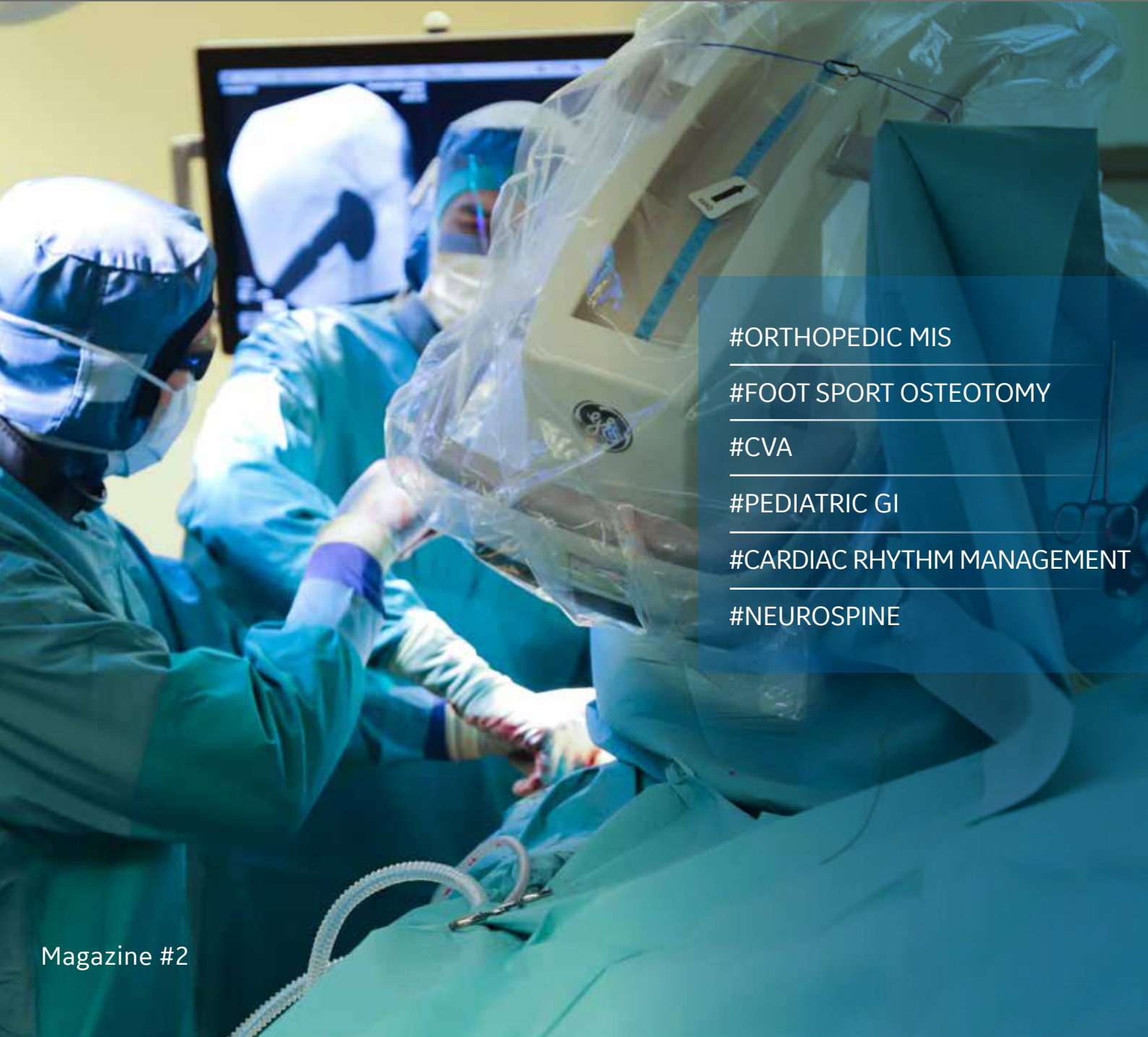



# OEC MAGAZINE

Innovation in Surgical Imaging with OEC C-arms



#ORTHOPEDIC MIS


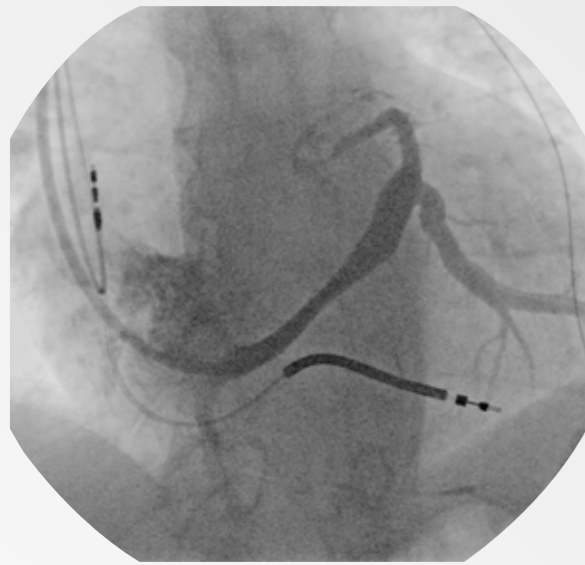
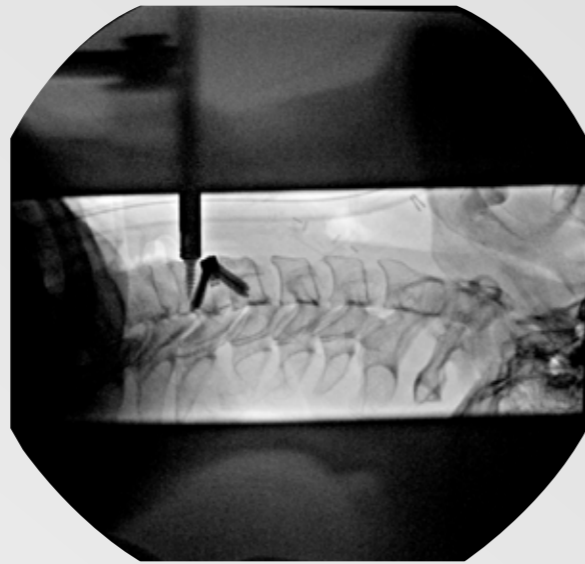
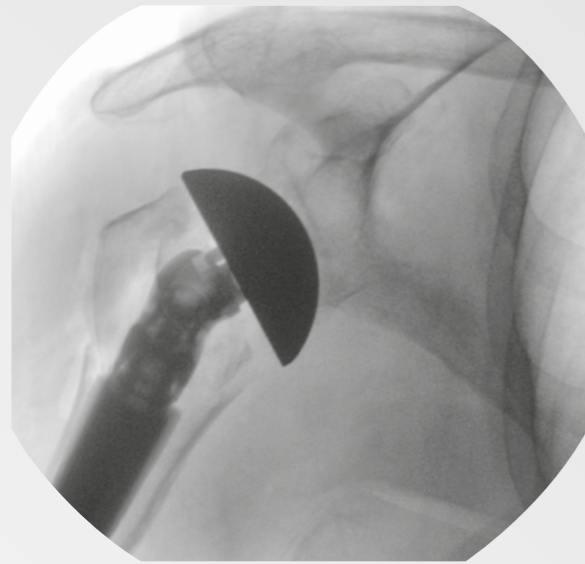
#FOOT SPORT OSTEOTOMY

#CVA

#PEDIATRIC GI

#CARDIAC RHYTHM MANAGEMENT

#NEUROSPINE



**Many thanks to our contributors:** Dr. Frederic Gomas, IGR, Villejuif, France | Dr. Bengt Karlsson, Skaraborgs Sjukhus Skövde Hospital, Sweden | Annelie Andersson, Skaraborgs Sjukhus Skövde Hospital, Sweden | Towe Järlfors, Skaraborgs Sjukhus Skövde Hospital, Sweden | Cecilia Dittmer, Skaraborgs Sjukhus Skövde Hospital, Sweden | Jörgen Hårdstedt, Skaraborgs Sjukhus Skövde Hospital, Sweden | Dr. Christophe Cermolacce, Clinique Blomet, France | Dr. Jean-Pierre Van Buyten, A.Z. Nikolaas, Belgium | Mrs Daeninck, A.Z. Nikolaas, Belgium | Mieke Devlieger, A.Z. Nikolaas, Belgium | Mrs de Bie, A.Z. Nikolaas, Belgium | Dr. Mike Thomson, Sheffield Children's Hospital, UK | Dr. Giovanni Alessi, AZ Sint-Lucas, Ghent, Belgium | Dr. Kristel Vanchaze, AZ Sint-Lucas, Ghent, Belgium | Dr. David Colle, AZ Sint-Lucas, Ghent, Belgium | Dr. David Mortsell, Skane University Hospital, Lund, Sweden | Mr Aronson, Skane University Hospital, Lund, Sweden | Helene Hansson Ferreira, Skane University Hospital, Lund, Sweden | Kerstin Sjögren, Skane University Hospital, Lund, Sweden | Maria Eltén, Skane University Hospital, Lund, Sweden | Dr. Stéphane Combes, Clinique Pasteur, Toulouse, France

Chief Editor: Coralie Nulac

**Editorial Team:** Mathilde Dauchez | Anne-Lise Brutus | Christoph Obermeier | Florian Guillemain | Laurent Murriss | An Massa | Susie Burrows | Edvin Kalmaru | Miki Perc | Anders Forsell | Knut Markeng | Marion Dequenne | Stephen Stoneman | Anette Storsjoe | Alice Berger | Tracy Deems | Jennifer Lange | Ellen van Oostenbrugge | Kenny Monsuru | Lifeng Wang | Rachel Schandel | Russell Dibb | Dave Barker | Helen Fowler

**Design:** Nathalie Ollivier | Mathilde Dauchez

**Local Contact Information:** GE Healthcare Buc | 283, rue de la Minière | 78533, Buc Cedex, France

For any feedback or question(s) you can contact: [coralie.nulac@ge.com](mailto:coralie.nulac@ge.com)

Dear reader,

As procedures become more complex, mobile C-arm technological developments are increasingly delivering better image quality, lower dose, better user workflow and ease of use.

Our GE Healthcare team is working hard to deliver innovative products, and to train and support personnel with the goal of easing the pressure in the operating room and reducing procedural complexity with better surgical imaging workflows for OR teams.

In this edition of the OEC Magazine, we highlight innovative practices and usages from customers using OEC Elite CFD, OEC One CFD and OEC Elite MiniView, all with CMOS flat panel detector. From cardiac rhythm management, to spine, gastro, orthopedic and other specialties, these articles highlight how surgeons and their teams utilize imaging today to drive better patient care.

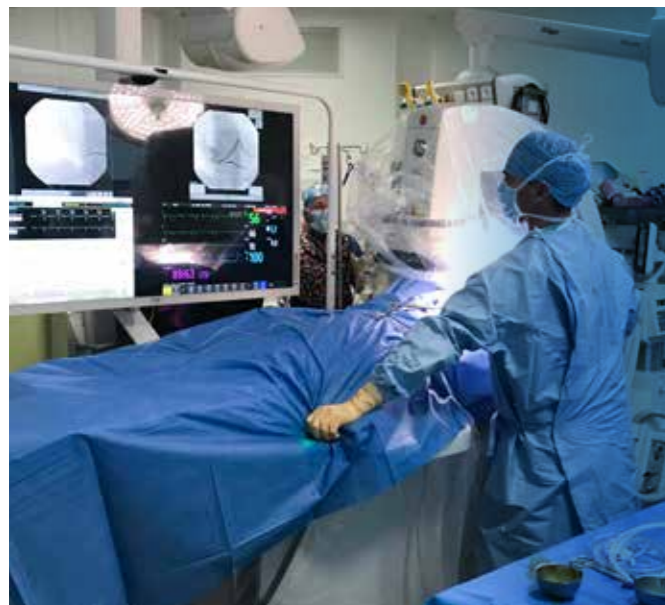We hope that these testimonials and articles on technology innovation and best practices will inspire you in your daily work in improving image guided therapy in various fields of application.

We would like to thank our clinical partners for sharing their best practices in this OEC Magazine and wish you a good reading!

With our best regards,

**Jean-François Drouet**  
Image Guided Therapy Director  
Europe  
GE Healthcare

**Christoph Obermeier**  
Surgery Marketing Manager  
Europe  
GE Healthcare



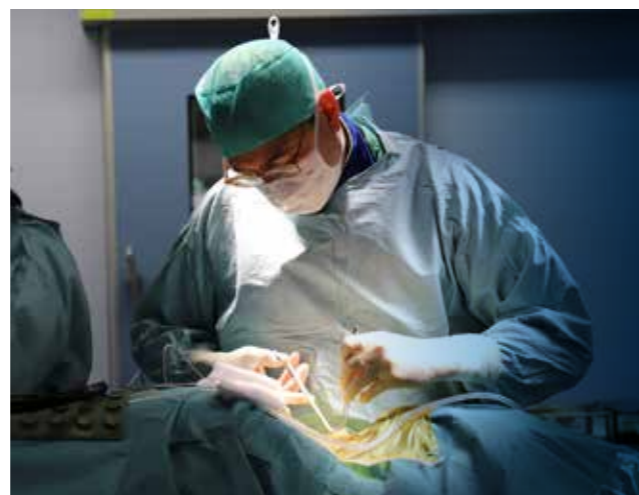06\_ Patient care pathway in an innovative CVA Unit | Ambulatory Express

16\_ Paediatric endoscopic dilatation of congenital intraluminal duodenal diverticulum or Congenital Duodenal Web (CDW) | Case report

20\_ Dose Management Tips & Tricks | Infographic

22\_ Orthopedic traumatology: a cross-disciplinary choice for a compact C-arm with CMOS flat detector

25\_ Shoulder fracture reduction by hemiarthroplasty | Case report



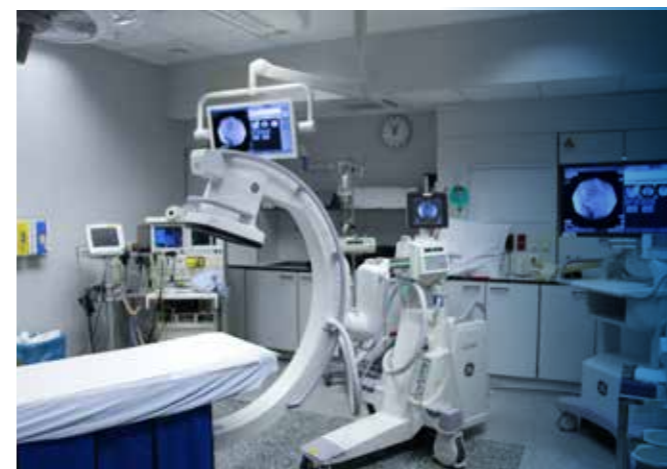30\_ Fluoroscopic imaging for foot and ankle surgery

35\_ Surgical excision of accessory navicular bone in a dancer's foot | Case report

36\_ Calcaneus osteotomy to correct congenital elongation and Haglund's deformity | Case report

38\_ Interventional Rhythmology with OEC Elite CFD

45\_ Optimizing patient care in an arrhythmia department



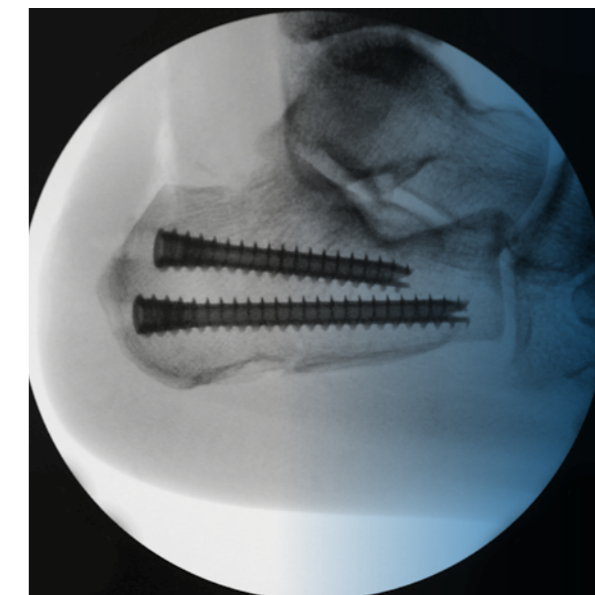
52\_ Complete Atrioventricular (AV) block treatment with Cardiac Resynchronization Therapy (CRT) device implant | Case report

54\_ Pacing treatment with leadless device implant | Case report

56\_ Spine procedures with OEC Elite CFD: efficient and reliable fluoroscopic imaging guidance

60\_ Anterior Cervical Discectomy and Fusion (ACDF) on C6-C7 | Case report

61\_ L5-S1 fusion by Retroperitoneal (Anterolateral) Approach | Case report



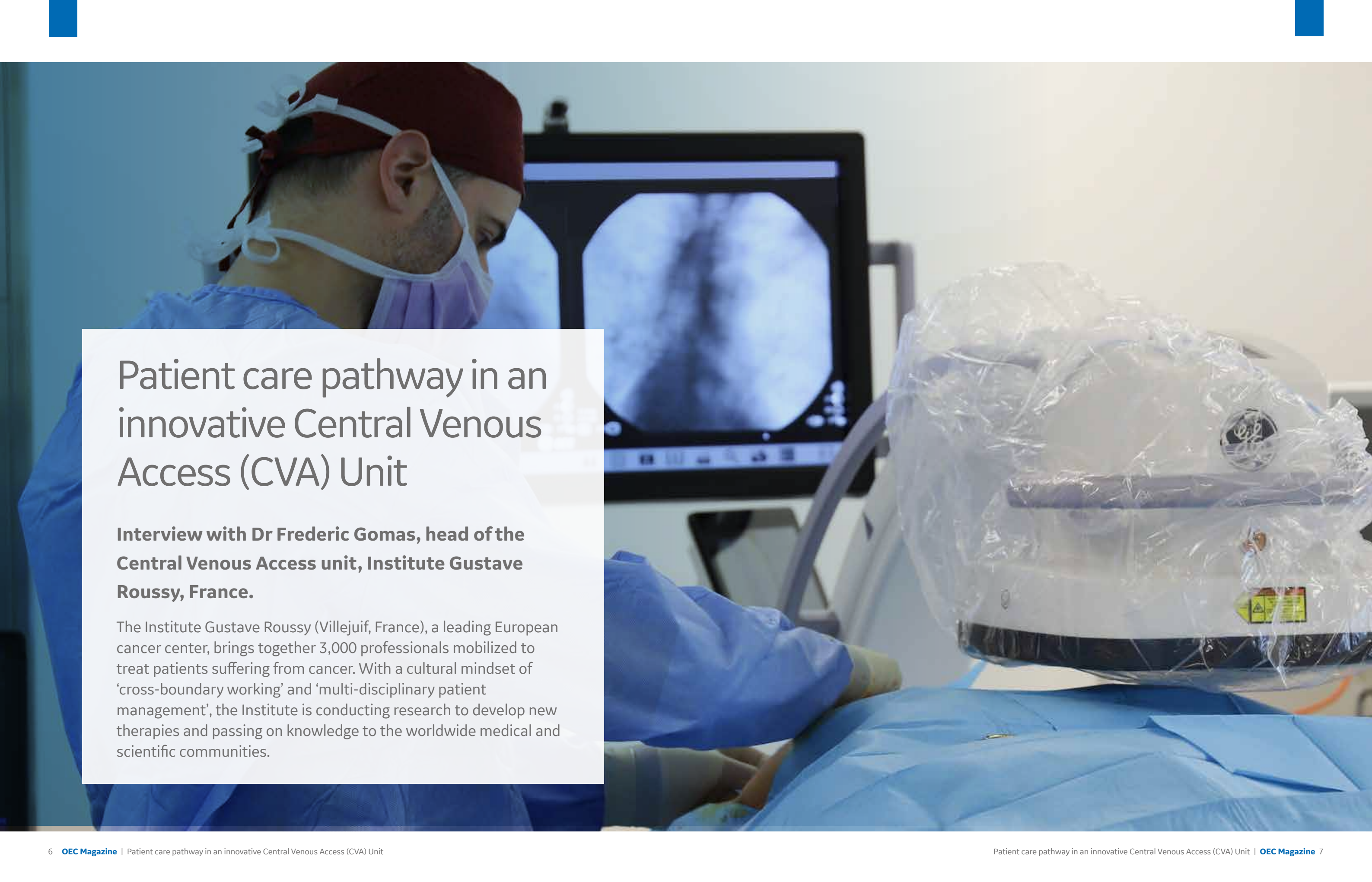
64\_ Anterior Cervical Discectomy and Fusion (ACDF) on C5-C6 and C6-C7 | Case report

66\_ Posterior percutaneous arthrodesis L5-S1 | Case report

70\_ How Live Zoom Imaging Feature Reduces Radiation Dose | Whitepaper

74\_ Interventional pain management technique with OEC Elite CFD

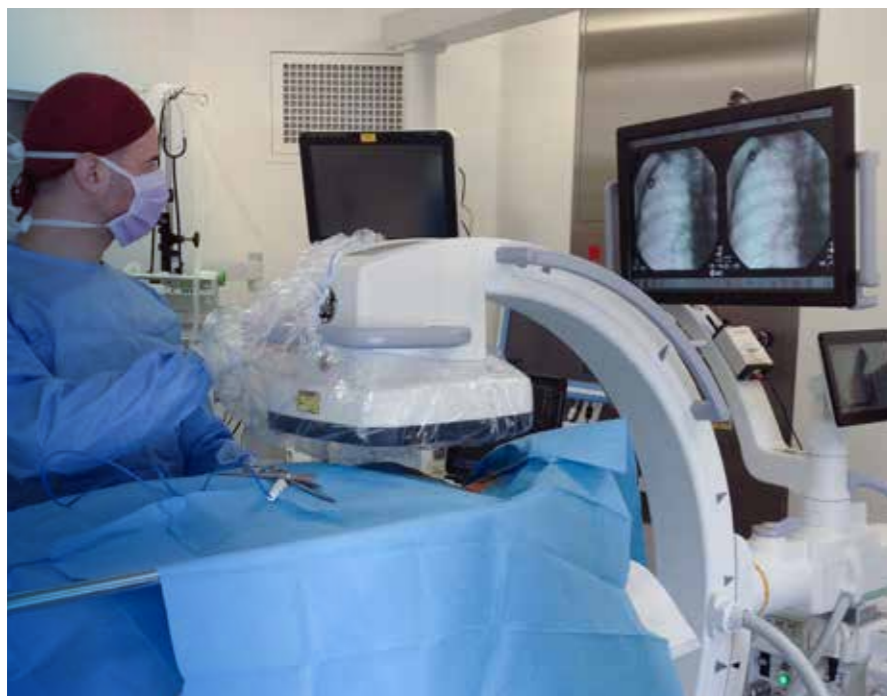82\_ GE Healthcare supporting Education and Continuing Professional Development (CPD) for radiographers



## Patient care pathway in an innovative Central Venous Access (CVA) Unit

**Interview with Dr Frederic Gomas, head of the Central Venous Access unit, Institute Gustave Roussy, France.**

The Institute Gustave Roussy (Villejuif, France), a leading European cancer center, brings together 3,000 professionals mobilized to treat patients suffering from cancer. With a cultural mindset of 'cross-boundary working' and 'multi-disciplinary patient management', the Institute is conducting research to develop new therapies and passing on knowledge to the worldwide medical and scientific communities.



**Within the Surgical and Interventional Pole, the unit of Venous Central Access (VCA) is a major contributor of the patient cancer care pathway. The unit has recently expanded its activity with a new operating room to meet the increasing demand for Central Venous Catheter (CVC) procedures. The Institute has selected OEC One CFD, an all-in-one C-arm with advanced imaging features.**

**Dr. Frederic Gomas explains the choice of the Institute and how the OEC One CFD C-arm answers the needs of the VCA unit activity.**

**Can you explain the activity of the CVA unit?**

*The Institute has been involved in the development of the percutaneous technique for the implantation of central venous access lines. My*

*predecessor and anesthesiologist Dr. Desruennes participated in building and introducing this technique in France. He also contributed to the creation of the CVA unit within the anesthesia ward. This organizational model ensures the centralization of information and knowledge to support the coordination of all the healthcare professionals in the patient cancer care pathway.*

*In the percutaneous approach, instead of just using anatomical landmarks, we identify the vein and perform the puncture under ultrasound control. We need fluoroscopic imaging to control the positioning of the extremity of the tunneled catheters, Peripherally Inserted Central Catheter (PICC) and Totally Implanted Venous Access Devices (TIVAD)<sup>1</sup>.*

*The mission of the CVA unit is to coordinate the activities of the 14 implant anesthesiologists of CVC*

*procedures. These specialized anesthesiologists manage preventive care activities to avoid potential complications as well as the follow up after implantation of the line. Working through the dedicated unit helps the coordination of the multifunctional team, giving them access to a point of reference for the patient before and after the line implantation.*

**How does OEC One CFD assist performance of the CVA unit?**

*Even though fluoroscopic imaging control is very short, it is mandatory for the implanter to ensure that the line is properly placed before discharging the patient.*

*In order to address the increasing volume of procedures, we put in place a process at each step of the patient pathway in our unit and inside the operating room. The staff supporting the organization of the CVA unit is composed of a nurse in the reception area, a care assistant, a bearer coordinating the arrival of hospitalized patients, a nurse inside the operating room, and an administrative assistant who receives the ambulatory patients. The architecture of the unit has been thoroughly vetted to optimize the patient workflow from the reception of the patient, during the procedure itself, and up to the discharge of the patient.*

*Inside the operating room during the procedure we are only assisted by one nurse. The room is quite small (about 29 m<sup>2</sup>) and busy, so it was mandatory to equip it with an all-in-one C-arm that would not congest the room.*

*We have set up the OEC One CFD C-arm with the parameters the team selected: automatic patient file filling (downloading the data from the*

*worklist), dose management during the procedure (working only in low dose and 8 pulses per second - pps) and archiving the patient images and dose report (sending them to the PACS and to our dose management software). The users of the C-arm are the anesthesiologists and the nurses of the CVA unit. As the user interface is intuitive and very easy to understand, the OEC One CFD C-arm facilitates the fluidity of our patient workflow.*

*The average time for a CVC procedure is about 20 to 30 minutes. The implantation itself takes about 10 minutes. The imaging procedure requires less than 10 seconds of X-ray activation time.*

*With our process and the OEC One CFD C-arm, we have been able to reach a maximum workflow of 16 CVC procedures a day in the new operating room.*

**Can you describe a typical CVC procedure?**

*The patient is placed in supine position. The procedure starts by the puncture of the jugular vein under ultrasound guidance. Then the graduated catheter is pushed to an estimated length (about 14 to 16 cm from the puncture). The fine tuning of the placement of the tip of the catheter at the junction of the Superior Vena Cava (SVC) with the Right Atrium (RA) is performed under fluoroscopy. In order to reduce radiation exposure to the patient and to the staff, we limit the fluoroscopic imaging to the control of the tip of the catheter in this junction. The last fluoroscopic image done is archived as proof of the success of the procedure outcome.*

*For the implantation of a TIVAD, there is an additional step connecting the catheter to the port (small chamber of injection). The port is placed underneath the skin. The final position of the tip of the catheter at the junction of the SVC with the RA is controlled with a fluoroscopic image after connecting the port.*

**How does OEC One CFD support your activity?**

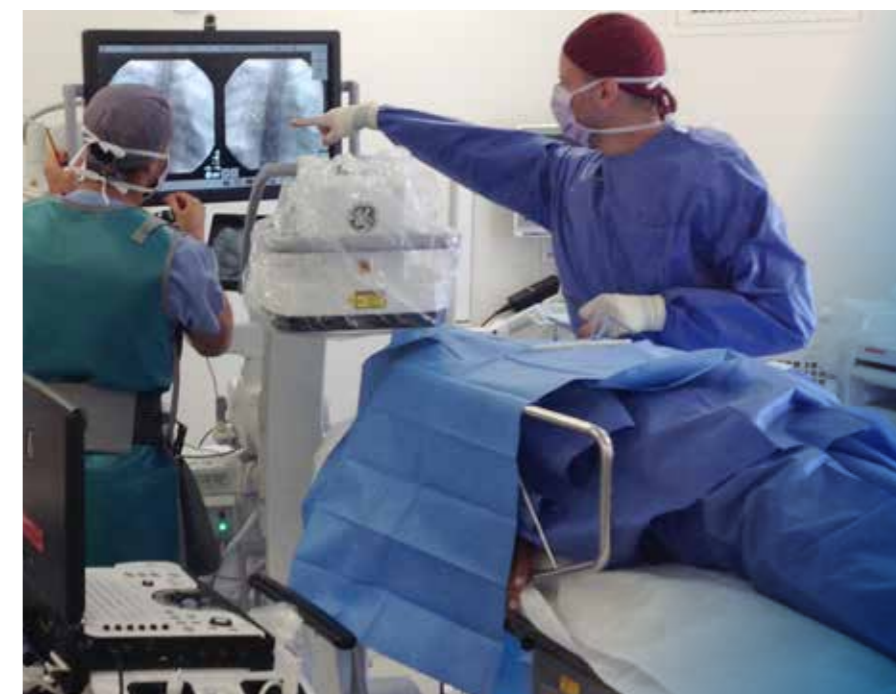*As I mentioned earlier, the OEC One CFD C-arm supports our workflow with its small size, its low dose imaging capacity and its ease of use that includes quite a lot of automation.*

**All-in-One**

*In our organization, the C-arm is dedicated to the CVA operating room and it is always placed at the head of the patient, along the patient axis. The room set-up is always the same even for a femoral access because we just need to check the junction point. We don't use fluoroscopy to guide the catheter to this junction. The depth of the C-arm is the right option for the CVC procedures: small footprint and large enough to reach the anatomy.*

*“The depth of the C-arm is the right compromise for the CVC procedures: small footprint and large enough to reach the anatomy.”*

**Dr. Gomas**



<sup>1</sup> Desruennes E, Gomas F [Central venous access for cancer chemotherapy]. Presse Med. 2018 Apr;47(4 Pt 1):320-330.

*“The image quality of the OEC One CFD C-arm in low dose mode and 8 pps is crisp enough to identify the anatomical landmark and the extremity of the catheter, even while the catheter tip moves quite a lot once it enters at the junction of the SVS and the right atrium.”*

**Dr. Gomas**

### High Image Quality allowing dose reduction

The big advantage of the OEC One CFD C-arm over our former C-arm is the CMOS detector that permits the optimization of radiation exposure, while maintaining the necessary image quality needed for the procedure. We are able to reduce the dose to the minimum and see the catheter tip moving in the vicinity of the carina. As our patients are exposed throughout their medical treatments (with CT scanners, Interventional radiology and radiotherapy exams) we consider that whenever we can reduce radiation exposure, it is better for the patient and has to be done.

For the CVC procedures or central lines implantation procedures (tunneled catheters, PICCs or TIVADs) we work with a fluoroscopy mode set to low dose and 8 pulses per second. It is the mode we choose that allows us to have

the required image quality to carry out the procedure. Indeed, during the procedure we want to see: the extremity of the catheter, the vertebral bodies, and the tracheal carina. The radiological landmark of the anatomy for the junction of the SVC and the RA is the zone located about 1.5 to 2 vertebral bodies below the carina. In very few cases of patients with a thoracic pathology, the carina might be difficult to see under X-ray, so we use the ElectroCardioGram (ECG) to help localize this position. We never change the dose set-up. The image quality of the OEC One CFD C-arm in low dose mode and 8 pps is crisp enough to identify the anatomical landmark and the extremity of the catheter, even while the catheter tip moves quite a lot once it enters at the junction of the SVS and the right atrium.

### Ease of Use

In order to comfortably do 16 procedures per day, the C-arm must not be complicated to use. The implantation time is critical. We are trained to perform the implantation in 10 to 12 minutes (between incision and dressing).

The technique of line implantation is called the Seldinger modified technique. Once the incision area is sterilized, the anesthesiologist proceeds to the anesthesia of the deep tissues. He localizes the vein under ultrasound and proceeds to puncture it with a needle mounted over a syringe. He introduces a guidewire through the needle and removes it after confirming that the guidewire is inside the vein. He slides the introducer over the guidewire, then he slides the catheter through the introducer, and lastly he pushes it to its final position. The implant anesthesiologist performs a fluoroscopic control image of the tip of the catheter at the junction of the SVC

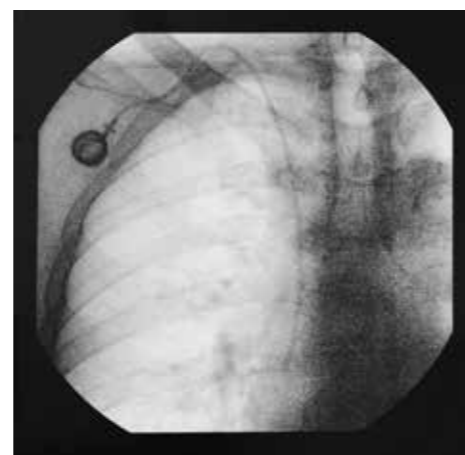
with the RA. Once confirmed he ends the procedure with the dressing of the wound.

For the fluoroscopic control, the anesthesiologist pulls the OEC One CFD C-arm over the patient's chest and takes several X-rays. Images are automatically saved on the hard drive. The adjustments of the fluoroscopy techniques are automatic as well as adjustment of brightness and contrast of the image. No additional manual adjustments are necessary.

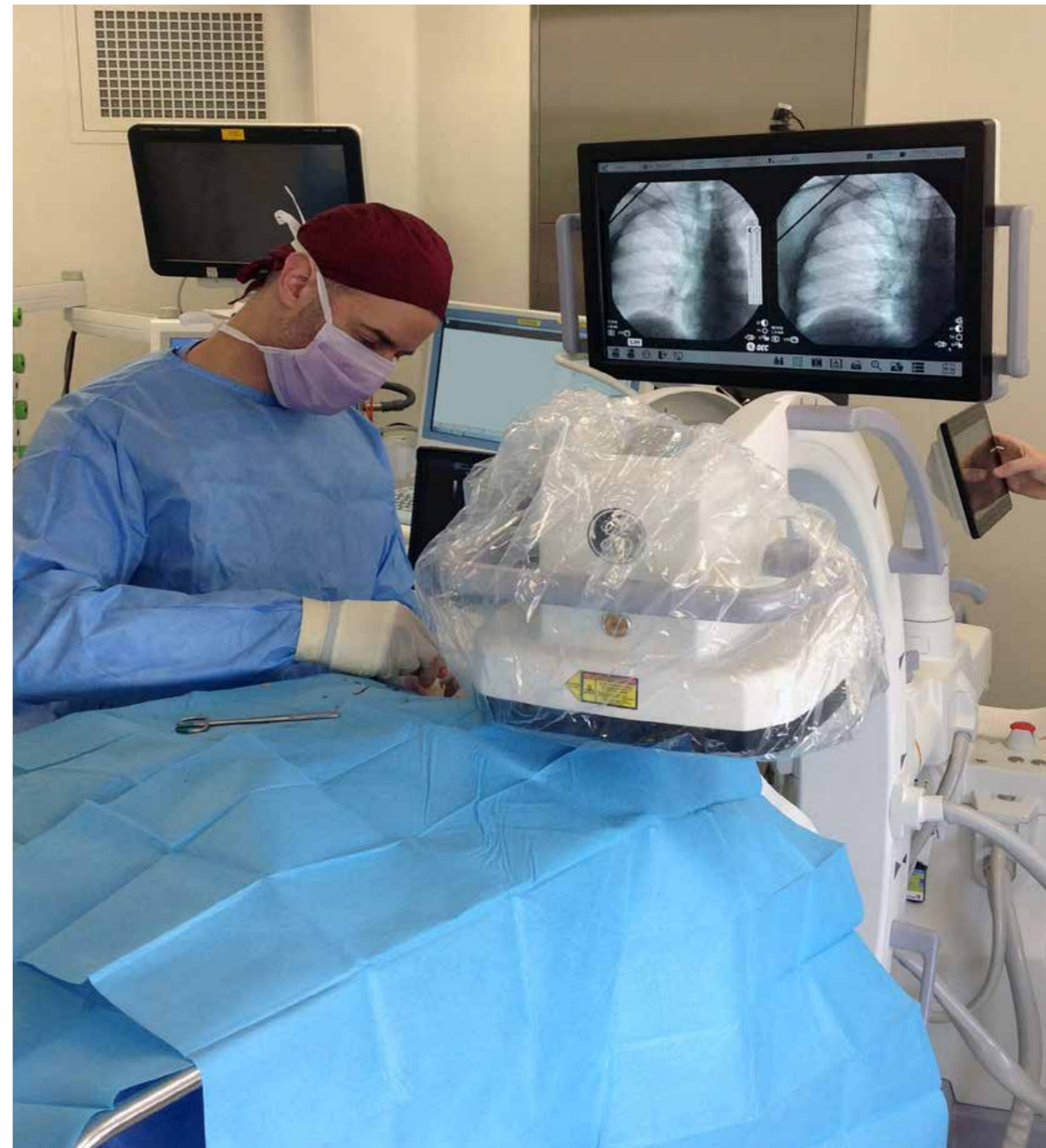The nurse and the anesthesiologist clean the C-arm after each patient. As the C-arm is connected to the PACS, they send the patient data to the archives and retrieve the information file for the next patient.

**In 2019, our unit performed the implantation of 2,939 CVC; 2,023 TIVAD; 781 tunneled catheters; 82 PICC and 53 cytapherese catheters. Among these procedures, about 300 to 400 are pediatric cases managed by 9 specialized anesthesiologists.**

**In our modern unit, considering the small operating room and the important volume of procedures, the OEC One CFD C-arm has brought us the comfort and the performance to maintain our optimized workflow. □**



Final fluoroscopic control of TIVAD implant with OEC One CFD.



# “Ambulatory express”

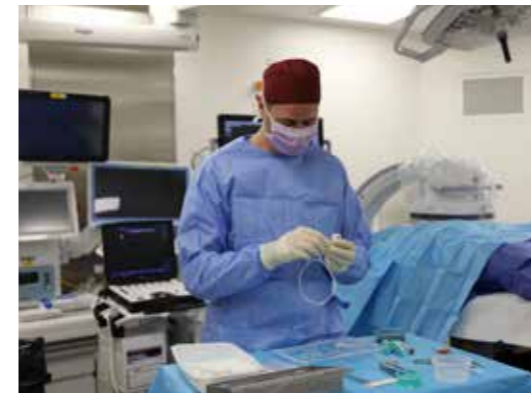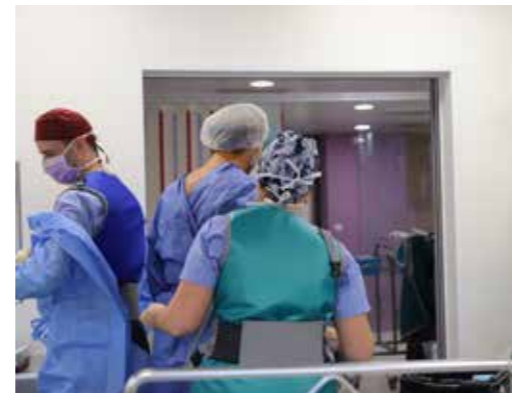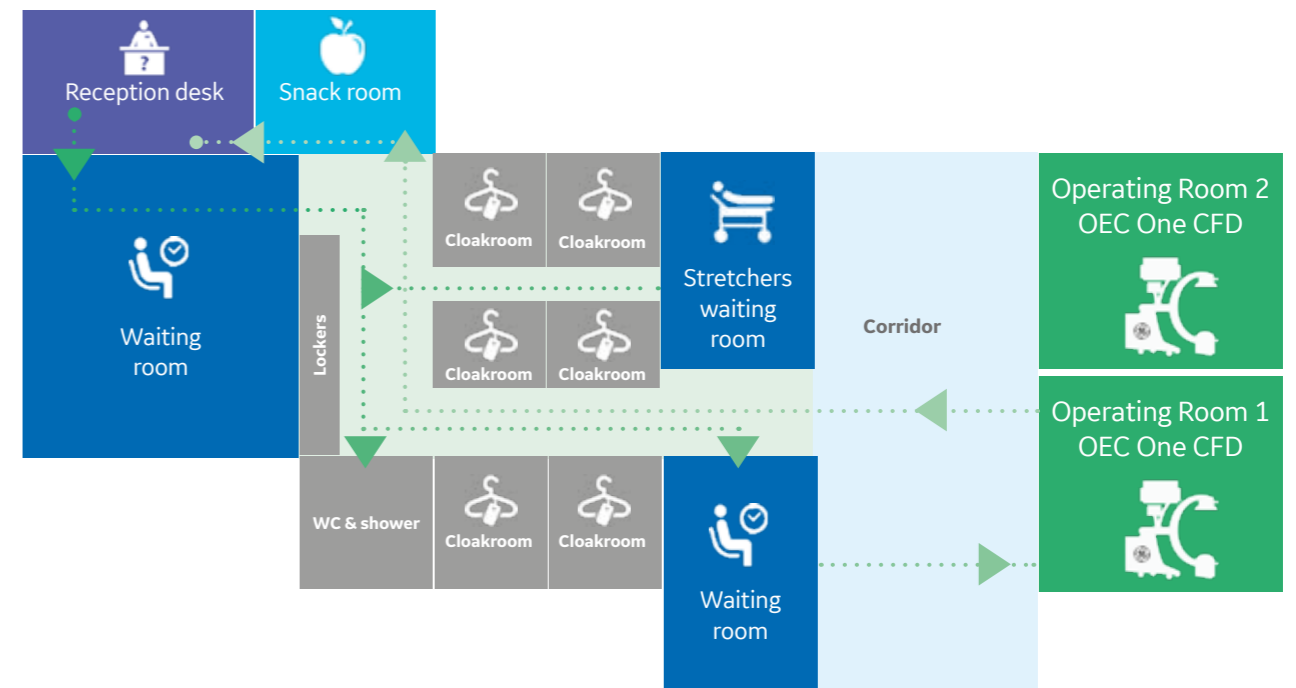
*“Since the creation of the CVA unit within the anesthesiology ward we have striven to develop all the logistics and organization around the procedure: from the architecture, staff, and equipment perspectives.”*

**Dr. Gomas**

From inception, the patient pathway, called “ambulatory express”, starts with the patient arriving directly in the center of the operating ward. Admissions, examinations and interviews are done by the reception nurse, who answers any potential questions the patient might have. The care assistant helps the patient change into a sterile smock needed in

the operating room. When the patient is ready, the care assistant takes him to the waiting room located just in front of the operating room. Once the patient enters the operating room, the nurse and the doctor position him over the examination table. They then start the checklist and proceed to prepare for the puncture. Preparation takes as much time as the procedure itself

(about 10 min). Once the procedure is finished, the care assistant takes the patient to the snack room, where he stays for about 10 to 15 minutes. Then the dressing is checked, instructions and prescriptions for discharge are given, and finally the patient can go home.



**ADMISSION** -----> 20 minutes

**PROCEDURE** -----> 10-20 minutes

**DISCHARGE** -----> 20 minutes

- Patient arrives at reception desk directly at the OR floor level
- The reception nurse performs admission interview

- Patient takes a shower if not done at home
- Patient changes in cloakroom and leaves personal belongings in lockers

- Patient waits to be lead to the Operating room
- Patient enters in the OR walking while the OR is preparing for the procedure

- Once surgery ends, patient leaves the OR walking back to the cloakroom

- Patient gets dressed and takes a snack
- The reception nurse gives the prescriptions and confirms the appointments for the first chemotherapy therapy treatment



training content is customized depending on the objectives of the practitioners: to start or to improve the activity.

I like the surgical gesture of catheter implantation. For some patients, the placement can be more complicated and more technical. The true reason I love this job is that usually as an anesthesiologist we have very few links with the other healthcare providers of the hospital. Working as an implanter anesthesiologist in the CVA unit, I have many interactions with doctors and nurses from the oncology, chemotherapy, radiotherapy, and surgery wards. Through this collaboration I get a more comprehensive overview of the management of patient care, understanding what the good indications are, and when to derogate from these indications depending on the potential complications. I can better measure the impact of my intervention, which takes only 10 minutes. It seems trivial if we consider the full treatment for cancer the patient will go through. However, the catheter must stay in place for several months and the patient will have to deal with it. I have to balance the choice of the technique with the needs of the patient comfort, and the needs of the users of the venous access line. It is a multi-lateral decision for the best solution.

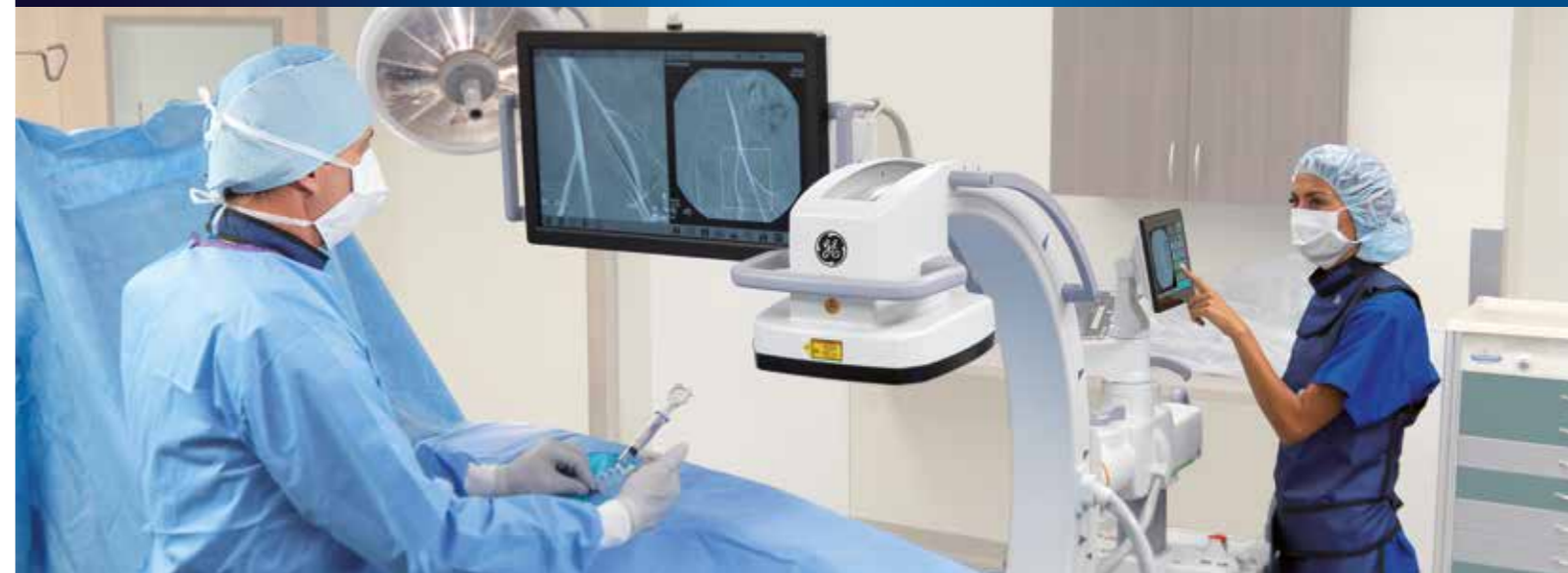In the evaluation of the solution we consider the psychological factor. From the patient perspective, the implantation of a CVC means the onset of the disease. From the moment he enters the operating room, the patient understands that they have cancer and that he will go through chemotherapy. As patients are totally awake and aware, they often ask lots of questions. We make sure we always answer so they feel as comfortable as possible during the procedure. Before starting the incision, I ask the patient for their favorite music, which the nurse always finds in our huge playlist – and we play it during the procedure.

I am an intensive care anesthesiologist with experience in pediatric care. I specialized in CVC implantation at the Institute Gustave Roussy during my internship. I became the head of the CVA unit 5 years ago.

The high volume of procedures at Gustave Roussy Institute provides us quite a lot of experience. We expand our experience and share our practices through training other practitioners from less experienced centers from France and other countries (mainly North Africa and Eastern Europe). The training includes a theoretical part to reinforce technical aspects of the procedures as well as the observation of several cases in the operating room. We also share our experience of clinical indications, the management of potential complications and also the organization of the unit. The

The statements by GE's customers described here are based on their own opinions and on results that were achieved in the customer's unique setting. Since there is no "typical" hospital and many variables exist, i.e. hospital size, case mix, etc., there can be no guarantee that other customers will achieve the same results.

## DISCOVER A WHOLE NEW WORLD IN SURGICAL C-ARMS: A COMPACT PREMIUM SYSTEM



### 3 REASONS WHY YOU ARE GOING TO ENJOY WORKING WITH THE OEC ONE CFD



#### COMPACT

**All-in-one C-arm system**  
Operating rooms are usually small and busy, the **OEC One CFD** has a small foot print (<1,40m<sup>2</sup>) to address your space constraint.

**Fluidity, maneuverability, transportability**  
The theatre space is a dynamic environment. Easy positioning, screen motions and C-Arm movement of 55° Overscan / 95° Underscan, all make for the **OEC One CFD** to be moved smoothly. Once the procedure is finished, the unit can be unplugged and moved to another theatre without the need to boot down – thanks to 5-minute standby power.



#### PREMIUM

**Stunning Image Quality (IQ)**  
IQ is one of the most important criteria when using a surgical C-arm. The **OEC One CFD** brings three exceptional aspects: CMOS flat panel detector (CFD) + 4K 27" UHD Monitor Display (30 cm squircle images) + Advanced image chain software enabling 1:1 image detail.

**Advanced features such as Live Zoom and much more...**  
You dream about having all the advantages of a compact system and the key premium C-arm advanced features? With the **OEC One CFD** it's now real. With Live Zoom you can view up to 4X image size, without increasing dose. And in peripheral vascular procedures, visualize 0.014" guidewires thanks to 1.5k x 1.5k image processing.



#### INTUITIVE

**Modern OEC Touch**  
Training? No worries. **OEC One CFD** makes your surgical experience easy. User navigation is intuitive and facilitated by well known smartphone and tablet gestures: 2 finger zoom, 1 finger to rotate image, slide or swipe across the icon menu.

**Plug & Play system**  
When you switch on your **OEC One CFD** thanks to the automatic settings you're immediately ready for fluoroscopy. The system smartly adjusts to patient anatomy thanks to advanced imaging algorithms. Simplified & synchronized workflow between the monitor screen and the OEC Touch control panel are designed to help you better collaborate with your team and optimize surgical time & dose management.

[www.gehealthcare.com/surgical\\_imaging](http://www.gehealthcare.com/surgical_imaging)

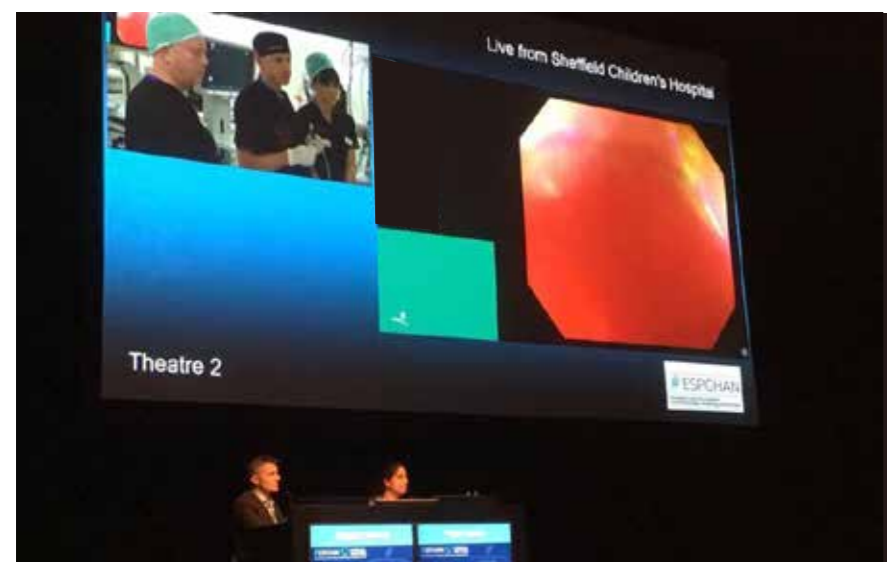Availability of select models, configurations, and options varies by country. Please contact your local sales representative.  
© 2019 General Electric Company. GE and the GE Monogram are trademarks of General Electric Company.

#ChooseTheOne



# Paediatric endoscopic dilatation of congenital intraluminal duodenal diverticulum or Congenital Duodenal Web (CDW)

Courtesy of Pr Mike Thomson, Sheffield Children's Hospital, UK



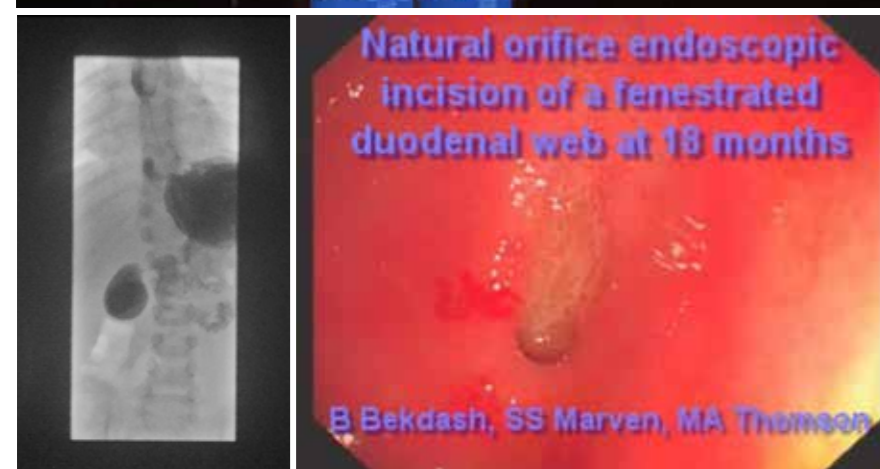During its 2019 annual meeting, the European Society for Paediatric Gastroenterology, Hepatology And Nutrition (ESPGHAN) organised for the first time, live endoscopy classes to promote and support specialists training on paediatric endoscopic techniques. Pr Mike Thomson, Paediatric Gastroenterologist and Interventional Endoscopist, showcased a live endoscopic dilatation of CDW, from a theatre in the International Academy for paediatric endoscopy training, Sheffield Children's Hospital.

## Patient History

A 4-year-old male patient, with a history of chronic Gastroesophageal Reflux Disease (GERD) was admitted for gastroenterology assessment. At the age of 10 months old, the patient had been treated for tracheal-oesophageal fistula (TOF) through a fundoplication procedure, done under endoscopy, but limited at time of surgery to the oesophagus and stomach. CDW was also diagnosed at age 18 months and the patient was put under surveillance (see Fig. 2).

Despite maximum medical therapy, cow's milk exclusion and a repeat fundoplication, the patient continued to vomit forcefully and had significant weight loss, weighing only 15 kg on consultation.

Barium meal (Upper Gastro Intestinal



**Fig. 1** Radiographic barium meal showing intact fundoplication and CDW

**Fig. 2** Endoscopic image of CDW of patient at age 18 months

contrast study) images revealed an intact fundoplication (see Fig. 1). Further upper gastrointestinal (UGI) endoscopy identified CDW as the most probable root cause of the vomiting.

It was decided to perform endoscopic balloon dilatation of the web to restore digestive pathway.

## Clinical Challenge

Although, endoscopic balloon dilatation of the web in paediatric cases is only documented for a few patients worldwide, the Paediatric Gastroenterologist team of Sheffield Children's Hospital is trained on this technique of surgery and has performed several cases. Due to its minimally invasive technique, it was then determined to be the preferred treatment for the patient. Balloon dilatation produces tearing of the mucosa of the obstruction. Recovery time of this 'incision less' procedure is reduced, allowing the patient to come back to natural food ingestion much faster.

The surgical oesophago-gastroduodenoscopy (OGD) technique for paediatric patients is taking into account the small anatomical dimension and sharp anatomical angulations of children. For example, the oesophagus of a newborn is about 10 cm in length and about 0.5 cm in diameter. It requires small duodenoscopes and tools. The fluoroscopic imaging challenge of the procedure is to provide contrast and image resolution at the lowest radiation dose possible, and lowest iodine concentration possible.

## Solution

Fluoroscopic imaging guidance was performed with the OEC One C-arm set to continuous standard fluoroscopy and paediatric configuration (addition of a 3.5 mm equivalent aluminium filter and removal of the anti-scatter grid). The additional filtration permits to harden the X-ray beam, and the removal of attenuating anti-scatter grid allows the C-arm to set up a lower technique (kV, mA), maintaining image quality while

managing radiation dose for paediatric anatomy.

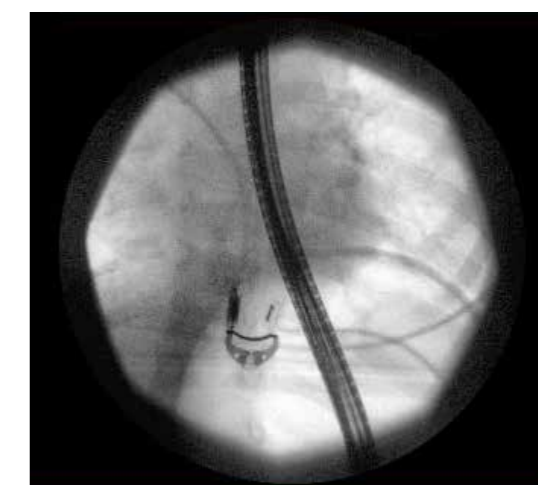
The laser aimers were turned on during the procedure to aid proper centering, avoiding extra positioning shots. Following ALARA best practices, the radiographer kept the image intensifier as close to the patient as possible. It was possible to complete the full procedure avoiding the use of the magnification mode which has a higher dose rate. The Cine run of final control of des-obstruction pathway was selectively recorded post acquisition using the Cine Save function instead of re-acquiring the sequence (which requires additional dose and contrast media). All of these imaging

techniques were carefully applied to manage the radiation exposure throughout the procedure.

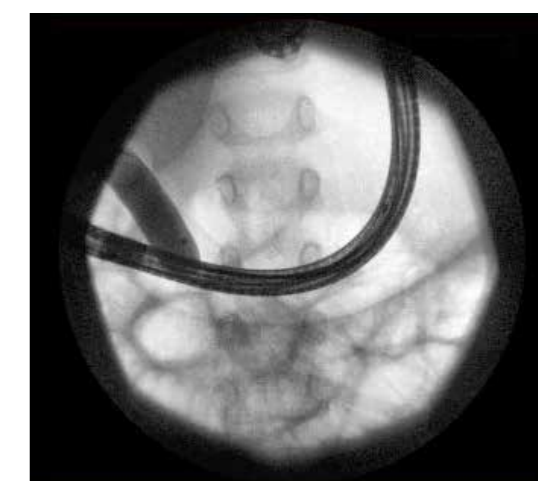
## Procedure

The procedure was performed under local anaesthesia.

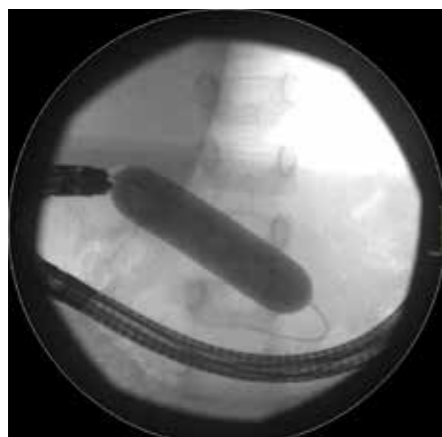Cannulation of the stenosis was done under endoscopic guidance. The balloon was introduced in the natural orifice to accomplish the dilatation under fluoroscopic imaging guidance as illustrated by Fig. 3, 4 and 5.



**Fig. 3** Fluoroscopic image showing correct insertion of duodenoscope in the patient's stomach



**Fig. 4** Fluoroscopic image showing balloon dilatation at stenosis level



**Fig. 5** Fluoroscopic image of balloon dilatation showing no "waist" or residual stenosis

Final fluoroscopic image of balloon dilatation showed no 'pinch' or 'waist' in the balloon resulting from resistance during inflation, indicating proper tearing of mucosa at stenosis level. Final control of pathway restoration after balloon dilatation was done under fluoroscopic imaging, using Iodine contrast media diluted at 50% (see Fig. 6).

## Conclusion

The procedure allowed enlargement of the original orifice from 1mm to a of 10 mm in diameter.

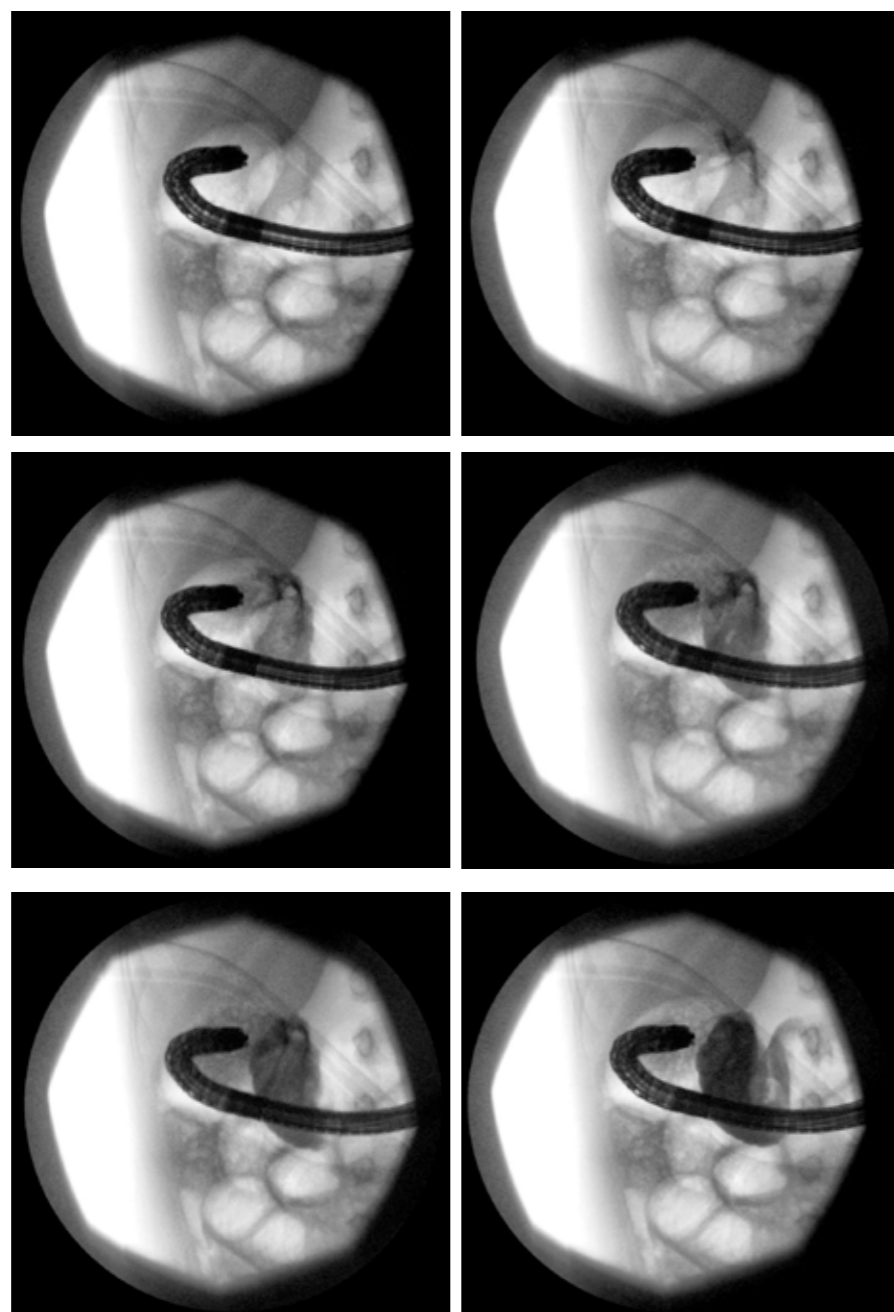
Total procedure time was 20 mn.  
Total fluoroscopy time was 10 mn and cumulated DAP was 83 mGy.cm<sup>2</sup>.  
The objectives of reducing procedure duration and re-establishing gastric pathway were reached.

The patient came back to normal nutrition without vomiting the day following the procedure.

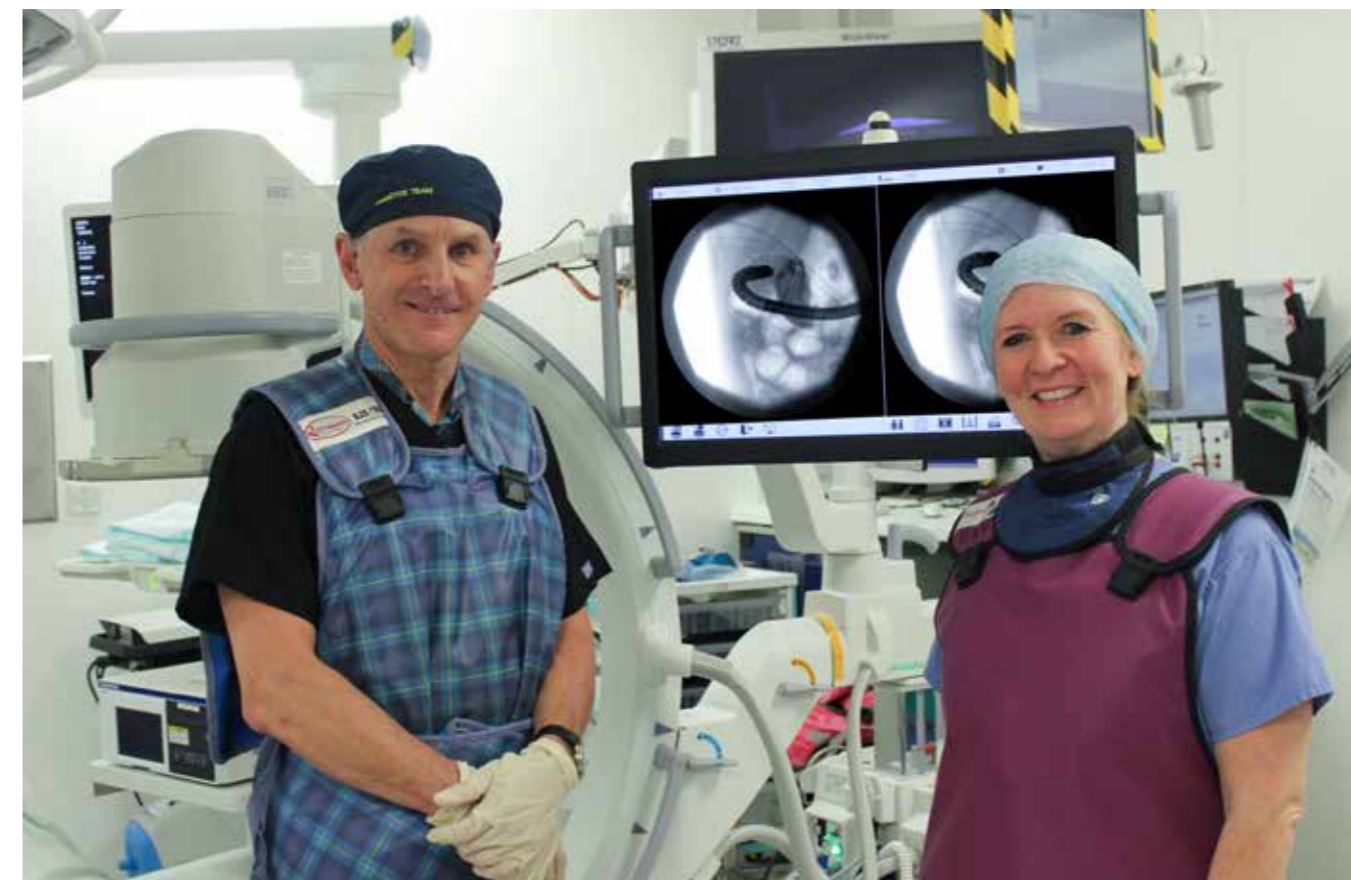*"I really liked the large monitor that I can move easily closer to my sight, it saves me craning my neck to see the image"*

**Pr Thomson**

*"The Cine Save function is brilliant and very useful. It saves dose by avoiding the need to rerun the fluoroscopy sequence,, and it is easy to use"* **Chris Heafer**



**Fig. 6** Cine run series of images confirming des-obstruction and re-establishment of gastric pathway



**Pr. Mike Thomson** is a consultant Pediatric Gastroenterologist and Interventional Endoscopist – Honorary Reader in Pediatric Gastroenterology.

*I trained in medicine in Aberdeen (Scotland), then I moved back to UK in Yorkshire to specialize in Pediatrics. I moved to Brisbane (Australia) to train more specifically in Paediatric gastroenterology at the Centre of Paediatric Gastroenterology, and completed my research for medical doctorate focusing on Nutrition and Energy expenditure in Cystic Fibrosis. I also trained in endoscopy, pediatric hepatology and pediatric nutrition. I was involved in their Pediatric Liver Transplant Program which is one of the finest in the world.*

*I returned to the UK to work for 2 years at the Birmingham Children's Liver Transplant Unit. After that, I accepted a position at the Royal Free Paediatric Gastroenterology Unit set up by Professor John Walker-Smith, one of the fathers of Paediatric Gastroenterology, for about 10 years.*

*For the last 15 years, I have been a Consultant Paediatric Gastroenterologist and Interventional Endoscopist at the Centre for Paediatric Gastroenterology of Sheffield Children's Hospital NHS Foundation Trust. I am also an Honorary Reader in Paediatric Gastroenterology Sheffield University Medical School.*

The statements by GE's customers described here are based on their own opinions and on results that were achieved in the customer's unique setting. Since there is no "typical" hospital and many variables exist, i.e. hospital size, case mix, etc., there can be no guarantee that other customers will achieve the same results.

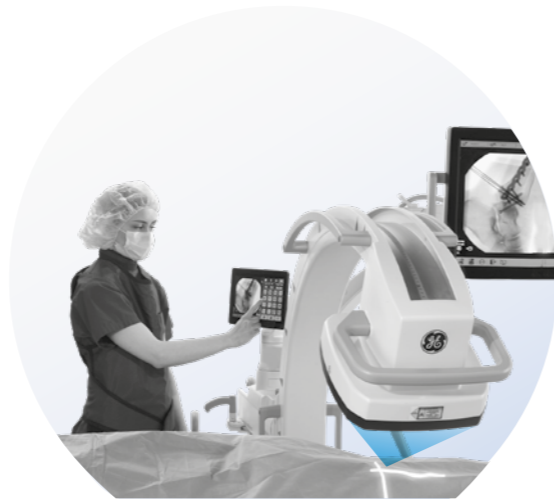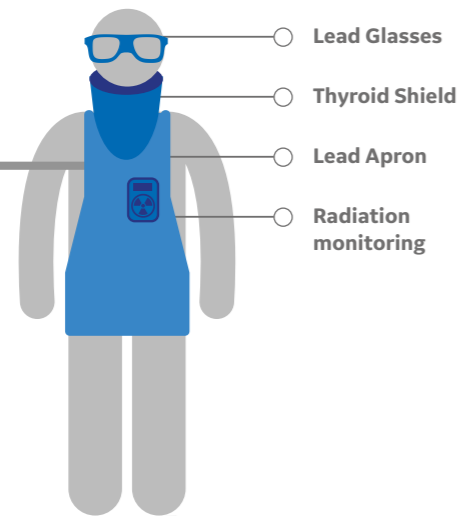
# DOSE MANAGEMENT TIPS & TRICKS



GE Healthcare designs OEC C-arms to provide optimum image quality at the lowest achievable dose. Fluoroscopic imaging is used routinely and increasingly for percutaneous and minimally invasive surgical procedures. Delivering the proper amount of radiation is critical to producing superb image quality. These best practices are to help manage the radiation dose for patients and surgical teams.

## Wear protective gear and monitor exposure

Proper radiation protection can reduce surgeon and staff exposure to scatter radiation.

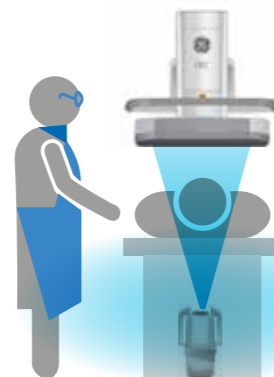

## Anticipate C-arm positioning

Angulate C-arm and use the laser aimer before acquiring images to reduce the number of images and amount of fluoroscopy.

## Position image detector

Placing the image detector as close as possible to the patient allows the user to manage dose exposure to the patient and to reduce the geometrical zoom effect due to the distance from the source. By doing so, scatter radiation is reduced and this can improve image quality.

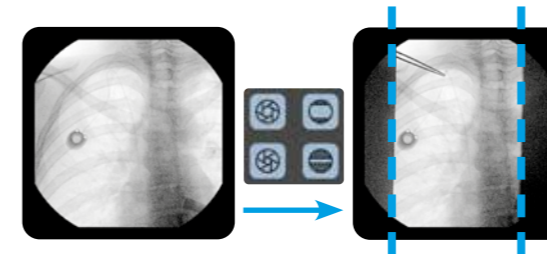


## Keep X-ray tube under the table

In this position, scatter radiation is largely directed towards the floor, reducing exposure to the operator's chest, neck and head.

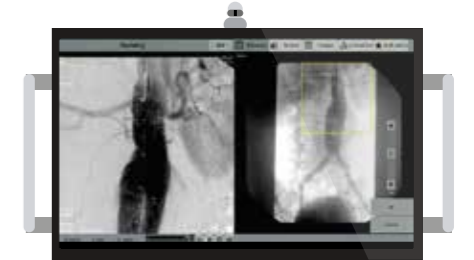## Use Collimation preview

Collimation may improve image quality and contrast. Use preview collimation to avoid a fluoroscopy exposure to check collimation.




## Live Zoom

Live Zoom enables surgeon to focus on critical details without increasing the X-ray dose<sup>1</sup>.

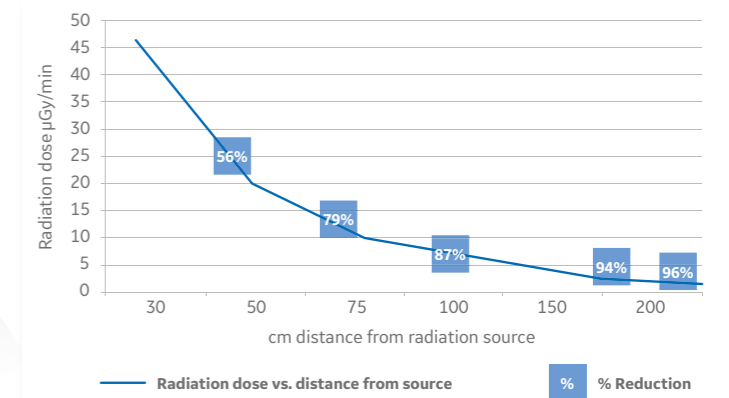


## Step Back

Operators should remain as far away from the X-Ray source as practical during fluoroscopic procedures.



Radiation dose vs. distance from source (table side)



## Fluoroscopy modes

OEC Elite and OEC One are designed with continuous, pulsed and low dose modes to allow maximum clinical utility with effective dose management. Each of these modes employs different characteristics in image quality, dose, and real-time temporal response.

### Continuous Fluoroscopy

In continuous fluoroscopy, the generator provides a steady tube low mA while the fluoroscope is activated for continuous real-time viewing.



### Low Dose mode

Low dose is used to decrease the amount of radiation received by the patient and operator for procedures that do not require a high quality image. In the standard and pulsed fluoro modes, using low dose will reduce the dose rate by approximately

**50%**<sup>2</sup>

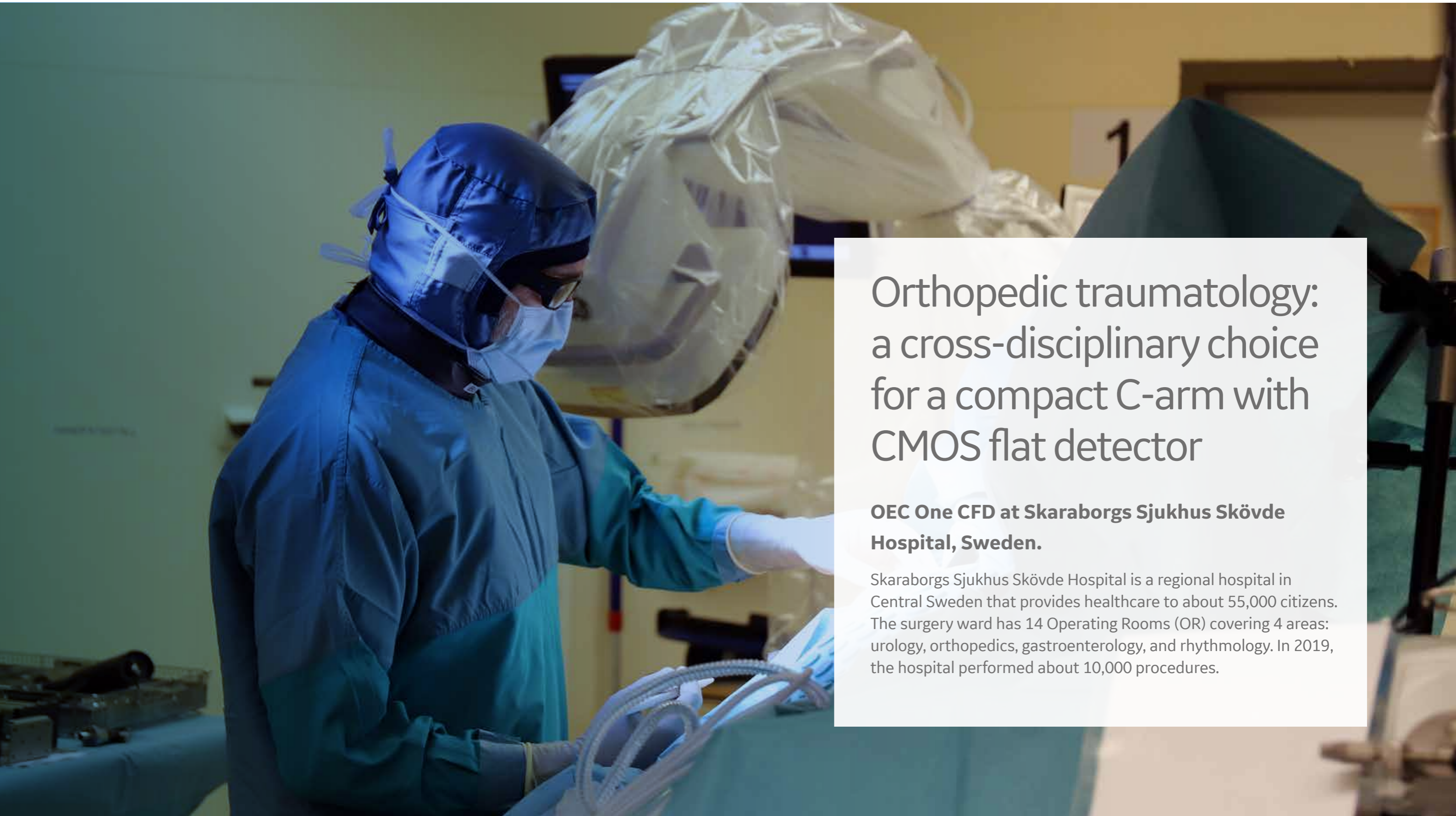

### Pulsed mode

Use of a pulsed fluoro mode may significantly reduce the dose rate; however, image quality may be degraded.



1. Live Zoom is available on OEC Elite CFD, OEC Elite, and OEC One CFD models. This option is not available on OEC Elite MiniView and OEC Brivo.  
 2. In the standard and pulsed fluoro modes, using low dose will reduce the dose mode rate by 50% or more compared to standard dose levels, as defined by IEC 60601-2-43:2010 cl. 203.6.101. Other modes, such as HLF, will experience lower dose levels if low dose is activated, but the reduction amount may vary.



## Orthopedic traumatology: a cross-disciplinary choice for a compact C-arm with CMOS flat detector

**OEC One CFD at Skaraborgs Sjukhus Skövde  
Hospital, Sweden.**

Skaraborgs Sjukhus Skövde Hospital is a regional hospital in Central Sweden that provides healthcare to about 55,000 citizens. The surgery ward has 14 Operating Rooms (OR) covering 4 areas: urology, orthopedics, gastroenterology, and rhythmology. In 2019, the hospital performed about 10,000 procedures.



Dr. Bengt Karlsson (Orthopedic Surgeon), Annelie Andersson (Operating Nurse), Towe Järlfors (Assistant Nurse), Cecilia Dittmer (Anesthesia Nurse), Jörgen Härdstedt (Chief Nurse)

**To address the increasing demand for orthopedic surgery, a multifunctional team composed of the chief nurse, the nurses, the biomedical engineer, and the surgeons was formed to select the most suitable C-arm for their procedures. After a selection process, the hospital chose the OEC One CFD C-arm. The team explains how the C-arm has supported the orthopedic surgery activity since its installation.**

**Dr. Bengt Karlsson explains his surgical activity with the OEC One CFD:** "My specialty is traumatology. I treat all types of fractures, with the exception of pelvis and spine injuries, and in all my procedures, I use fluoroscopy. I perform about 5 to 6 operations per week, and for half of them I use the OEC One CFD C-arm. I have been using it for about

one month long for upper extremities, a couple of pediatric cases, and for hand surgery.

OEC One CFD has several functionalities that I appreciate and use. In shoulder surgery, I can rotate the C-arm to get an overscan of more than 45°, up to 55°, to take an AP view. The image quality is very good, and I can see the tubercle lines of the humerus and check that the prosthesis is well centered. If the tubercles don't move when I rotate the shoulder, it confirms they are firmly attached. I have a clear view of the cortical structures of the bones, which is essential for fracture reduction in trauma surgery. OEC One CFD functions very well when I use it for supracondylar fracture reduction in children. The image quality is excellent.

This compact C-arm was also selected for its small footprint to work in our small OR. The big monitor attached to the C-arm is very important to me. It saves space and I can raise it to eye

level and pull it close so I can work in a comfortable position. The wireless footswitch, that does not interfere with the equipment of the room when we need to move around, is also an additional comfort. The laser aimer is also important to get the C-arm in the right position without taking additional fluoroscopic images. A 21-cm CMOS detector is big enough for upper extremity surgery, as a larger detector would clutter the sterile working space.

We have also had good experience with the Live Zoom feature, which allows the display of small details in zoomed mode without additional dose.

OEC One CFD is a very good C-arm for my traumatology activity. It is compact, easy to use and provides a very detailed image of the anatomy I need to see for my procedures."

# Shoulder fracture reduction by hemiarthroplasty

Courtesy of Dr. Bengt Karlsson, Orthopedic Surgeon, Skaraborgs Sjukhus Skövde Hospital, Sweden.

## Clinical Challenge

A 72-year-old female patient was admitted for right proximal humeral fracture reduction by hemiarthroplasty with SMR® prosthesis (Lima Corporate).

## Procedure

Before starting the procedure, the team displayed the pre-operative 3D CT image of the fractured shoulder (see Figure 1) on the large monitor of the operating room. They then moved the patient on the operating table in reclined chair position. The patient's right shoulder was cleared from contact with the operating table. This gave the surgeon complete access to the shoulder joint including the possibility to test its motion after reconstruction. A headrest was used to stabilize the patient's head and keep the body in a straight-up position. The procedure was performed under general anesthesia.

The surgeon was positioned in front of the patient's shoulder to be able to perform surgery together with his assistant. The C-arm was brought over the patient's shoulder with an overscan of 45°. Fluoro mode was set up at 8 pps as the CMOS detector delivered the image desired for the surgeon, while minimizing dose.

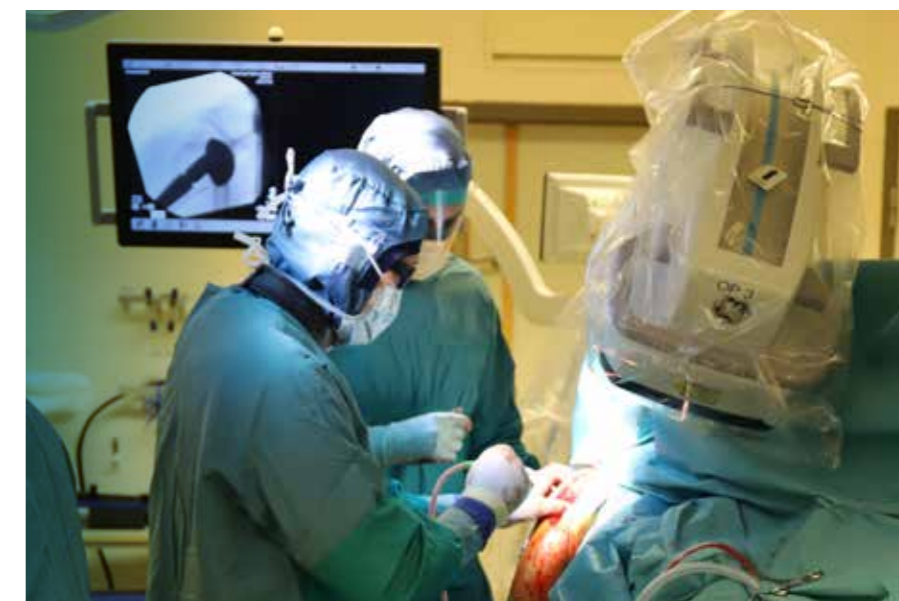Before starting the incision, the surgeon took a fluoroscopic image in AP view to verify the fracture and the dislocation of the humeral head (see Figure 2). This AP view also confirmed that the patient was in the correct position for surgery. Once done, the C-arm was then removed from

the operating field to proceed with the incision. Once access to the humerus was established, the surgeon performed the careful removal of the bone fragments under visual control. Only those that have the tendons of the rotator cuff inserted were preserved. Fragments that are not useful were removed, and the humeral head was resected under visual control.

The next step consisted of preparing the humeral canal to receive the stem of the prosthesis. The proper stem diameter was then determined with a gauge. The implant stem was inserted and oriented. The size of the humeral head of the implant was evaluated with a gauge. The depth of the stem and the size of the humeral head were verified under fluoroscopy (see Fig. 3). Another fluoroscopy control was

performed to check that the humeral head curvature matched with the glenoid cavity (see Fig.4). The trial components were removed and replaced by the final stem. The position of the tubercles within the glenoid cavity were checked under fluoroscopy (see Fig.5) using the Live Zoom feature to confirm it (see Fig. 6).

Functionality of the muscles of the rotator cuff was checked by performing internal-external rotation under dynamic fluoroscopy recording. Once the attachment of the tubercles was confirmed, the incision was closed.



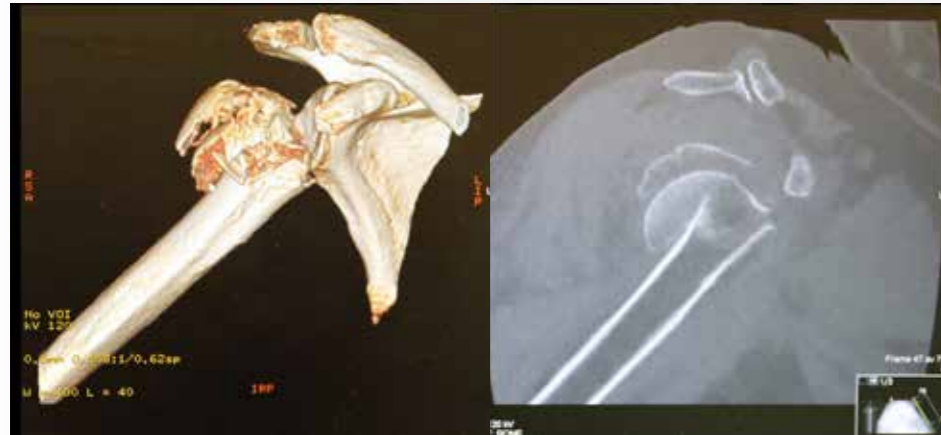


Fig.1: pre-op CT scanner 3D rendering (left) and sagittal view (right) of proximal humeral fracture

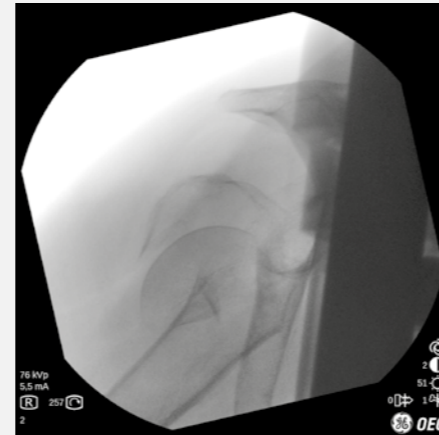


Fig.2: AP View of proximal humerus fracture

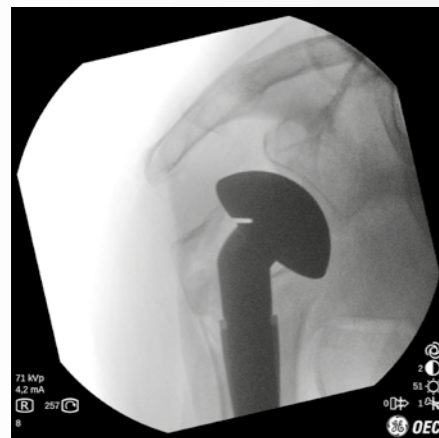


Fig.3: AP View - humeral shaft and head gauge control

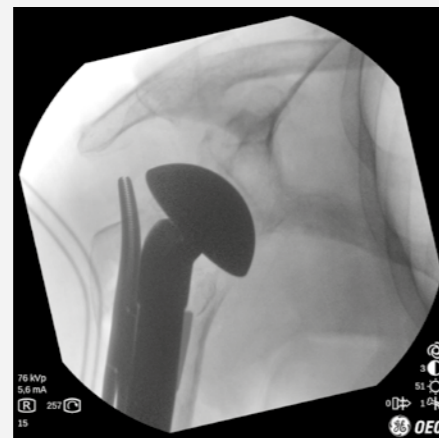


Fig.4: AP View - control of the match of the humeral head gauge with the glenoid cavity

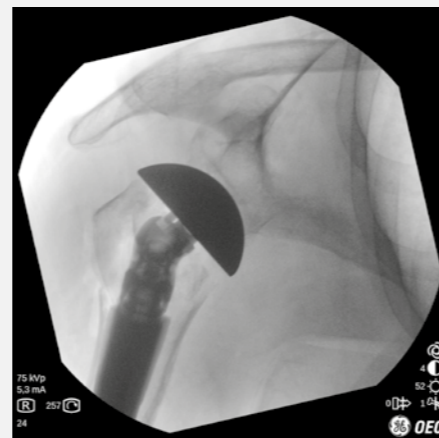


Fig.5: AP View - control of shoulder reduction with final implant

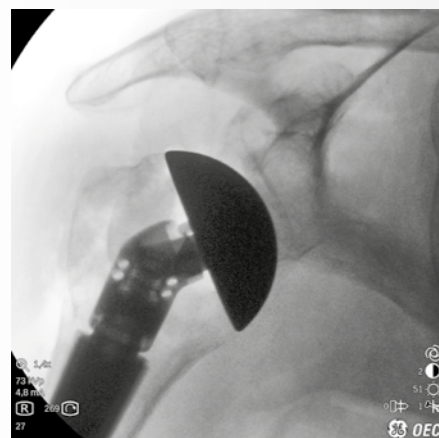


Fig.6: Live Zoom acquisition of final implant with the glenoid cavity

## OEC One CFD - A Nurse's choice

Jorgen Hardstedt, Chief Nurse

**Chief Nurse Jorgen Hardstedt has been working as an OR nurse for many years. He now manages the orthopedic OR: staff scheduling, the organization of the material and equipment, as well as the instruments needed for special operations. The orthopedic procedures are performed across five operating rooms. The ward is equipped with five C-arms that are shared between the various activities (pacemakers, endoscopy, and orthopedics) and two G-arms that are dedicated to hip fracture reduction.**

**Can you explain how the OEC One CFD C-arm is assisting management of your operating rooms?**

*In our process for the selection of a new C-arm, the surgeons defined the level of image quality they need, and the nursing staff looked at the practical aspects of the manipulation of the C-arm.*

*Our orthopedic OR is about 36 m<sup>2</sup>. We want to keep the room very clean and uncluttered. One main criterion for the choice of the OEC One CFD is its 'All-in-One' compact design. The OEC One CFD C-arm is light and easy to transport from one room to another.*

*Another important point for the nursing staff is the ease of use of the C-arm. It is even more important for our trauma patients. We wanted a C-arm with a user interface that is easy to work with. To start taking images, we don't have to choose a program, we just plug the C-arm in and it's ready to go. We don't even need to enter the patient file; we just take pictures during the procedure. If we want, we can complete the patient file afterwards. The wireless footswitch is also important: it reduces the risk of tripping hazard due to cords or contamination.*

*We use the laser aimer to center the*

*C-arm over the patient. If the doctor forgets to turn it on, we can activate it from the Touch control panel. We can orientate and turn the image. The Live Zoom feature can be activated like on a smart phone, which makes it intuitive and easy.*

*For some procedures, we need to switch the C-arm to the contralateral sides. With the OEC One CFD C-arm, it is very easy as we can unplug the C-arm for 5 minutes without turning it off, while we change sides and plug it back in.*

*With the CMOS flat detector, the image looks good without needing to choose a protocol or adjust the X-ray loading factors to a specific anatomy. The OEC imaging software does it automatically. These are small things, but they significantly improve the workflow, and when you use the OEC One CFD C-arm every day it makes all the difference.*

## OEC One CFD - A regular user for orthopedics department

Towe Jarlfors, Nurse

*I love the fact that it is one piece of equipment with most of the controls located in the same place on the tablet, so I don't need to keep going back and forth between the C-arm and the workstation. I know that I will find all the controls I need on the tablet, and so I just go there to do what I need to do.*

*The green laser aimer helps to position the C-arm over the patient. I like to be able to turn it on from the tablet in*

*case I need it without asking the surgeon or his assistant in the sterile field. When I position the C-arm with the help of the laser aimer I have noticed that we need to take fewer images and, therefore we reduce the radiation dose.*

*Before bringing the C-arm over the patient, I apply light tension to the brakes. The surgeon can adjust the C-arm to get the right angle. The*

*C-arm is very stable and stays in place. The surgeon can find the right angulation himself, whereas previously I had to do it. It was more complicated to understand what angle the surgeon needed and in what direction I had to maneuver the C-arm to get it.*

*The wireless footswitch is nice and easy to clean.*



## OEC One CFD - A Biomedical Engineer's choice

Andreas Magnusson, biomedical Engineer

**Andreas Magnusson is the biomedical engineer in charge of the mobile C-arms used in the operating rooms.**

**Mr. Magnusson explains what criteria he considered for the selection of OEC One CFD for trauma orthopedic surgeries.**

"When we select new equipment, we consider the cost effectiveness, the ease of use, and the performance of the product. We work collectively with the physicists and the clinical staff to select the best C-arm for the activity. We asked the different manufacturers to come over for one week of demo with their C-arm so it could be tested by the different members of the team.

Our physicists were involved in the evaluation of the radiation dose. They concluded that the level of dose for OEC One CFD was low compared to other C-arms. This is one benefit from the CMOS detector: high image quality at low dose. It was one of the criteria of choice among the different brands of C-arms we tested.

From the technical standpoint of the biomedical engineer, we wanted to select the C-arm with the best compromise between image quality and ease of use. If the user interface of the C-arm is cumbersome, it doesn't matter how good the image quality is. The operating room is an increasingly complex environment, with an increasing amount of equipment to be used by the staff. New equipment should be very intuitive to use without additional stress.

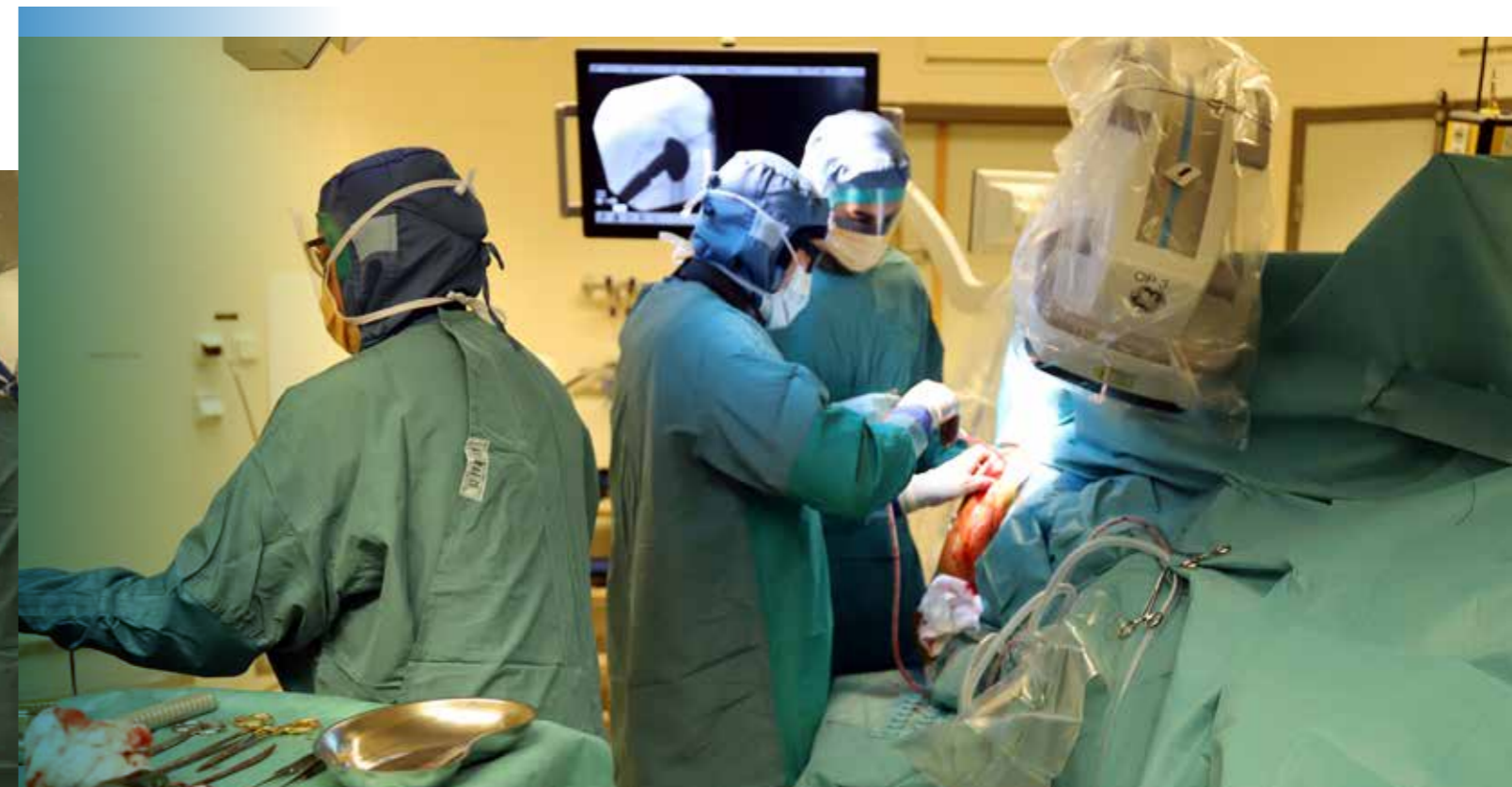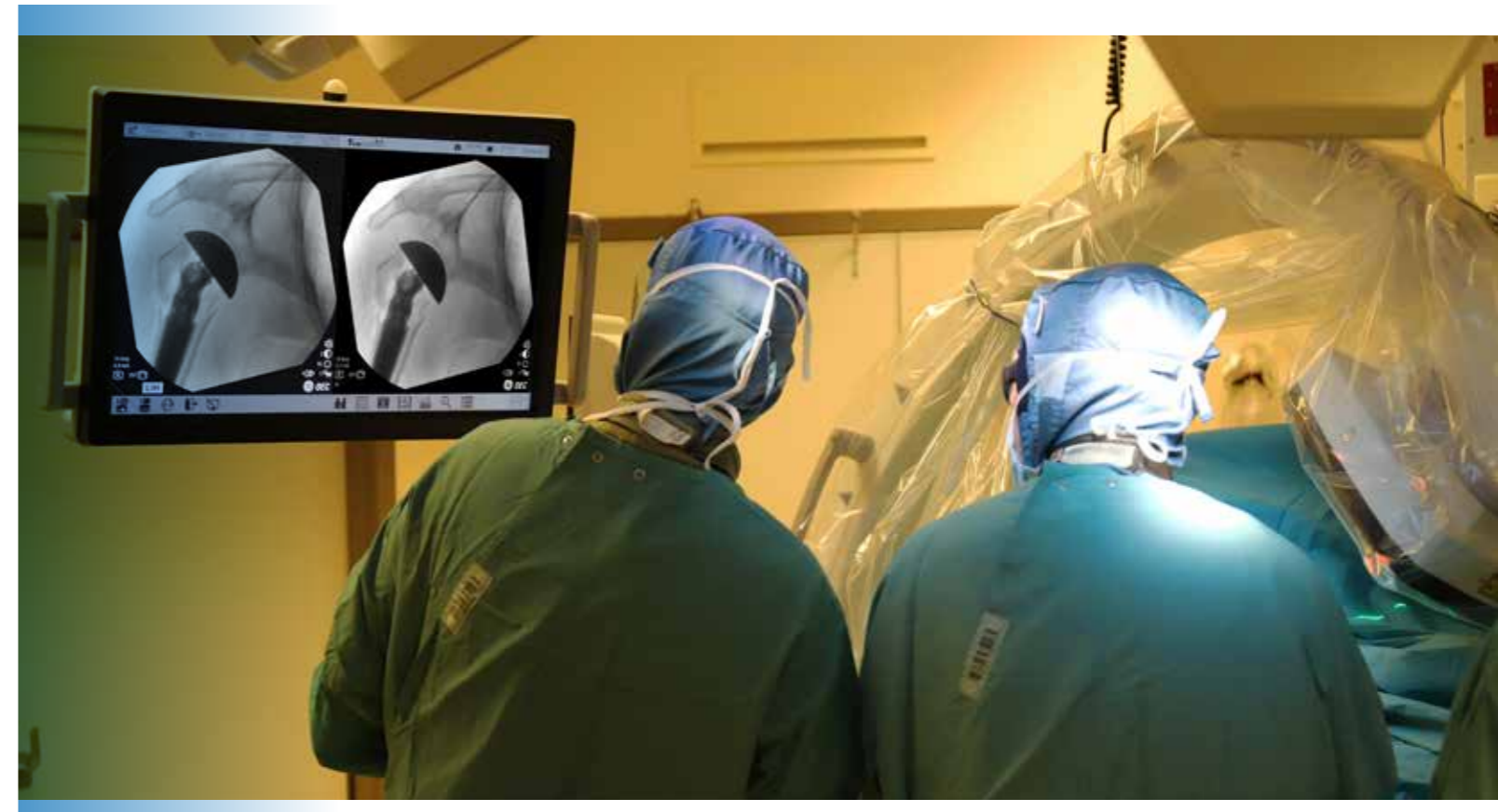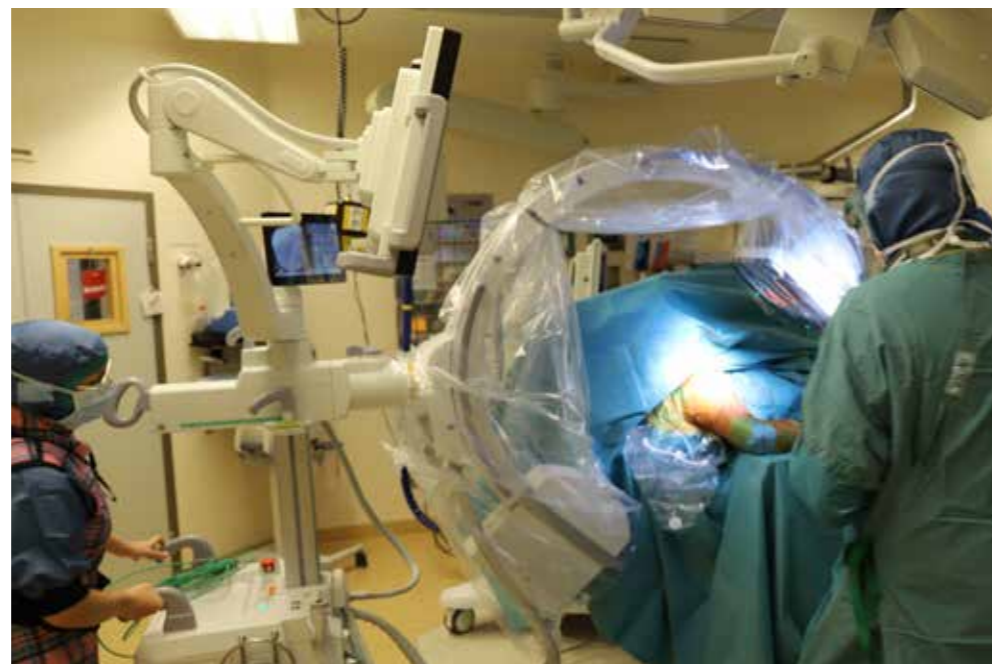The OEC One CFD was convincing in that sense: the menus have large and easy-to-understand icons, and I was also able to set up the OEC One CFD C-arm quickly within the hospital network.

The 'All-in-One' compact design is important for us. It is an improvement not having the C-arm mainframe and a separate cart for the video monitor that has to be moved from one OR to the next. In our orthopedic activity, there is no need for the extra monitor cart because we can connect the C-arm to any external monitors in the OR. We like this configuration because it avoids the need to handle the monitor cart and reduces the congestion of the operating room with equipment and cables.

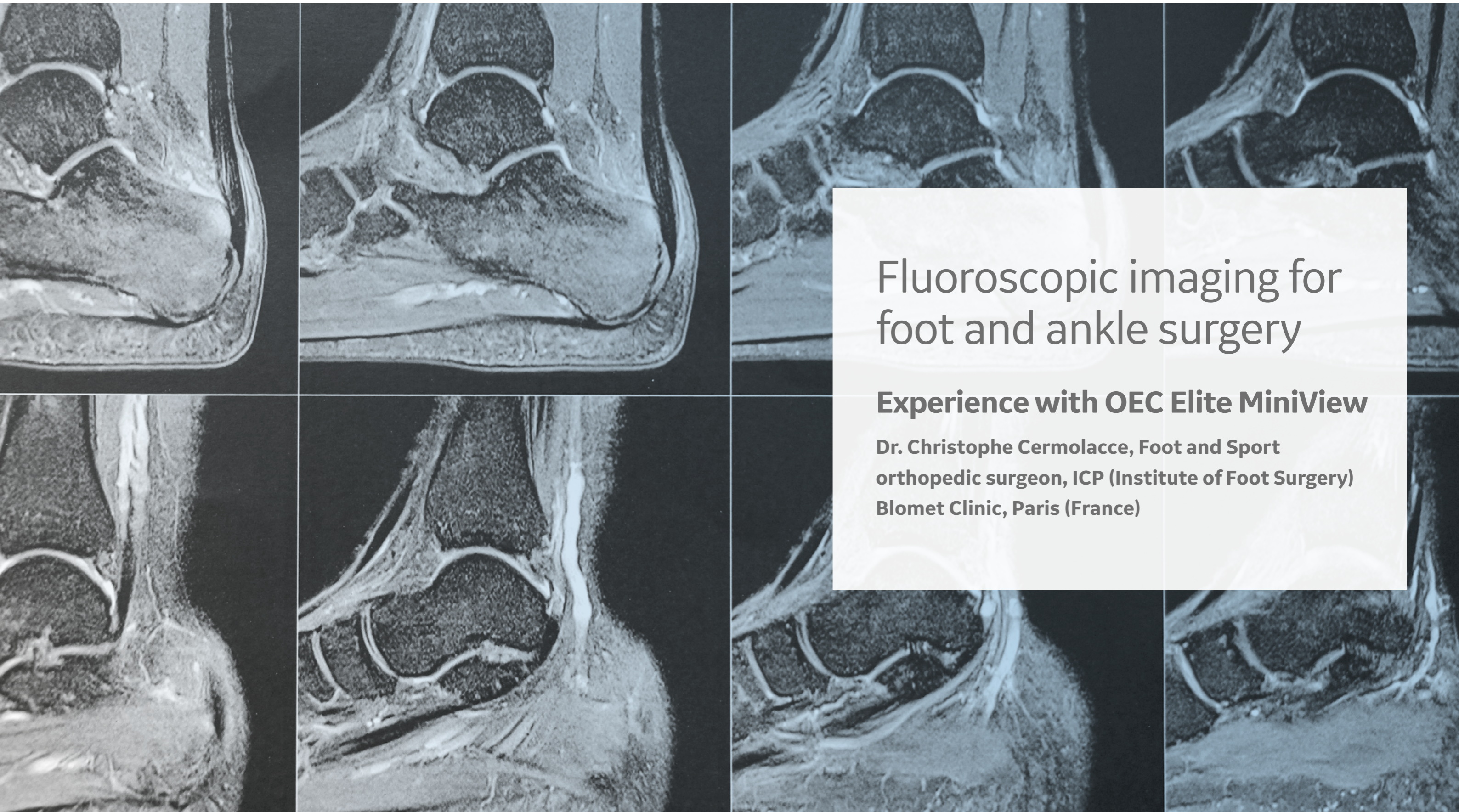
When we tested the image quality, I

knew that surgeons want to see fine details such as the cortical bone lines or the fracture lines. We knew that the enhancement of image quality is due to the CMOS digital detector that the team has already been using with the OEC Elite CFD C-arm. Compared to our older C-arms that don't have a CMOS flat detector, the improved image quality was immediately perceived by the surgeons. They say that they can see the very fine details in the bones and the surrounding tissues. This is something that was immediately highlighted by the clinical staff.

In the future, it will be difficult to go for anything other than a CMOS detector. The image quality increased significantly and we benefit from reduced dose."



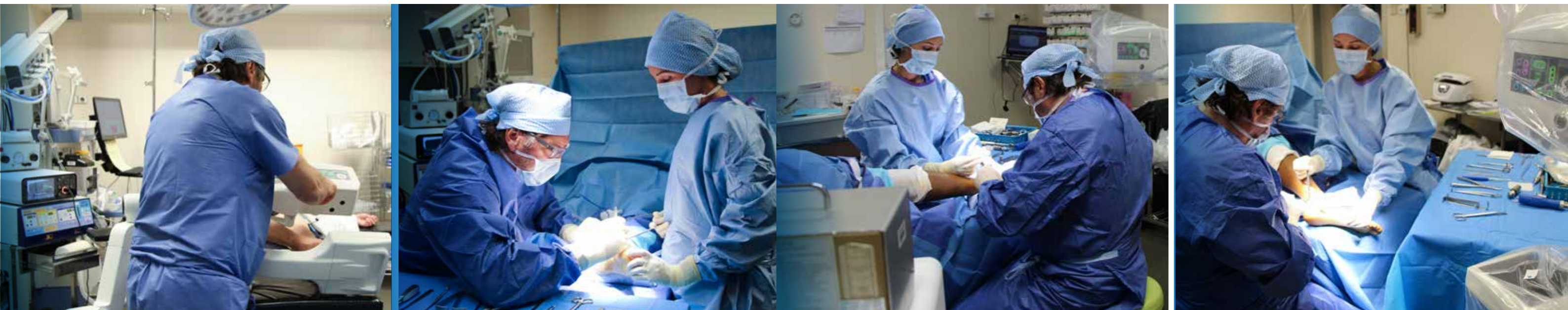
The statements by GE's customers described here are based on their own opinions and on results that were achieved in the customer's unique setting. Since there is no "typical" hospital and many variables exist, i.e. hospital size, case mix, etc., there can be no guarantee that other customers will achieve the same results.



# Fluoroscopic imaging for foot and ankle surgery

## Experience with OEC Elite MiniView

**Dr. Christophe Cermolacce, Foot and Sport  
orthopedic surgeon, ICP (Institute of Foot Surgery)  
Blomet Clinic, Paris (France)**



**What are the main criteria that made you choose the OEC Elite Miniview C-arm for foot surgery at the Blomet Clinic in Paris?**

My partners and I at ICP Paris tested several mini C-arms in accordance with our buying process. The two main criteria that brought us to select the OEC Elite Miniview C-arm are image quality and arm mobility.

The image that we obtain with our OEC Elite MiniView is clear, in particular at the level of the ankle, which is my concern as the surgery of the ankle accounts for a large proportion of the procedures I perform. With some other mini C-arms, we do not see the ankle because the beam is not powerful enough to pass through it. With the OEC Elite Miniview, the beam penetration is sufficient to provide a clear image with the details of the small bones of the ankle.

The flexibility of the articulated arm allows me to position the system in the axis of the patient's legs, at the end of the patient table, instead of placing it on the side of the patient bed, as is the case with other mini C-arms. This setup, in the prolongation of the patient's legs, is more comfortable for the surgeon. With my assistant we can sit on each side of the foot and change position. Once the OEC Elite Miniview is in place, I do not move its base anymore. To acquire the images, I simply move the articulated arm and I can automatically lock and unlock it with one button. The articulated arm can be pushed away from the operating zone and parked quite easily.

Image quality and maneuverability are the two most important criteria for my foot surgery activities. I now use fluoroscopic imaging guidance and control for at least 40% of the several hundreds of procedures I perform per year.

**Can you describe the main procedure in foot and ankle surgery for which you need to use fluoroscopy?**

In this department, we use fluoroscopy in all ankle arthrodesis procedures (subtalar, talocalcaneal, tibiotalar) to verify the length of the screws and the bone mating after fusion. One colleague is specialized in percutaneous-access surgical techniques in the hindfoot and midfoot. Because the incisions are the smallest possible, he needs continuous fluoroscopy control to guide his tools while doing osteotomies and milling.

In my specialty of sport medicine, I also use fluoroscopy extensively for the treatment of the ankle, as for example when I treat the osteochondral lesions of the talus (Talus Dome Lesions TDL). Recent treatments consist of injecting medullar stem cells at the basis of the necrosis of the talar bone to stimulate

*“Image quality and maneuverability are the two most important criteria for my foot surgery and the OEC Elite Miniview allows me to see the small details of ankle bones.”*

**Dr. Cermolacce**

the regeneration of the cartilage. The injection is done after the curettage is performed via intra-articular access. As the injection point is difficult to reach, I guide the insertion of the needle using fluoroscopy to go underneath the TDL.

There are several other procedures where I use fluoroscopy such as the treatment of strong tendinitis of the calcaneus (see the clinical illustration below). In this procedure, the approach is minimally invasive to be able to inject stem cells and boosters. I need to use fluoroscopy because it is very difficult to see the calcaneus, and I need to make sure its axis is correct after the osteotomy.

In forefoot and midfoot surgery, hallux valgus deformity surgery, and with the Lapidus procedure, we systematically use fluoroscopy. The goal of the surgery is to stabilize the first metatarsal (M1) at its basis with the cuneiform bone C1, to maintain it at the right location while there is hyper-laxity of the tendons. We do not need a large number of images, but after completing the wedge resection and closing, we need to verify the axis of the metatarsal bones (M1 and M2). Today we know that the

metatarsal head has to be in the same axis as M2 so it can regain its role of support for the other metatarsals. If this geometry is not maintained, there will be a relapse of the deformation. We therefore check the positioning of the M1 head and the axis of the head using fluoroscopy. We then verify the length of the screw put in place.

In some ankle-trauma surgical procedures, often caused by motorcycle accidents, or in post-trauma treatment when there is a luxation of the ankle, we need to precisely verify the anatomy of the foot using fluoroscopy.

**How are foot and ankle surgery techniques evolving and what are their fluoroscopy needs?**

Foot surgery centers are not as well developed as hand surgery centers, maybe because there are no acute pathologies of the foot, and there are

no emergency networks of foot surgery units. While all orthopedic surgeons are trained to perform foot surgery, it is important to emphasize that the anatomy of the foot and the ankle is particularly complex. Surgery techniques to address congenital deformities, neurological dysfunctions, or sport pathologies must be performant to ensure the most performant patient outcome. Many minimally-invasive techniques are being developed, which require guidance using fluoroscopic imaging.

About 20 years ago, we started performing minimally-invasive techniques, which were brought to Spain by Dr. Mariano de Prado from American podiatrists (forefoot surgeons). He demonstrated that this type of surgical access ensures the preservation of muscles and tendons, and he started to train other European

surgeons in the use of the technique. My partners and I trained with him and to sustain this best practice of evaluating and validating minimally-invasive foot and ankle surgery, we created an international association made up of orthopedic surgeons called GRECMIP. Today foot surgery requires multidisciplinary techniques (percutaneous, minimally invasive and open access surgery). One mission of GRECMIP is to provide training in the most appropriate techniques to treat a given pathology.

With this goal of developing the ankle and foot surgery specialty, we decided to create this center of excellence in Paris (ICP Blomet Clinic). We recruited surgeons from different regions (Paris, Lyon, Bordeaux, London) based on specific surgical skills. The goal of the team is to contribute to the development of new surgical

techniques, and new implants for the surgical treatment of the foot and ankle. Currently we are working on the development of new procedures based on stem cell therapy.

Today foot and ankle surgery is codified and validated. We see an increase in the demand for procedures because we can now offer better treatment.

I was able to develop foot and ankle surgical management for professional athlete, thanks to minimally invasive surgical techniques. This is a very interesting domain in continuous development. The pathologies of professional athletes are very specific, and the surgical techniques need to be tailored to this. Once validated, these surgical techniques can be beneficial to other traditional patients. □



**Dr. Christophe Cermolacce** is an orthopedic surgeon. In 1992, he completed his fellowship with Pr. Groulier (University of Marseille) in orthopedic surgery. An associate of Pr. Franceschi, he specialized in the surgery of the foot, a discipline that was not recognized at that time. He trained in the United States with foot surgery specialist Dr. Weil, and in France with Dr. Barouk who brought a new forefoot bone procedure from the US, the so-called Scarf technique (for hallux valgus deformity). Dr. Cermolacce started his foot surgery activities with these procedures in Marseille and joined the Clinique Juge focusing on orthopedic surgery of the lower

limbs.

From his collaboration with Pr. Franceschi, he developed his interest in sport surgery, estimating that minimally-invasive surgery techniques should be considered to manage sport injuries. Dr. Cermolacce is consulted by professional athletes from Marseille's soccer team (Olympic de Marseille), as well as local basketball and rugby clubs, for ankle sport pathologies. His goal is to develop a similar activity in the Paris area. This year, he will join the team managing Stade of France athletes.

The statements by GE's customers described here are based on their own opinions and on results that were achieved in the customer's unique setting. Since there is no "typical" hospital and many variables exist, i.e. hospital size, case mix, etc., there can be no guarantee that other customers will achieve the same results.

# Surgical excision of accessory navicular bone in a dancer's foot

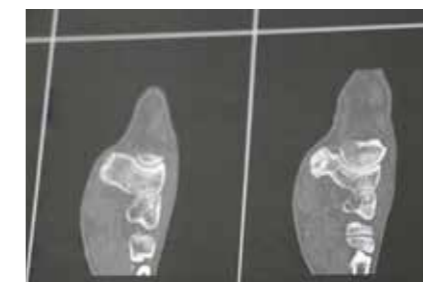
## Challenge

A 25-year-old female presented with chronic pain due to synchondrosis development between the accessory and the navicular bone. Diagnosis was confirmed by MRI (see Figure 1). Examination showed the prominence of the navicular bone from the head of the talus. Conservative therapy (physical and medication) gave inconclusive results. The patient approached the clinic for minimally-invasive surgical treatment using a surgical technique recommended for athletes and which has become increasingly prevalent over the last few years. The procedure consists of the excision of the accessory navicular bone leading to the reduction of its prominence. The surgical procedure is followed by physical therapy to reinforce musculature.

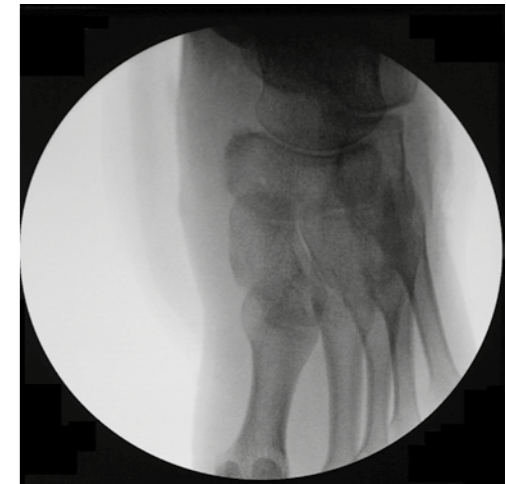## Procedure

Surgery for this pathology is the last solution after conservative treatments, to reduce the pain, and recover mobility. It is very important for the athlete going through surgery to recover as fast as possible in order to go back to her training activity. While structural bone recovery can be obtained within six weeks, the physiological recovery requires an additional three months. Stopping training over such a long period (five to six months) can be very disruptive for high-level athletes. This is why they turn to sport

surgery techniques, which are less invasive. Minimally-Invasive Surgery techniques, combined with stem-cell treatment, allows a return to training two months after the surgical intervention. Stem-cell treatment allows a decrease in the healing time of the osteo-cartilaginous wound. This consists of the injection of Platelet-Rich Plasma (PRP) in the lesion created by the bone resection. PRP is obtained by collecting a blood sample that is processed by centrifuging to obtain a serum in which periostin protein, an osteogenic agent, is concentrated. PRP is harvested in the operating room before starting patient anesthesia. It is implanted over the bony wound after surgery, before suturing the skin incision. A final verification of the bone excision is performed using fluoroscopy (see Fig. 2). The small footprint of the OEC Elite MiniView C-arm allows it to stay in the OR and not interrupt the procedure workflow. The articulation of the arm allows an easy and fast positioning of the C-arm over the patient's foot at the end of the patient table.



**Fig. 1** MRI of the foot showing the disunion of the accessory navicular bone from the navicular.



**Fig. 2** Final verification showing complete removal of the accessory navicular bone.

## Conclusion

The procedure was performed in ambulatory care. The total procedure duration was about 30 minutes. The patient was able to return home the same day of the operation. At the follow-up consultation, the pain had considerably subsided. Patient resumed her professional dancing training two months after surgery.

The statements by GE's customers described here are based on their own opinions and on results that were achieved in the customer's unique setting. Since there is no "typical" hospital and many variables exist, i.e. hospital size, case mix, etc., there can be no guarantee that other customers will achieve the same results.

# Calcaneus osteotomy to correct congenital elongation and Haglund's deformity

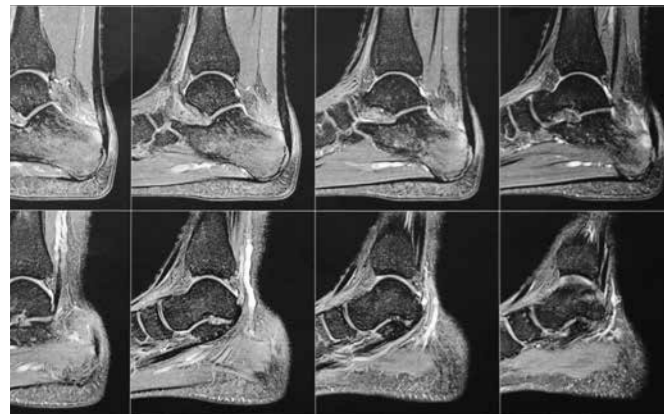

Fig. 3 Sagittal MRI view of the heel.

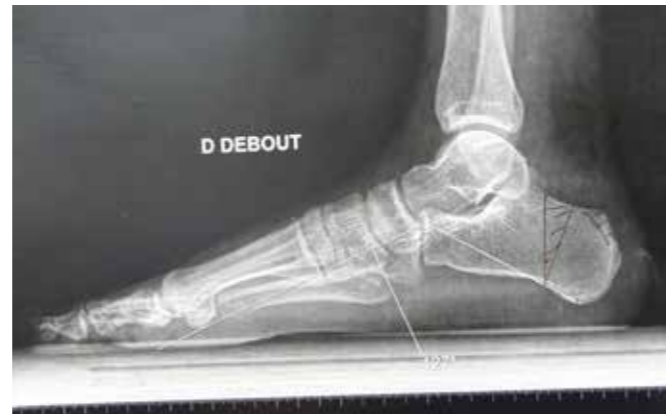

Fig. 4 Lateral X-ray image for surgery planning.

## Challenge

A 37-year-old male was admitted for surgical treatment of a congenital elongation of the calcaneus bone of the right foot, causing chronic Achilles tendon tendinopathy. Diagnosis was confirmed by MRI (see Figure 3) showing a thicker Achilles tendon, calcaneal bursitis, and Achilles tendinosis.

The treatment selected was calcaneal osteotomy and calcaneus fixation with internal screws, through a minimally invasive approach.

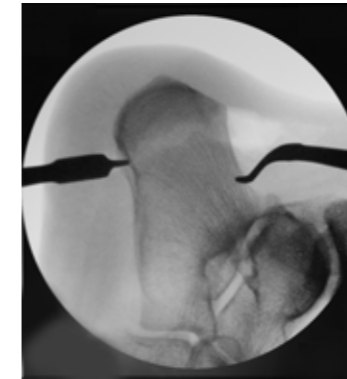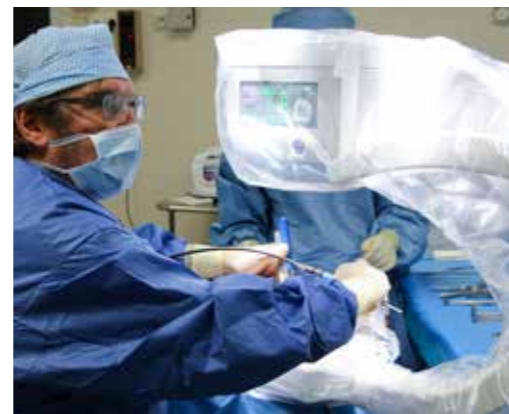Fluoroscopic imaging was used to check the line of bone resection and the offset of the alignment of the

calcaneus after osteotomy to ensure that the vertical axis of the calcaneus was preserved. As the approach was minimally open, this verification cannot be performed visually.

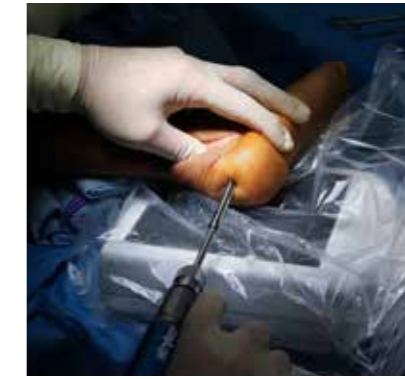## Procedure

The procedure consisted of the removal of a triangle of bone, the closing of the bone wedge, and the anchoring of the calcaneus with two screws to stabilize the osteosynthesis. The approach was minimally open to permit the injection of PRP in the lesion created by the bone resection. The patient was put in prone position with the C-arm positioned at the end

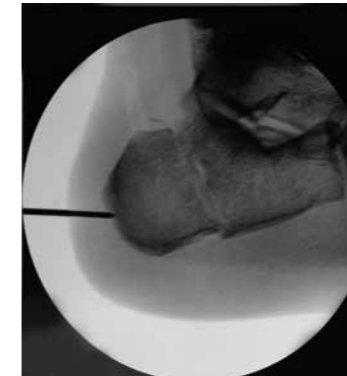
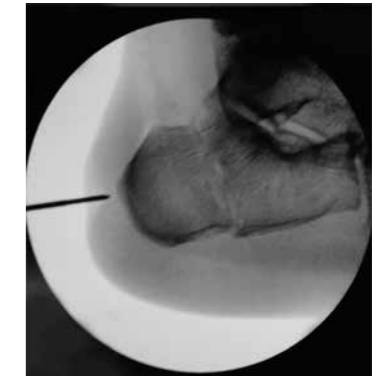
of the patient table in the axis of the legs. The procedure was performed under general anesthesia.



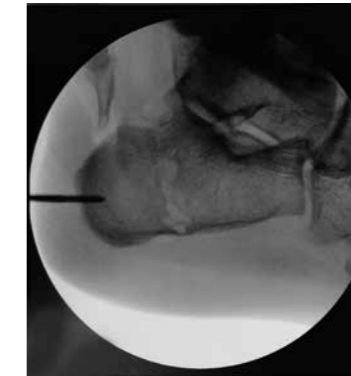
Definition of osteotomy line – calcaneus profile view.



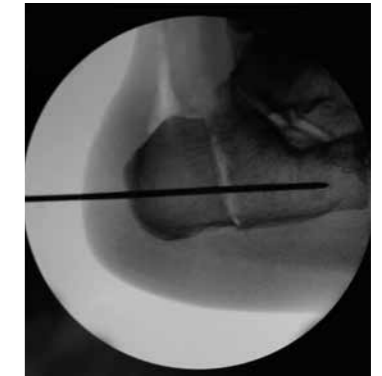Drilling of the calcaneus under fluroscopic imaging guidance.



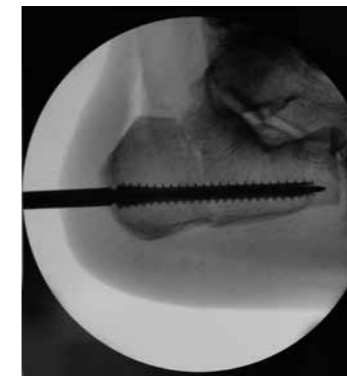Drill final positioning and orientation for the first screw.



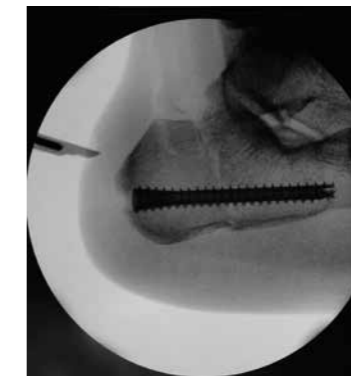
Drill progression in the distal area of the calcaneus.



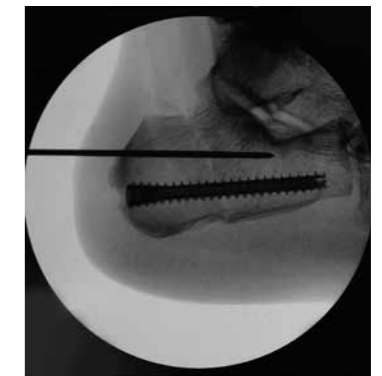
Drill progression in the proximal area of the calcaneus.



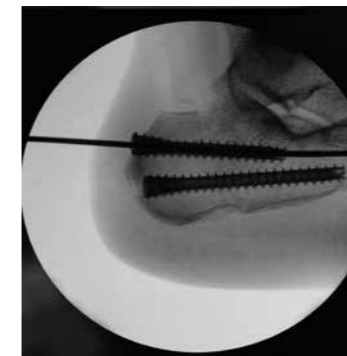
First screw placement.



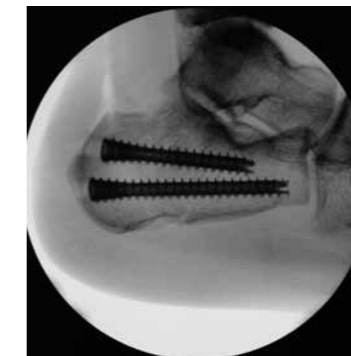
First screw placement.



Entry point definition for second screw.



Second screw placement.

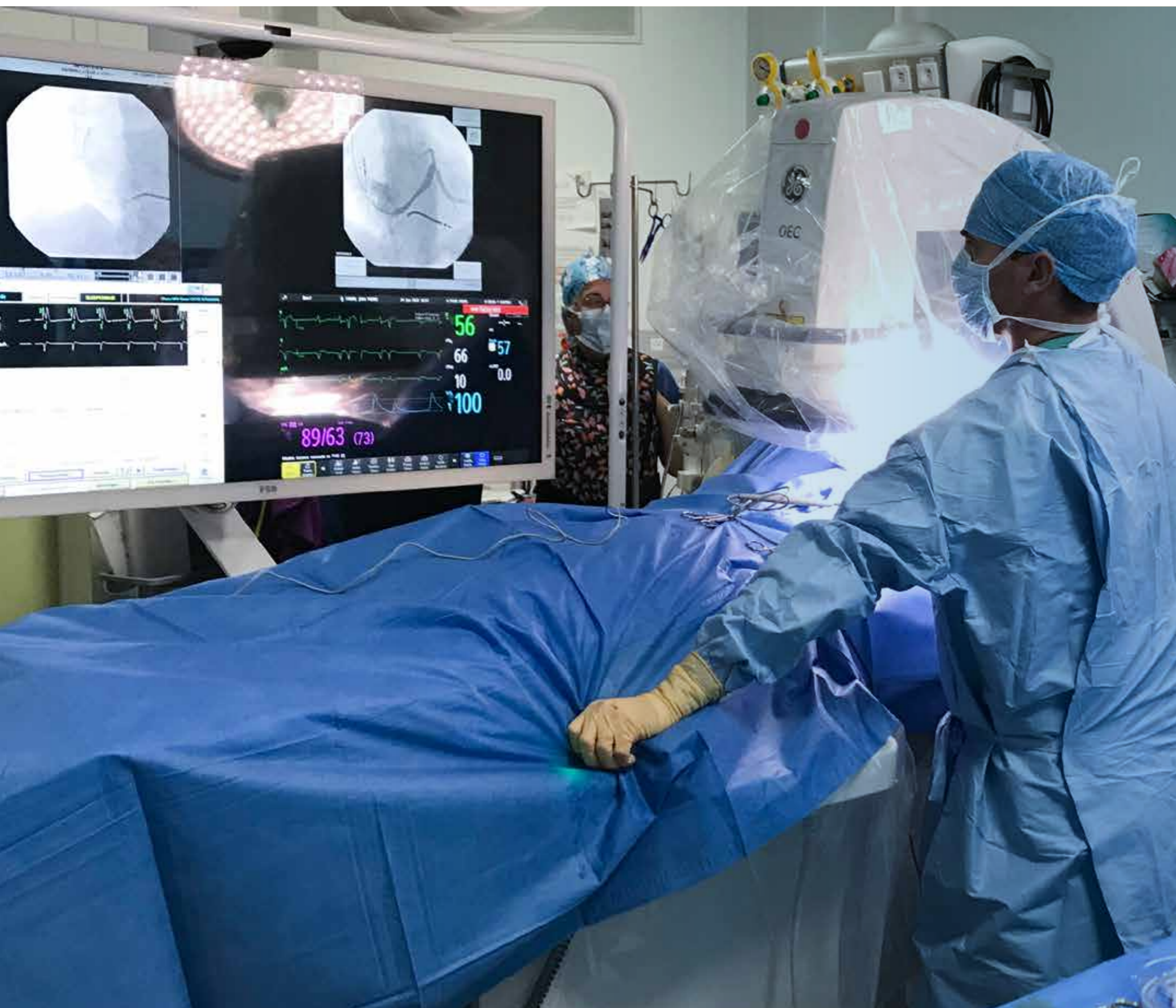

Final verification image of calcaneus anchoring.

## Conclusion

OEC Elite MiniView was set in continuous fluoroscopy and low-dose mode. The total procedure duration was about 40 minutes. The total fluoroscopy time was 13.8 seconds and total Dose Area Product was 0.0111 Gy.cm<sup>2</sup>. The patient was able to return home two days after the operation. The functional rehabilitation for walking was completed after one month. Upon careful osteotomy consultation, re-athletisation was completed within three months after surgery.

The statements by GE's customers described here are based on their own opinions and on results that were achieved in the customer's unique setting. Since there is no "typical" hospital and many variables exist, i.e. hospital size, case mix, etc., there can be no guarantee that other customers will achieve the same results.

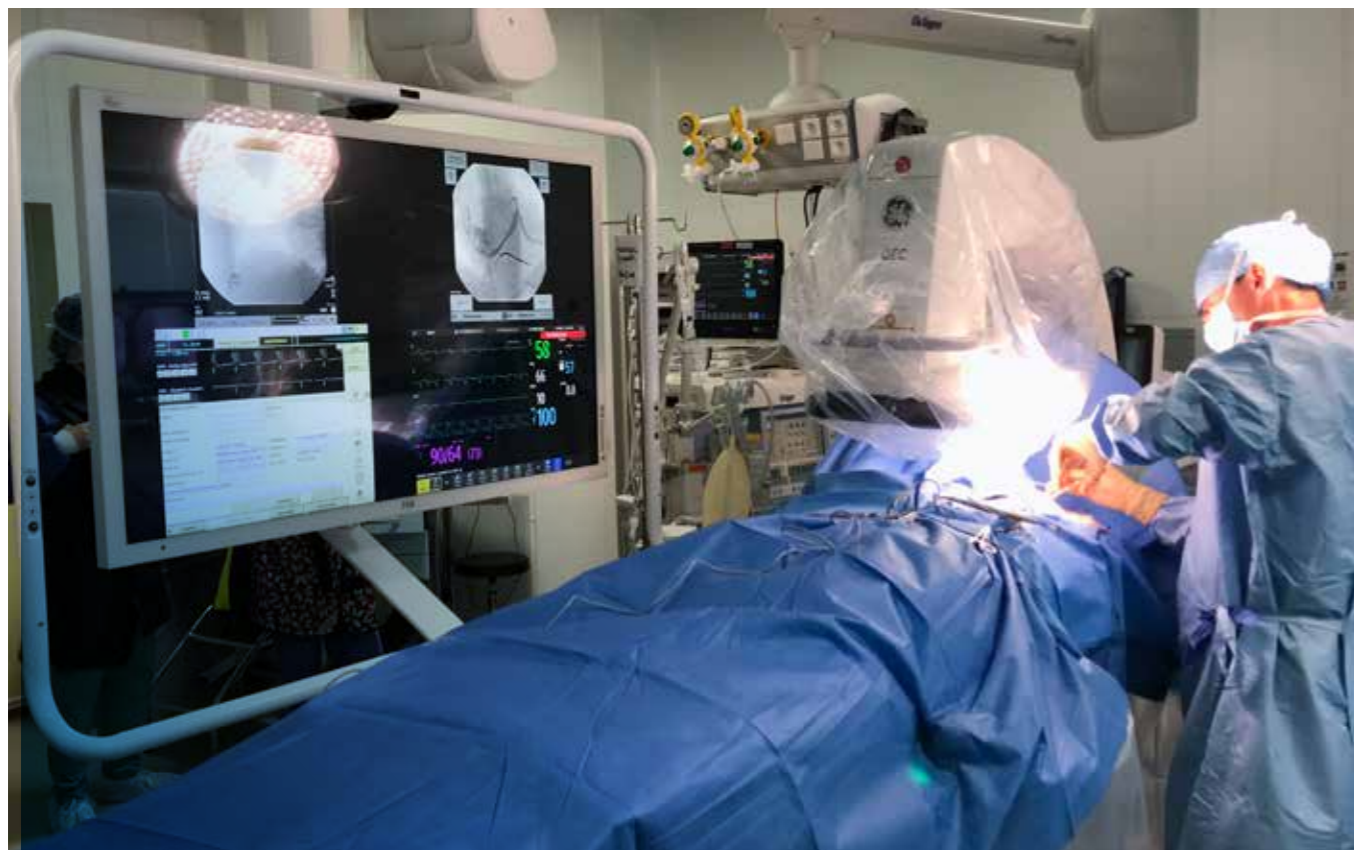

# Interventional Rhythmology with OEC Elite CFD

**Dr. Stéphane Combes, Cardiologist and Interventional arrhythmia specialist, Clinique Pasteur, Toulouse (France)**

The Clinique Pasteur is the leading cardiology and cardiac surgery institution in France in terms of number of procedures. The recently completed building called La Passerelle - The Bridge, has been designed by and for caregivers, such that all necessary services have been built and organized under one roof. Equipped with high-tech imaging modalities dedicated to complex treatments, it is aimed at optimizing the patient's care pathway.

Among the eight cathlabs dedicated to Interventional Cardiology, Electrophysiology and Rhythmology, one room has been equipped with an OEC Elite CFD motorized Cardiac C-arm, dedicated to pacemaker placement and CRT device implantation.



Dr. Stéphane Combes, Interventional rhythmology Cardiologist, explains the needs in image quality and patient access with OEC Elite CFD for these procedures.

**Can you explain the organization of the activity of the Interventional Rhythmology department?**

There are about 30 cardiologists at Clinique Pasteur. Everyone has a different specialty to cover across the different cardiology domains. Our rhythmology group specializes in placing cardiac stimulators to provide arrhythmia treatments. As a national reference center of excellence, we participate in national and international research studies in rhythmology for cardiac stimulation and the management of ventricular and atrial disorders.

The Pasteur Clinic's department of rhythmology performs more than 1500 ablations per year, as well as the implantation of about 900 pacemaker and multisite cardiac stimulators, and 150 to 200 defibrillators.

**What type of procedures are performed in the mobile C-arm room?**

The procedures performed in this room are essentially stimulation, including multisite stimulation and defibrillation procedures. We sometimes perform simple ablation procedures in this room, i.e. endocavitary electrophysiological exploration and

ablation of the cavo-tricuspid isthmus or of the HIS junction.

We reserve fixed angiography rooms for complex procedures that are of three types: procedures that require a transeptal puncture in order to realize an ablation into the left atrium, the ablation of ventricular tachycardia, and complex ablation procedures. Complex ablation procedures might involve a higher operating risk for the patient, such as procedures where the positioning of the catheter needs to be very precise like for the ablation of the slow path of the HIS intra-nodal junction. About 50% of these complex procedures are performed under general anesthesia of the patient, and the size of our fixed rooms has been designed to include a large space for the anesthesiologist set-up in case of the need to switch to intensive patient care, that is not the case in our mobile C-arm room. For these procedures, we are using Cartography systems that take up quite a lot of floor space in the operating room and require a dedicated engineer assisting us during the procedure. As our room with OEC Elite CFD is small, we cannot work comfortably with these systems, and cases of acute patient care management require extra space.

**What are the challenges in terms of image quality and detector size?**

The most complex imaging procedures are multisite stimulation, requiring the precise visualization of very small guidewires (about 0.014 inches or 0.35 mm of diameter) while navigating in the venous vasculature of the back of the heart.

It is also critical to see clearly the heart's venous tree and then the

stimulating probes that are a little larger. We need fluoroscopic coverage large enough in order to get a full cardiac shadow in the image. The patients we treat are in cardiac insufficiency with cardiomegaly. There is always a tradeoff between the size of the flat panel, the coverage of the anatomy in the image and the obstruction of the detector in the working space. We work very close to the detector, unlike vascular surgeons who can work away from the anatomy explored. The 21 by 21 cm flat panel detector size is a good compromise. Indeed, if we took a larger detector field of view, would take up too much space and the ratio between the obstruction of the working space to image benefit would not be advantageous.

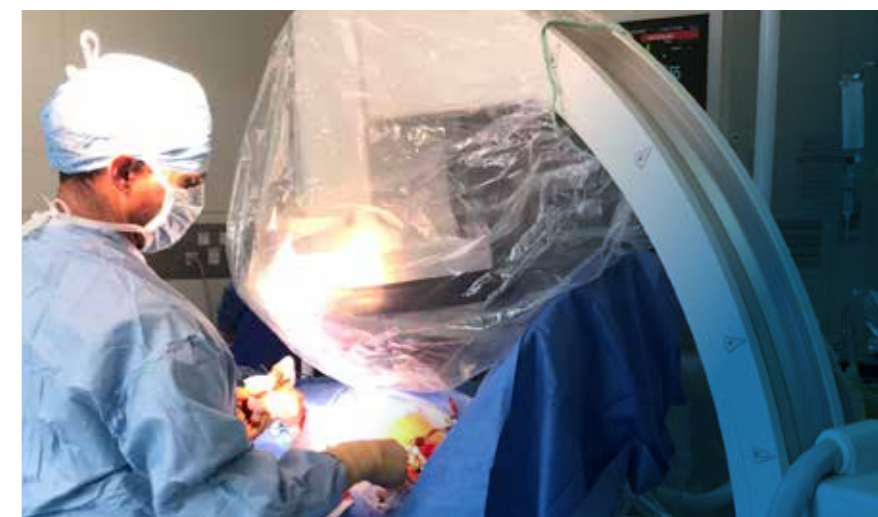
**What fluoroscopy modes do you use during your procedures?**

In our department, we want to optimize the amount of radiation dose during the procedure, so we are working with low-dose modes: decreasing the image rate using the pulsed mode (8 pulses per second

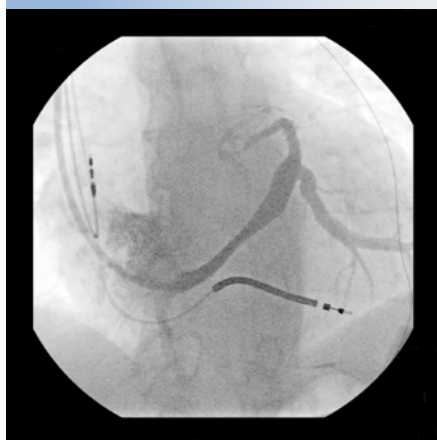
– pps) and decreasing the level of radiation dose using the low-dose mode. Of course, we modify these parameters during the procedure to manage the image quality depending on the complexity of the step of the procedure. It is very easy to improve the image quality by increasing the pulse mode rate from 8 to 15 pps, removing the low-dose mode or setting up the collimation from the Remote User Interface during the procedure.

When performing multisite stimulations, we inject contrast media into the cardiac venous tree, and record the sequence using the dynamic recording mode. We inject the coronary sinus vein to position the probe at the level of the left ventricle in such a way as to safely anchor the probe at the level of a bifurcation. The dynamic recording allows us to visualize the full venous tree in the image in order to select the optimum site to anchor the lead.

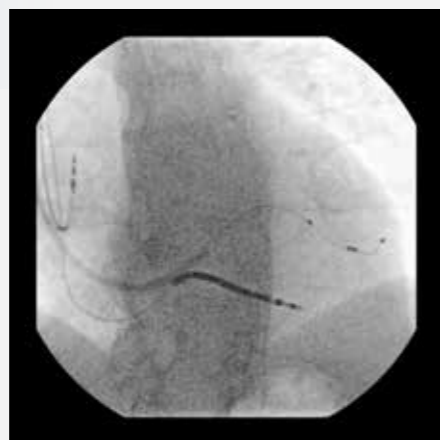
...



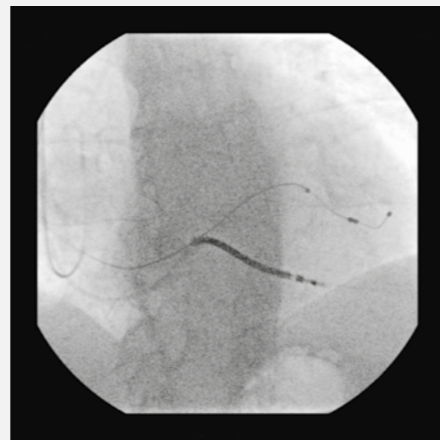
**CASE 1 | Defibrillator implantation**



Coronary sinus venogram - Digital Cine Pulse 15 pps - AP view - Cardiac profile

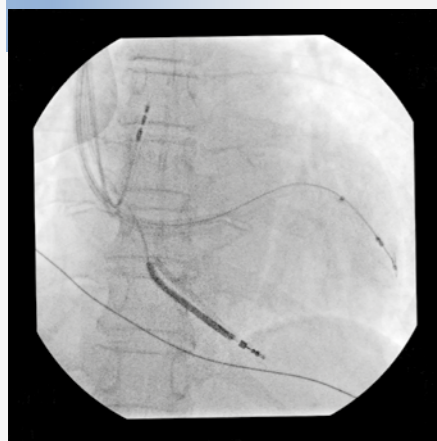


Defibrillator lead placement control - standard fluoroscopy low dose 8 pps - AP view - Cardiac profile



Final control - standard fluoroscopy Low dose 8 pps - AP view - Cardiac profile

**CASE 2 | Multisite pacemaker implantation**



Final control standard fluoroscopy 8 pps - AP view - Cardiac profile

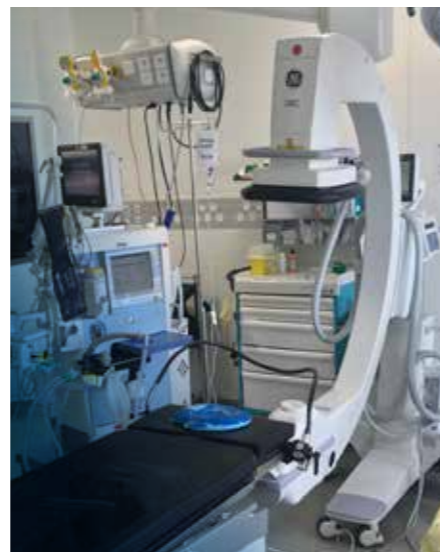**How did you set up the C-arm in the room with space constraints?**

As the C-arm is very deep, we placed it along the axis of the patient table, at the patient head. This position allows us to perform both right and left sub-clavicular accesses very easily. During our procedures, we often angulate the C-arm in order to get right or left oblique views. With this set up it is very easy to modify the angulation of the C-arm without interfering with our working space.

We optimize the space in our operating room. We selected the OEC Elite CFD C-arm in order to avoid the congestion of this operating room.

The remote user interface is very easy to install and remove from the table-side rails. Its ergonomics are quite simple and robust. The interface possesses the essential functionalities,

we do not need more than this. The buttons are easy to activate. We also use it to modify the position of the C-arm from the sterile field. This interface allows the integration of staff into the procedure workflow such that they actively participate in the procedure.

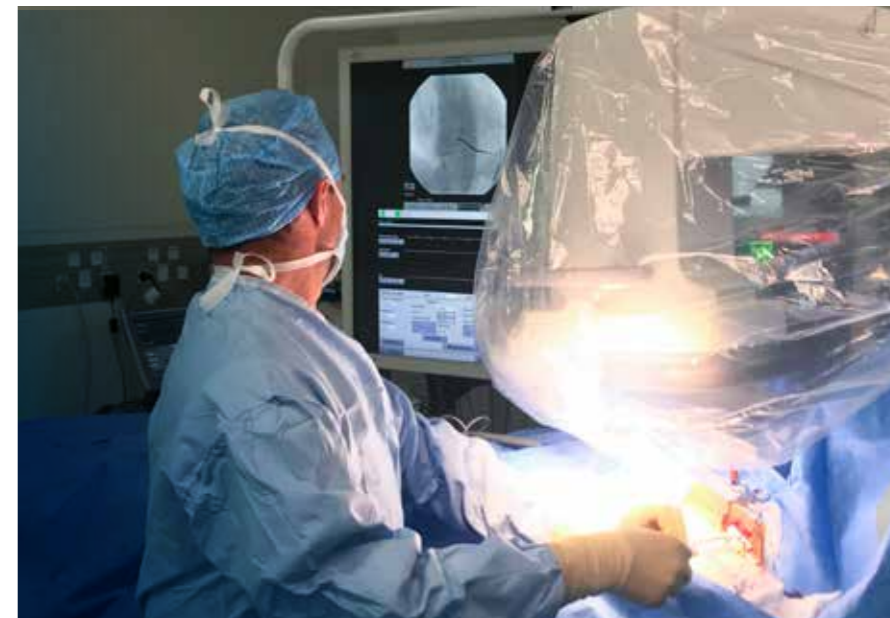

Also the laser aimer is a very interesting tool that can assist in positioning the detector and may limit the number of images taken.

**How do you think fluoroscopic imaging is going to evolve as rhythmology techniques progress?**

In rhythmology, we have two main domains of activity: Electrophysiology/ablation and cardiac stimulation. In Electrophysiology, we are moving towards developing integrated systems without fluoroscopic imaging. We are using cartography systems. They were developed for complex procedures, but now we are using them for simpler procedures. These systems are still expensive, but as they contribute to reduce radiation exposure, we are driving our activity to extend their use.

In cardiac stimulation, we are very far away from working without fluoroscopic imaging. We need fluoroscopic guidance. The evolution of the C-arm needs to go in the direction



of miniaturizing the footprint and reducing X-ray dose.

Today, the cost of cardiac stimulation procedures has been reduced making them accessible to more centers. The OEC Elite CFD mobile C-arm is well

suited to cardiac stimulation procedures. Nothing prevents using the C-arm with a cartography system, only the size of the room determines if we can add an additional system and personnel for the procedure. □

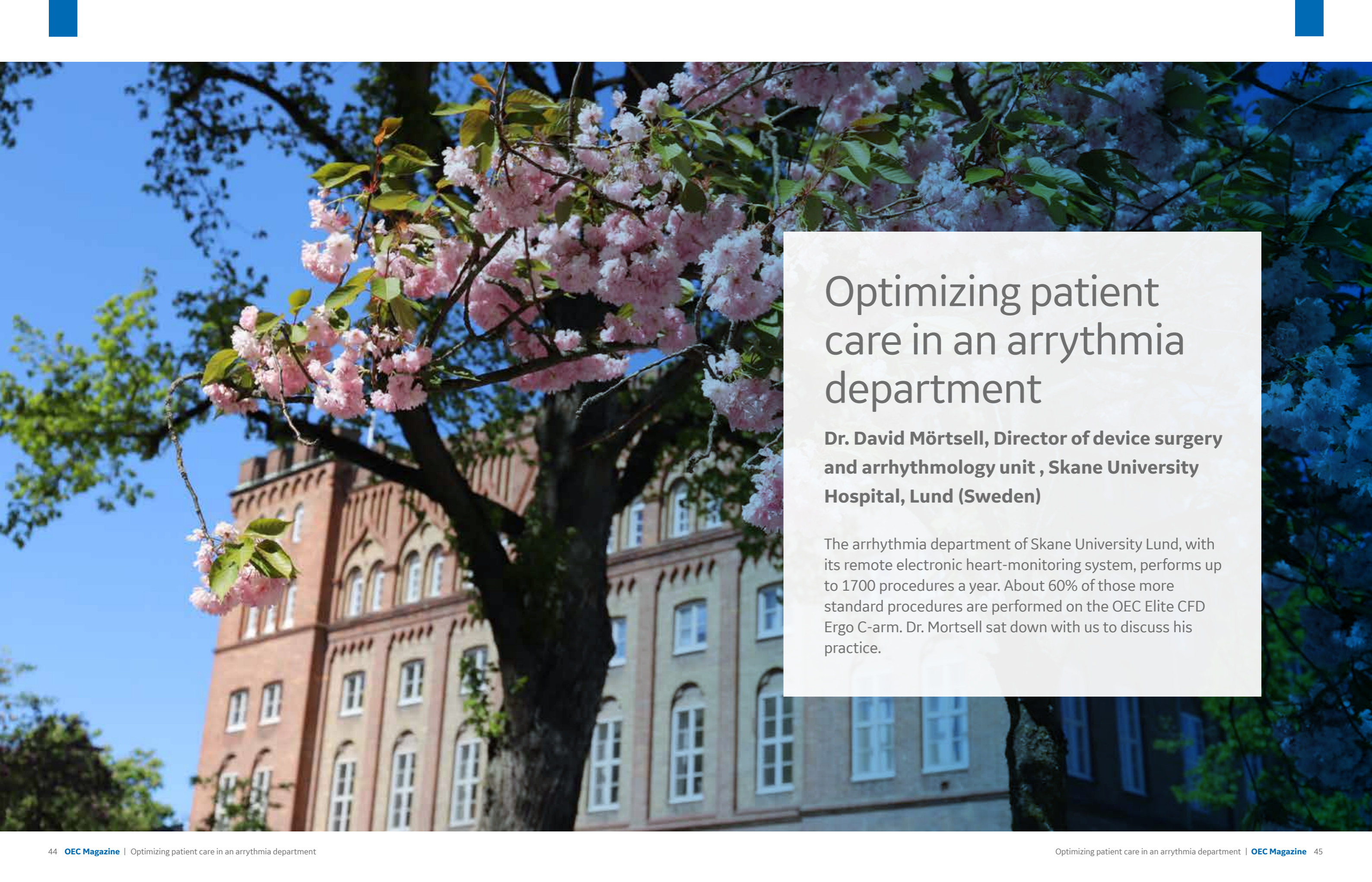

**Dr. Stéphane Combes** is an Interventional Cardiologist specialized in Interventional Rhythmology, after a fellowship in cardiology. He has worked at Clinique Pasteur for the last 11 years, in Toulouse. He is a member of the French cardiology society and of the European Heart Rhythm Association.

Dr. Combes is involved in the RETAC (European network for the Treatment of Arrhythmias in Cardiology), which promotes sharing experiences to improve the management of cardiac arrhythmias, particularly in the field of radiofrequency catheter ablation<sup>1</sup>. With the rhythm group of Clinique Pasteur, he participates in national and international multicentric studies in the field of arrhythmia and stimulation/defibrillation.

<sup>1</sup> <http://www.retacgroup.com/about-us/>

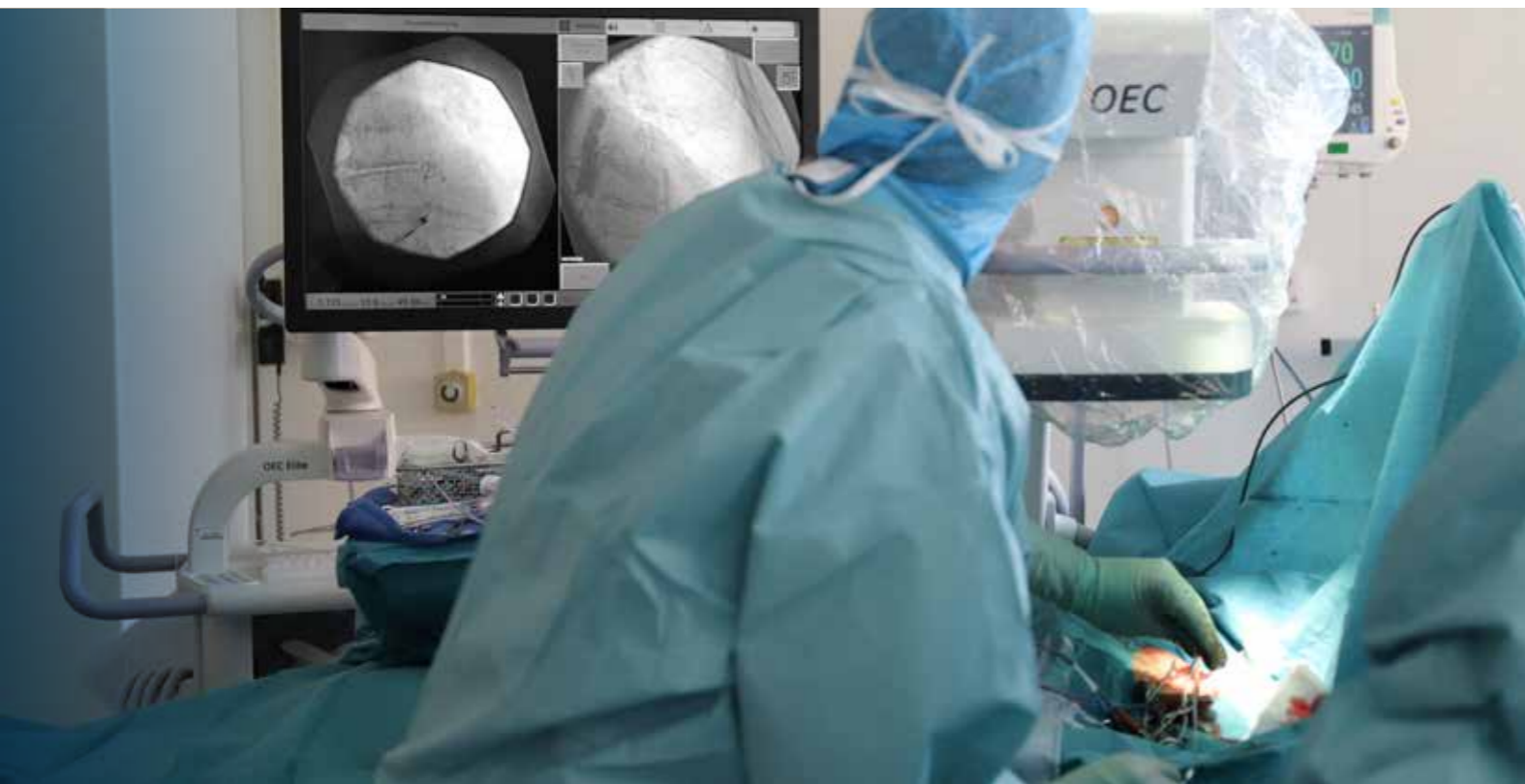The statements by GE's customers described here are based on their own opinions and on results that were achieved in the customer's unique setting. Since there is no "typical" hospital and many variables exist, i.e. hospital size, case mix, etc., there can be no guarantee that other customers will achieve the same results.



# Optimizing patient care in an arrhythmia department

**Dr. David Mörtzell, Director of device surgery and arrhythmology unit, Skane University Hospital, Lund (Sweden)**

The arrhythmia department of Skane University Lund, with its remote electronic heart-monitoring system, performs up to 1700 procedures a year. About 60% of those more standard procedures are performed on the OEC Elite CFD Ergo C-arm. Dr. Mörtzell sat down with us to discuss his practice.



**What are the economic challenges that your department is facing to optimize patient care?**

*Last year, we had a block-budget for 800 devices and 700 ablation procedures and we ended up doing about 1700 treatments. The additional cost was supported by our hospital administration because we demonstrated that it was necessary for the patients, and the patient outcome was positive. Compared to some other European countries where procedures are reimbursed on a fee-for-service basis, like lead extraction for example, we have a lower procedure volume. For additional*

*procedures over budget, we discuss patient benefit with the administration before proceeding. What is more important: performing device implantations or lead extractions?*

*Sweden is divided into 21 counties; each county has a different budget. In Skane county, we are evolving slowly towards performing more and more complex procedures in centralized departments. We have grants for lead extraction, and ablation to treat patients primarily from Skane county, but patients come from anywhere in Sweden. In addition, my department is specialized in children's heart diseases and Grown-Up Congenital Heart*

*disease (GUCH), for which we receive specific subventions. These subventions also cover lead extraction, which is relatively expensive. We are growing as a center of excellence for children's heart care therapy and GUCH. We are one of the largest centers in Sweden for these four patient groups. This allows us to apply for increased budgets to improve patient care.*

**What type of imaging lab do you use in Lund arrhythmia department and how do you triage the procedures among these rooms?**

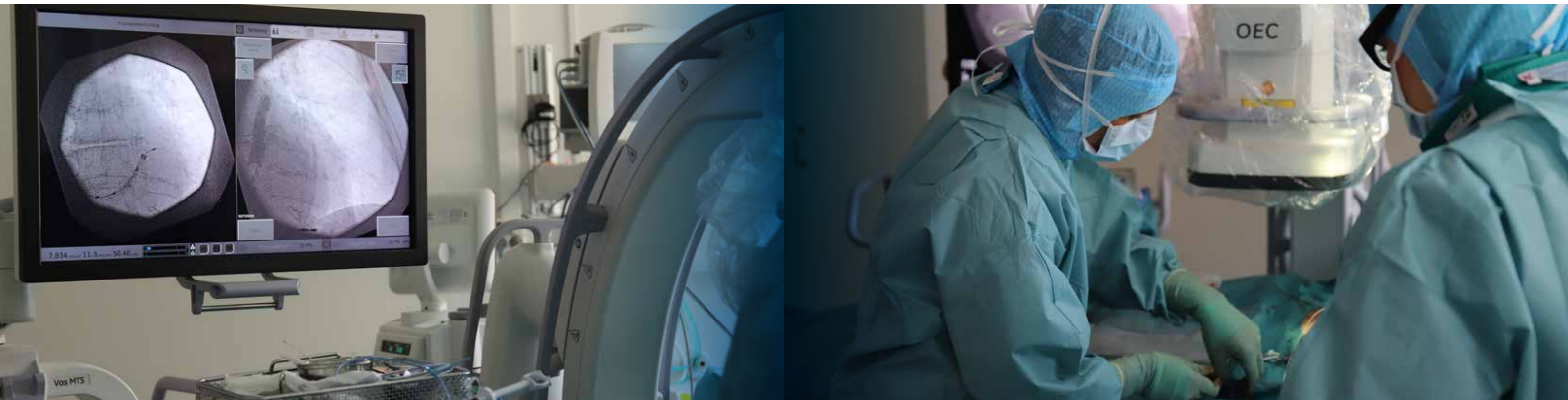*In the arrhythmia clinic we have two cathlabs where we primarily do ablation procedures. The complex heart rhythm treatments are performed in one of the cathlabs with two physicians, where we can use the Niobe (Stereotaxis, Saint Louis, MO USA) magnetically-driven robotic system. The department is a reference center for Stereotaxis. The other cathlab is equipped with a fixed angiography room setup for manual ablation and both labs are equipped with 3D mapping system CARTO® (Biosense Webster). In addition to the two fixed angio rooms, we built an additional room dedicated to device*

*surgery with the OEC Elite CFD Ergo C-arm (GE Healthcare) and an imagiQ2™ surgery table (Stille). We have one shared hybrid room in the surgery department that I can use for some procedures twice a week. We also have access to the children's surgery department on demand (approximately once a week), that is also equipped with a C-arm. We are one of the two reference centers for children's heart surgery and arrhythmia treatment in Sweden, together with Sahlgrenska University hospital.*

**What are the most demanding procedures in terms of fluoroscopy?**

*I think that lead extraction is the most demanding procedure for fluoroscopy. We need to see the lead extraction tool, i.e., a special sheath, and position it in a controlled manner over the lead to break the fibrous tissue that makes the lead adhere to the vessels and heart muscle. Fluoroscopy imaging is used to make sure that the sheath is aligned with the lead. If the sheath deviates from the lead, we can damage it, or even break it. This procedure can be long.*

...



We perform standard extractions on the OEC Elite CFD C-arm when the lead has been in place for only a few years and calcified fibrous tissue has not had time to develop over the lead and where the lead design is standard and not fractured. The most complex extractions are performed in the fixed hybrid room. We routinely perform this procedure under general anesthesia in the hybrid operating room in case we need to do an emergency sternotomy, as we are unable to do this down here in the EP Lab.

Balloon cryoablation is a standard procedure performed at Skane university Hospital - Lund as a primary

intervention to treat atrial fibrillation. This procedure is performed using fluoroscopy alone to guide the catheter containing the balloon, to inflate the balloon, and check that we have a good occlusion of the pulmonary veins by the balloon before introducing the refrigerant liquid into the balloon and proceeding with the creation of scars in the heart tissue. For this procedure, there is no need for image fusion. The CT scanner is used to confirm the anatomy of the patient, checking that there are 4 separate pulmonary veins. We can then merge the CT images in the CARTO® mapping system, to create a 3D model of the heart chambers.

Some centers perform cryoablation using a very simple set up, with a C-arm and the ablation system. To be able to perform ablation, you need a high-quality left anterior oblique projection to do the trans-septal puncture. However, once you are in the left atrium, you can simply navigate with an AP projection and the electrical signal from a mapping catheter. In routine ablation cases, it is possible to perform ablation without fluoroscopy, as we know where we are in the heart just by looking at the ElectroCardioGram (ECG) signals.

Typically, if you have a standard case, you need just a few seconds of fluoroscopy to verify that the catheters

are in the heart, and in the position where you need to have them, and maybe you will need to perform fluoroscopy for another few seconds to check where your ablation catheter is. Thus, many procedures only have between 20 to 60 seconds of fluoroscopy time, and we can rely on 3D electroanatomical mapping systems and minimize fluoro, even if the procedure itself may be 2 hours or more. But, if our 3D mapping fails, we need to rely on fluoroscopy. For pacemaker implants, we use fluoroscopy to guide and position the leads. This is the main activity in this mobile room in the device surgery lab.


**Why did you choose the OEC Elite CFD Ergo C-arm for your activity?**

I am the referent for the choice of the C-arm in the clinic, but as it is a major investment, the decision is taken by the team within the heart-lung center.

The main criteria we examine when choosing a C-arm are: ease of use, well-designed and intuitive interface, and image quality/dose. It is important for me to try to limit my X-ray dose without compromising image quality, especially as some procedures take more fluoroscopy time. We are always screening in low-dose fluoroscopy mode, just increasing the dose with a Cine loop for the final check. Because

the OEC C-arm is easy to move, I can easily change the projection during the procedure, and optimize my exposure time thus minimizing the overall dose.

The image quality of the OEC Elite CFD C-arm is really good. I can clearly see the border of the heart as well as my leads and guidewires, and I have good visualization of the motion of the tip of the leads. The OEC Elite CFD C-arm performs well on low dose and IQ, and is easy to use, which are the two most important criteria. □



**Dr. David Mörtzell**  
Director of device surgery  
and arrhythmology unit,  
Skane University Hospital,  
Lund, (Sweden)

### Dr Mörtzell - how did you train to become an arrhythmia specialist?

I started as a general medicine and emergency room physician and specialized in cardiology in 2006. As I had a preference for arrhythmology within cardiology, I completed my training during a fellowship at the EP lab at Royal Brompton Hospital (London, UK). On my return to Sweden I decided to specialize in invasive arrhythmology. So I moved from interventional cardiology to invasive arrhythmology. Since then I perform only electrophysiology procedures and device surgery with a split in my activity of about 50% EP ablation and 50% device surgery.

### How do you manage the quality of care within your arrhythmia department?

As director of arrhythmia devices, I define what procedures we are going to do, how we are going to do them, and we report the number of procedures with their associated cost. I define the routines, how we do the

procedures, and I define the training courses for the staff and other physicians. We work in collaboration with device companies for training courses and I am responsible for the relations with them. In addition to managing the patient workflow, I am also responsible for ensuring that we work within our quality charter requirements, optimizing for example X-ray exposure time and fluoroscopy protocols. But I also work 100% as a clinician as well. On a national level, we contribute with research projects, such as the multicentric evaluation of new cryoballoon ablation techniques<sup>1</sup>.

### How do you foresee the evolution of device and arrhythmology procedures in the future?

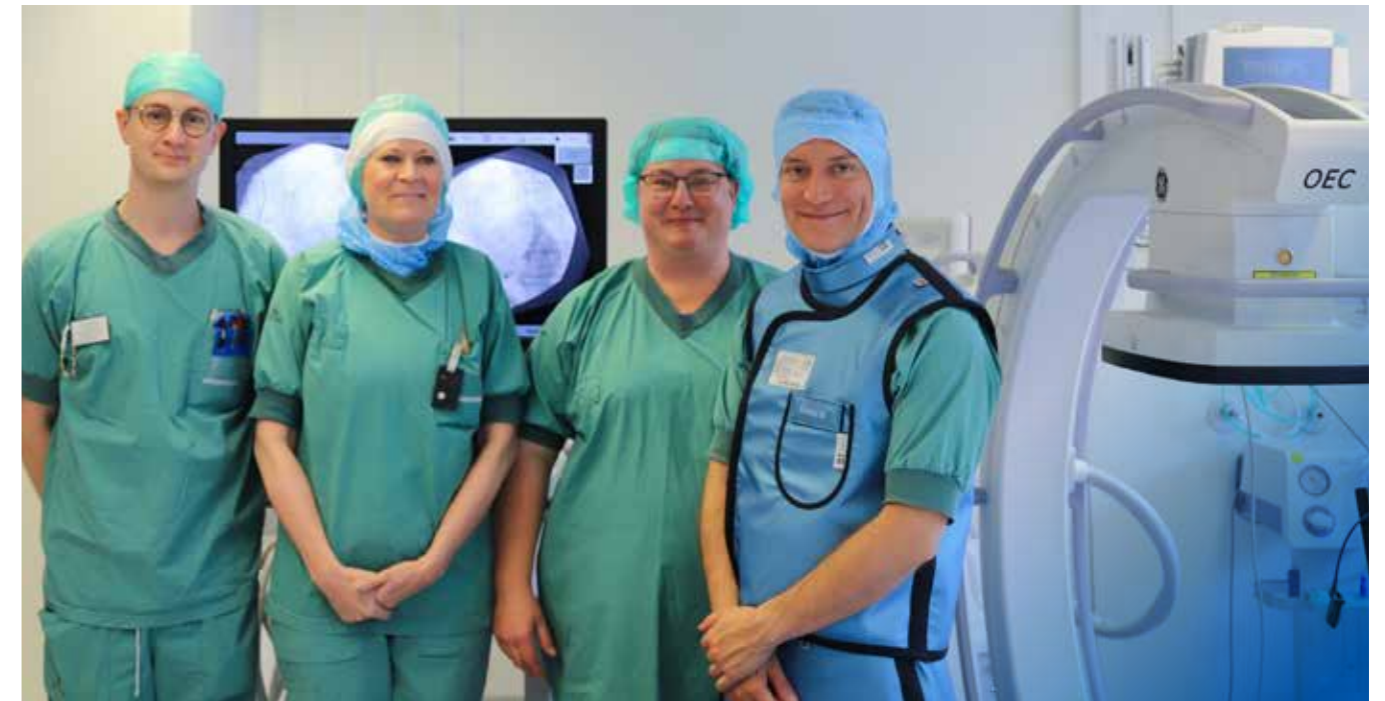The trend for arrhythmia procedures is to move towards leadless devices through percutaneous access. If you are asking me where we will be in 5 years, I would say that subcutaneous ICDs will be the largest portion of ICD procedures. This type of device implantation does not require

fluoroscopic imaging guidance. We just need to perform a quick final control image to check the positioning of the device, that is located under the muscle, and the position of the defibrillator lead connected to the device, that is placed under the skin, over the ribs, and over the sternum, creating a defibrillation field. The implantation of leadless pacemakers will also become widespread. This device, which is no larger than a big vitamin pill, is brought directly into the right ventricle via the inferior cava vein using a delivery system through femoral vein access. The device is anchored directly to the heart tissue. The implantation procedure duration is shortened as there are no leads to be placed inside the heart. For this procedure, fluoroscopy is used to guide and position the device.

Today, radiation exposure is a concern for young doctors. They are training with mapping systems, navigation systems, 3D models, and when something happens and they do not have these tools available, but just fluoroscopy imaging, they are lost, they don't know how to read the image. Teaching them how they can perform simple procedures using fluoroscopy alone, and only one catheter, relying on ECG signals is an important part of training. It is important to be able to manage our procedure with minimalistic equipment and effective fluoroscopic imaging while at the same time, learning how to use more sophisticated mapping tools. □

<sup>1</sup> "Cryoballoon vs. radiofrequency ablation for atrial fibrillation: a study of outcome and safety based on the ESC-EHRA atrial fibrillation ablation long-term registry and the Swedish catheter ablation registry". Mörtzell D et al. Europace. 2019 Apr 1;21(4):581-589.

The statements by GE's customers described here are based on their own opinions and on results that were achieved in the customer's unique setting. Since there is no "typical" hospital and many variables exist, i.e. hospital size, case mix, etc., there can be no guarantee that other customers will achieve the same results.



Jakob Aronson (Nurse), Kerstin Sjögren (Operations Nurse), Maria Eltén (Assistant nurse) and Dr. David Mörtzell

## The arrhythmology unit is a sub-division of the hospital's heart-lung center.

The center comprises the cardiology department, itself divided into 3 subsections: ischemia (including Percutaneous Coronary Interventions), structural heart interventions and heart failure, and the arrhythmia clinic.

The EP activity of Skane University Hospital is split between two departments, one located in Malmö and one located in Lund. In Malmö regular pacemakers are implanted in up to 600 patients per year.

Lund's EP department has been developing its activity in more advanced procedures, training the staff to perform the programming of the devices itself. The department is equipped with a remote electronic heart-monitoring system where the data saved on the device is transmitted to the clinic through a transmitter in

the patient's home. Regular reports are sent to the clinic so the medical staff can check the diagnostic data, modify the programming of the device if needed, and feed the database. This electronic system allows us to increase patient safety while saving costs and time to concentrate the medical staff on patients with the greatest needs<sup>1</sup>. The volume of procedures is about 700 ablations, 400 Implantable Cardioverter Defibrillators (ICDs), 300 CRTs, 500 pacemakers, 100 lead extractions, and a number of congenital treatments per year. For ICD and pacemaker activities, patients are mainly recruited in the county of Skane. For pediatric care, complex CRT, lead extraction, and ablation in GUCH, patients come to the ward from the entire country.

<sup>1</sup> <http://skanecare.com/care-projects/>

# Complete Atrioventricular (AV) block treatment with Cardiac Resynchronization Therapy (CRT) device implant using the OEC Elite CFD Ergo C-arm

Courtesy of Dr. David Mörtzell, Director of device surgery and arrhythmia clinic, Skane University Hospital, Lund (Sweden)

OEC Elite CFD Ergo C 21 cm, VAS MTS

## Clinical Challenge

CRT device implantation (or biventricular pacing) is a common treatment for cardiac arrhythmia. The procedure involves implanting a pacemaker under the skin below the collarbone, connecting the pacemaker to three leads: one inside the right atrium, one inside the right ventricle, and the third one inside the coronary sinus vein at the level of the left ventricle of the heart.

The leads are brought to the heart through venous access, from the subclavian vein to the superior vena cava. Fluoroscopy is used to guide the different leads to their final anchorage location.

While the guidance of the leads in the right atrium and right ventricle is quite straightforward, the cannulation of the coronary sinus can be more complex. In addition, the third lead needs to be guided to the great cardiac vein, and placed into one of

its bifurcations using a 0.014" guidewire.

As the procedure can be long and is performed under fluoroscopy guidance, with demanding image quality, radiation exposure must be managed during the procedure, optimizing each step.

## Solution

The procedure was performed with assistance of X-ray imaging from OEC Elite CFD Ergo C. To control the exposure, the fluoroscopic guidance of the leads was set to standard pulse mode at 15 pps. Coronary sinus venogram was performed in Digital Cine 15 pps mode. The anatomic profile was set to General HD to navigate 0.014" guidewires.

## Clinical example

An 80-year-old female patient with a history of chronic heart failure presented with a left bundle branch block. She was

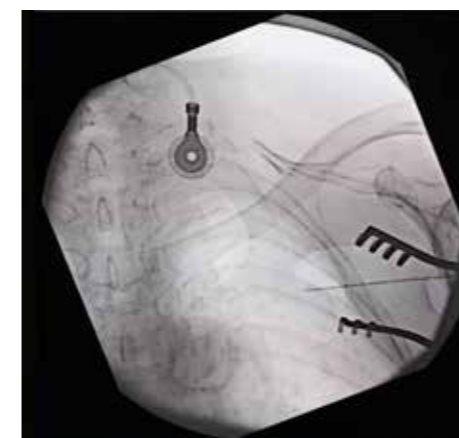
treated 6 months earlier for pulmonary edema and received optimal pharmacological treatment but remained highly symptomatic and left ventricular function stayed poor. The patient was thus eligible for a CRT device implantation.

This procedure was performed under local anesthesia, under ambulatory conditions.

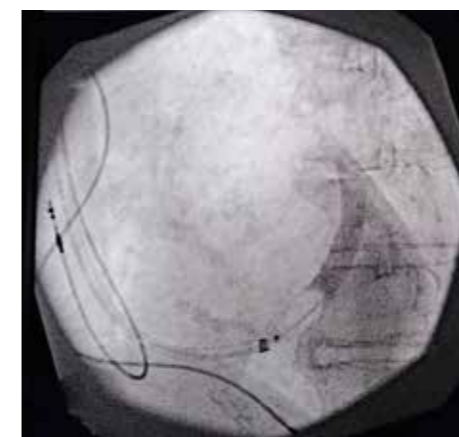
Venous access was obtained by axillary vein puncture. Catheterization and subsequent venogram of the coronary sinus was performed injecting about 20 cc of iodine at 50% dilution.

The final verification of the lead was performed and compared to a post-op X-ray control image. The same information was found in both the fluoroscopy control and X-ray images.

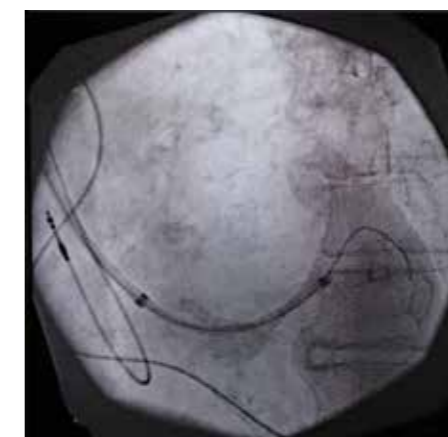
The total exposure time was 1 minute and 20 seconds, and the total DAP was 11.7 Gy cm<sup>2</sup>.



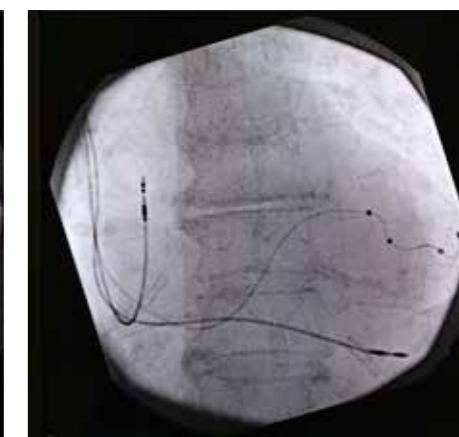
Puncture of axillary vein – Antero Posterior (AP) View.



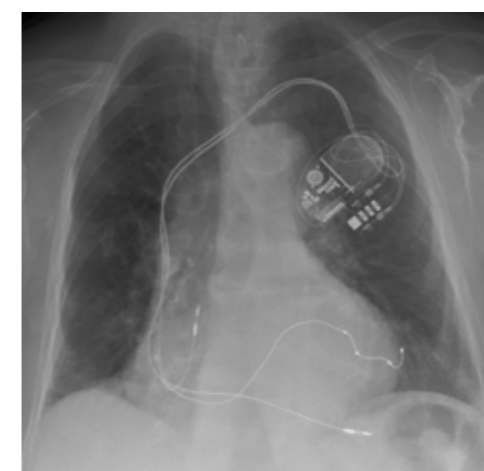
Coronary sinus injected with contrast media 30° Left Anterior Oblique (LAO).



Catheterization of coronary sinus – 30° LAO.



Final perioperative control of CRT leads in coronary sinus – AP view.



X-ray control post procedure AP view.

The statements by GE's customers described here are based on their own opinions and on results that were achieved in the customer's unique setting. Since there is no "typical" hospital and many variables exist, i.e. hospital size, case mix, etc., there can be no guarantee that other customers will achieve the same results.

# Pacing treatment with leadless device implant using the OEC Elite CFD Ergo C-arm

Courtesy of Dr. David Mörtzell, Director of device surgery and arrhythmia clinic, Skane University Hospital, Lund (Sweden)

OEC Elite CFD Ergo C 21 cm, VAS MTS.

## Clinical Challenge

Pacing devices are evolving towards systems without leads. The advantage of such devices is that they require no lead guidance and no surgical pocket under the skin. Potential complications associated with venous access (such as pneumothorax), lead dysfunction and local symptoms from the surgical pocket (such as hematoma or infection) are less likely. The device (Micra™ Transcatheter Pacing System – TPS Medtronic), which is no larger than a large vitamin pill, is brought directly into the right ventricle via the inferior vena cava using a delivery system through femoral vein access. The device is anchored directly to the heart tissue without external leads.

## Solution

The procedure was performed with assistance of X-ray imaging from OEC Elite CFD Ergo C. The guidance of the delivery sheath was achieved using continuous fluoroscopy. The verification of the anchorage of the device on the heart tissue was performed in Digital Cine 15 pps mode. The anatomic profile was set to General HD. In order to visualize the small anchor tines located at the extremity of the device and ensure that there is no

dislodgment, the magnification mode was used during live fluoro control.

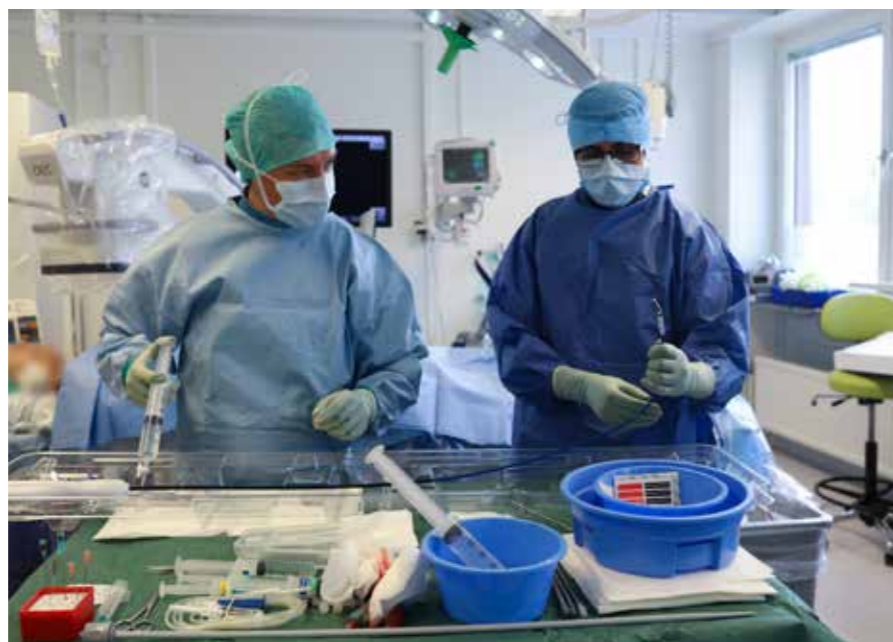## Clinical example

An 85-year-old female patient with a history of chronic atrial fibrillation and bradycardia was offered this treatment instead of a conventional pacemaker in ambulatory conditions. This device implant

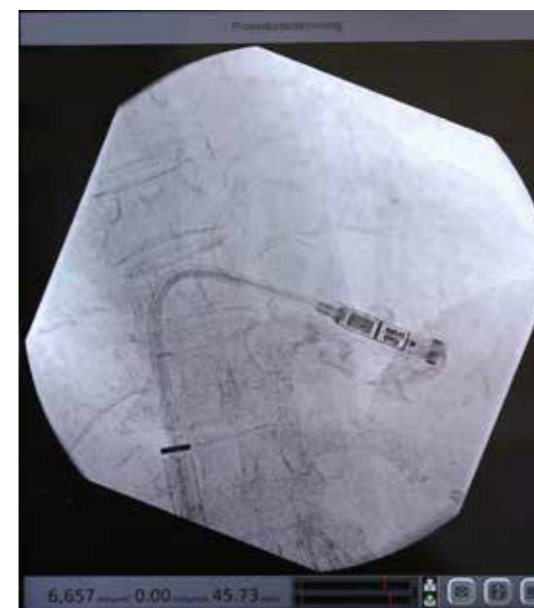placement requires only femoral vein access, and no other incisions during the procedure, potentially reducing post-op complications.

Femoral vein access was performed under local anesthesia.


The total exposure time was 1 minute and 53 seconds, and the total DAP was 6.6 Gy cm<sup>2</sup>.



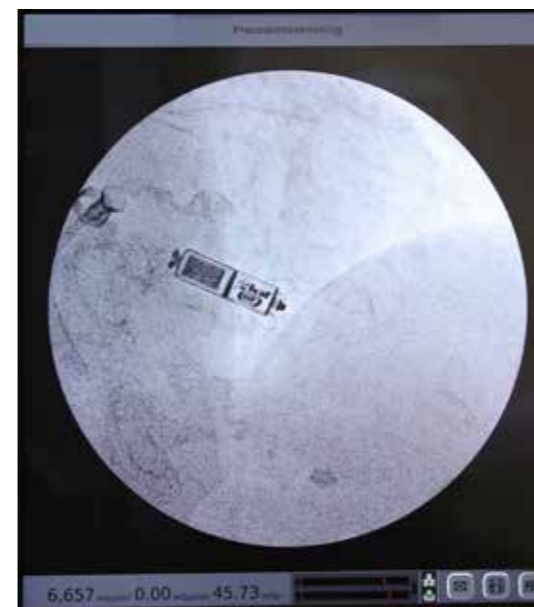
Preparation of the device delivery sheath.



Placement of the device next to heart tissues – AP view.



Release of the device from delivery system – AP view, Magnification 1.



Final verification of device implantation – 30° Right Anterior Oblique (RAO) view, Magnification 1.

The statements by GE's customers described here are based on their own opinions and on results that were achieved in the customer's unique setting. Since there is no "typical" hospital and many variables exist, i.e. hospital size, case mix, etc., there can be no guarantee that other customers will achieve the same results.

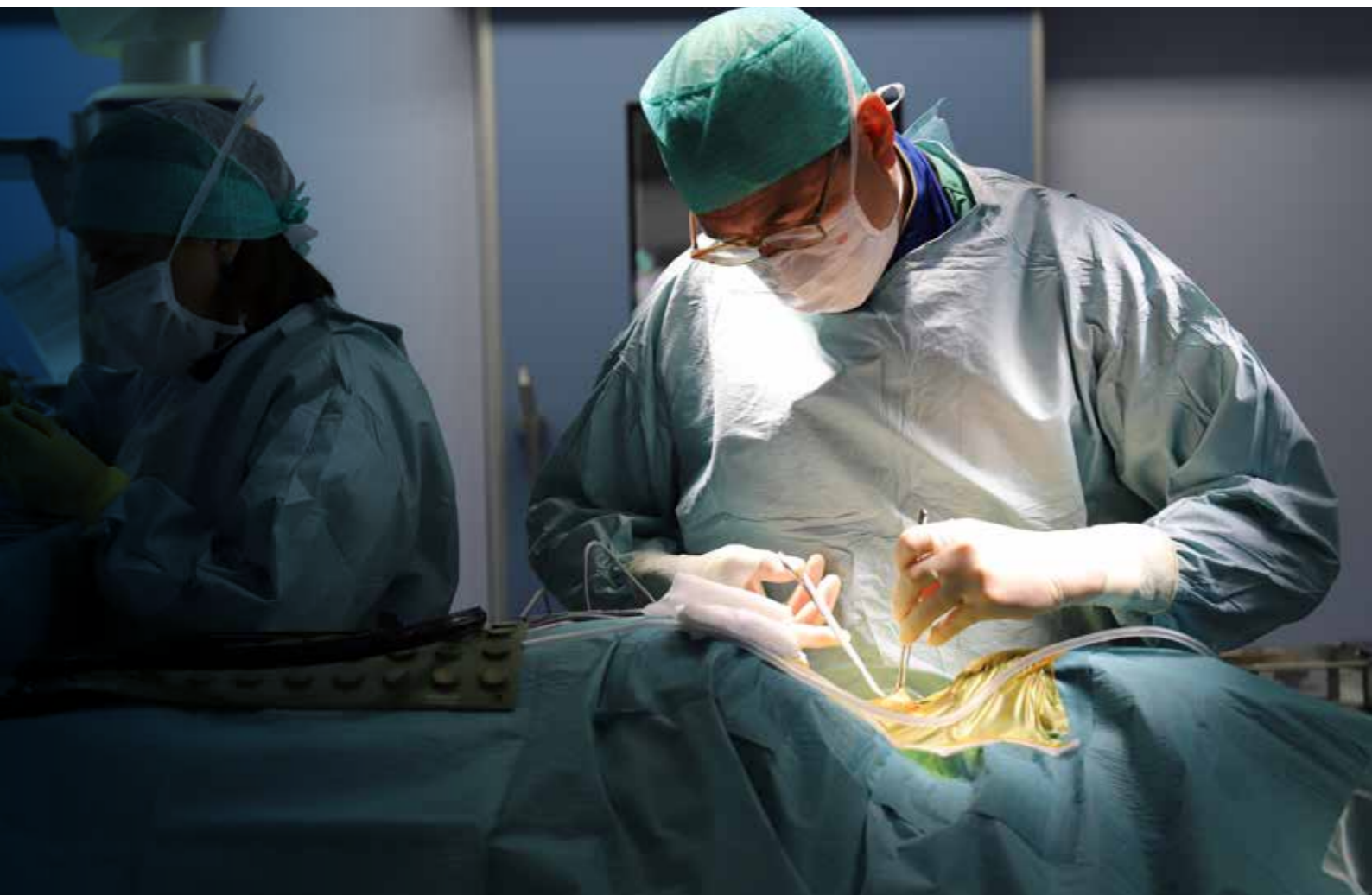# Spine procedures with OEC Elite CFD: efficient and reliable fluoroscopic imaging guidance

**Experience of Dr. Giovanni Alessi, Neurology department, AZ Sint-Lucas, Ghent (Belgium)**

Fifteen years ago, AZ Sint-Lucas was created through the merger of three separate hospitals in Ghent. Located in the city center, the hospital continues to grow with the renovation and construction of new buildings. Half of the patients at AZ Sint-Lucas are from Ghent, but its service area also covers the northwest of the province of East Flanders, extending north to the border with the Netherlands, and west to the province border with West Flanders.

The neurology department has five neurosurgeons, performing over 1000 procedures per year. Dr. Alessi was involved in the selection of the OEC Elite CFD C-arm Ergo C for the department. He explains why the image quality, maneuverability and intuitiveness of OEC Elite CFD is so important for neurosurgery.

azsint-lucas



**Can you tell us which neurology procedures require fluoroscopic guidance and control?**

We are using fluoroscopic imaging guidance and control in all our spine procedures: spinal arthrodesis (or spinal fusion), intervertebral prosthetic disc replacement, and spine fracture reduction (including kyphoplasty and vertebroplasty). For intracranial procedures, we no longer use fluoroscopy, but rather a navigation system.

Among all the spine surgery procedures, the highest volume is represented by the arthrodesis procedure at thoraco-lumbar and cervical levels. I myself perform about 400 arthrodesis procedures a year, and I would say about 50% of these are thoraco-lumbar and 50% are cervical.

When we do Minimally Invasive Surgery (MIS) or percutaneous arthrodesis, we need fluoroscopic images to define the entry point and the direction of the tools. At each step

of the procedure, we need to know where the instrument is. To do so, we perform dual fluoroscopy with two C-arms: one acquires the Antero Posterior (AP) view and the other one the Lateral view and one Lateral view of the vertebral pedicle, to see the direction of the tool and its depth, and also how to progress the screw in the pedicle bone.

Even during minimally invasive surgery of a herniated intervertebral disc for which I work with the

microscope, I take some fluoroscopic images at the beginning of the procedure to define the level of the disc where I need to perform the incision. To do this, I place a needle under fluoroscopic imaging and confirm its position with one AP and one Lateral projection, which I display simultaneously on the video monitors. From these two views I can mentally rebuild the volume of the anatomy. Then I remove the C-arm and complete the procedure with the microscope. In fact, there are no spinal surgery procedures for which I do not use fluoroscopy for at least a few seconds. I know that some centers don't use fluoroscopic imaging, but at AZ Sint-Lucas we use this protocol all the time as part of our quality charter to ensure a better surgery outcome for the patient.

**What are your main motivations choosing the OEC Elite CFD C-arm Ergo C for your neurology procedures?**

The most important criteria for me is the image quality. For a surgeon, the more we see, the higher the quality of the procedure outcome. A surgeon performs better when he sees better. In spinal surgery, there are many instruments that we know will not improve the surgery, even if enhanced. What does improve the quality of the surgery is a good microscope and a good fluoroscopy imaging system. While doing percutaneous arthrodesis, I have no visual control, and I rely on fluoroscopic imaging to see the volume of the vertebrae. I am looking for the delimitation of the bone contour. The most difficult vertebrae to visualize is S1 because of its inclination. To see the cortical bone of the pedicle, we need to apply a craniocaudal angulation to get a true AP view of the vertebra,

compensating for the lordosis. Sometimes, even with a craniocaudal angulation, the pedicles are not clear. If the image is of inferior quality, we feel less comfortable performing the intervention.

My criterion for image quality definition is the ability of a C-arm to provide a good image of S1. Image quality is my first requirement when choosing fluoroscopic imaging equipment.

I love the General HD profile, which gives me an image that is crisp and crystal clear. It really is a great image. In addition, when using the Live Zoom, I can enhance small anatomies and get more details. I better see the contour of the pedicles.

**How should C-arms evolve to better support the evolution of the surgical procedures in neurology?**

For me the ideal C-arm of the future is a system with less X-ray radiation, combined with navigation. I would like to take one image at the beginning of the procedure and then navigate on this image for the rest of the procedure. Of course, I need very high accuracy in the position of the surgical tools, this is the sine qua non for using navigation.

If we consider the different tools to better visualize the volume of the anatomy, the 3D feature allows, at each moment of the procedure, to see where we stand on the 3 coronal, sagittal, and axial planes. While there are imaging systems available that provide 3D multi-planar views, the technology is currently too, and I am not convinced that it improves the outcome compared to what I am doing today.

It would reassure me about the location of the screws inside the

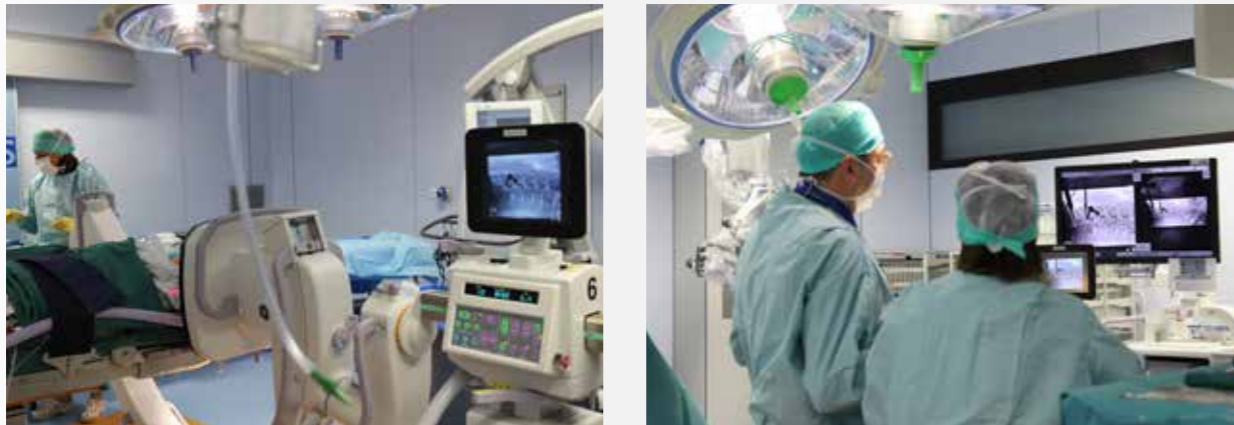pedicles as a final control, but I have been doing percutaneous arthrodesis for 15 years and I haven't misplaced a screw in a pedicle.

I am more interested in features that improve my surgical outcomes. Image quality is essential to me, I can operate better when I see better.

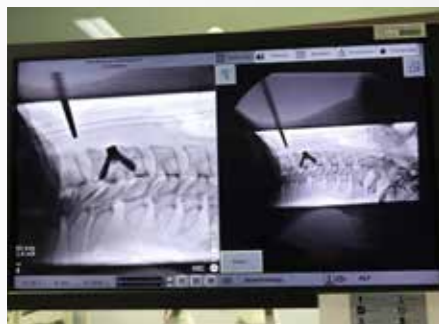The ease with which images can be acquired is also important and this helps increase the speed or the rate at which I can take images. When we work with a percutaneous approach, we turn the C-arm AP to Lateral multiple times, and we create our 3D representation of the spine mentally from these two projections. If I can speed up the workflow using a motorized C-arm like the one used by vascular surgeons for angiographies, it could contribute improving my surgery outcomes. In this spirit, I tested the motorized version of OEC Elite CFD and I believe that it brings a real added value for spine surgery. I can see the angle value and have it memorized by the system, I can recall the angulations myself from the table rails and have the C-arm move fast from AP to lateral. Without motorization we lose time trying to recall the angulation and find the right angle when coming back to AP from Lateral. This is why, when I work without motorization, I use two C-arms: one to capture the AP view, the other one to get the Lateral view of the vertebra, so I can keep the C-arm at the same angle to avoid the stress of remembering what craniocaudal and orbital angles I used. It is a good compromise using the tools I have available to do my surgery. I believe I could better manage the radiation dose with a motorized C-arm.

# Anterior Cervical Discectomy and Fusion (ACDF) on C6-C7

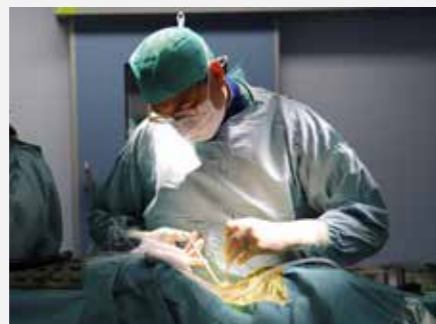Courtesy of Dr. Giovanni Alessi, Neurosurgeon, AZ Sint-Lucas in Ghent (Belgium)



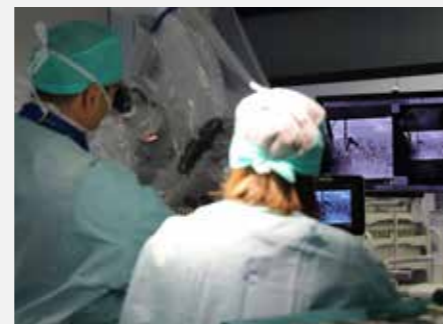On a 62-year-old female patient with a history of degenerative disc disease and previous C5-C6 ACDF. The C-arm is placed perpendicularly to the patient table to get a lateral view of the neck. The angulation is maintained during the full procedure. Anatomical profile is set to Spine. The live zoom is set to 2.2. Fluoroscopy mode is standard continuous.



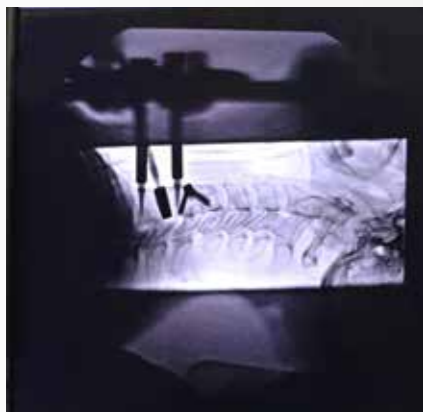Definition of the incision level with a lateral view



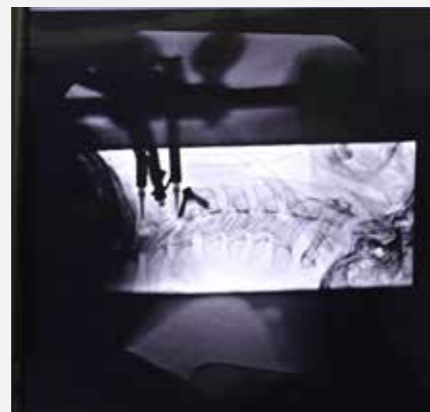The C-arm is parked to proceed to incision



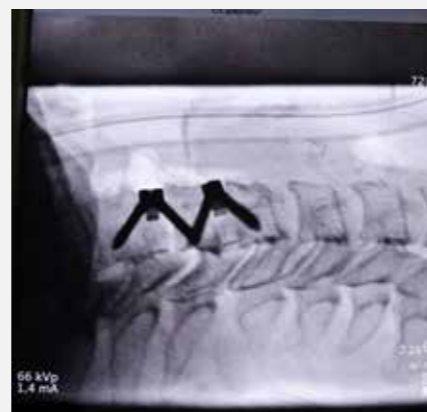The C-arm is brought back to the sterile field. Discectomy is performed under microscope and fluoroscopy control.



Cage gauge control to define the size



Introduction of the definitive cage

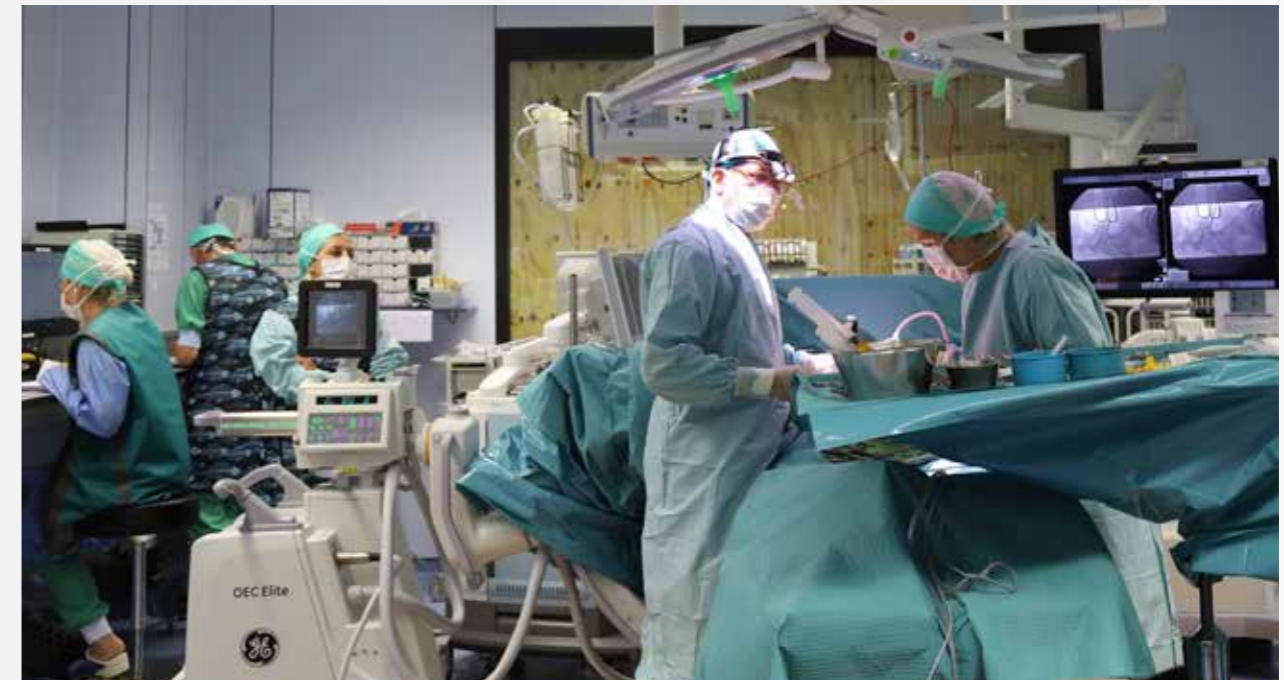

Final control of cage and screw placement

A total of 33 series of images have been taken, the total exposure time was 1 minute and 2 seconds, and the total DAP was 0.7 Gy.cm<sup>2</sup>.

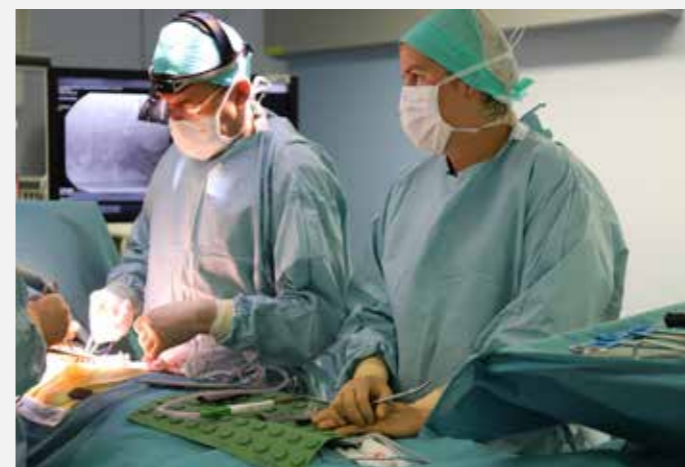# L5-S1 fusion by Retroperitoneal (Anterolateral) Approach

Courtesy of Dr. Giovanni Alessi, Neurosurgeon, AZ Sint-Lucas in Ghent (Belgium)

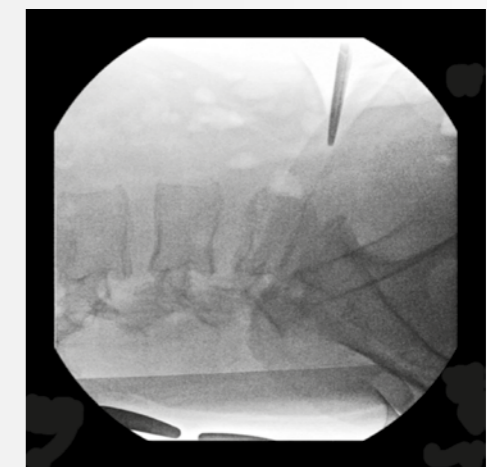


On a 40-year-old male patient. The patient is placed in a supine position. The Retroperitoneal approach requires retraction from the peritoneal cavity medially, and mobilization of the aorta on the contralateral side in order to reach the disc to be treated.

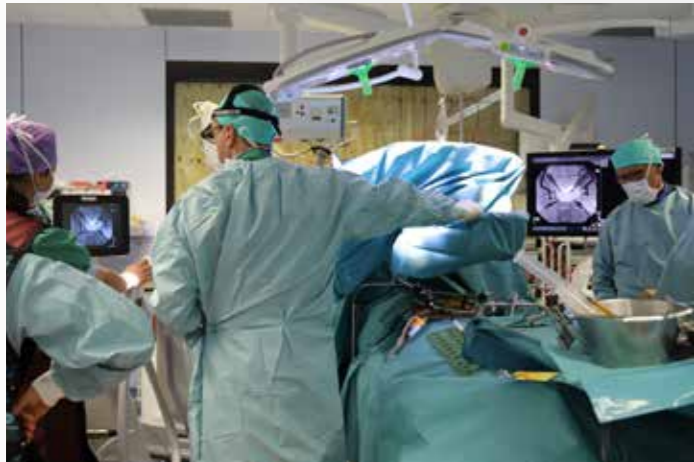The C-arm is positioned at S1 level, switching angulation from 0° (AP view) to 90° (lateral view) at different steps of the procedure. The anatomical profile is set to Spine. Fluoroscopy mode is standard continuous.



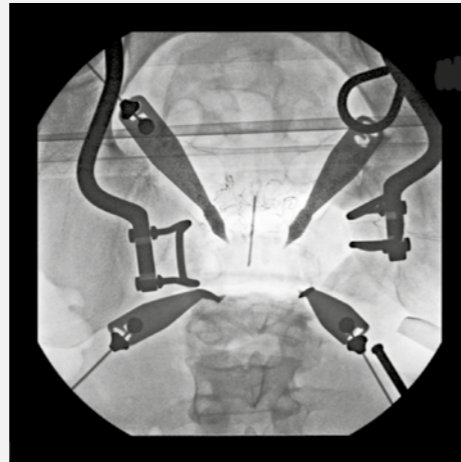
Extraction of bone sample from patient's iliac crest. Bone sample will be placed inside the cage as osteogenic material.



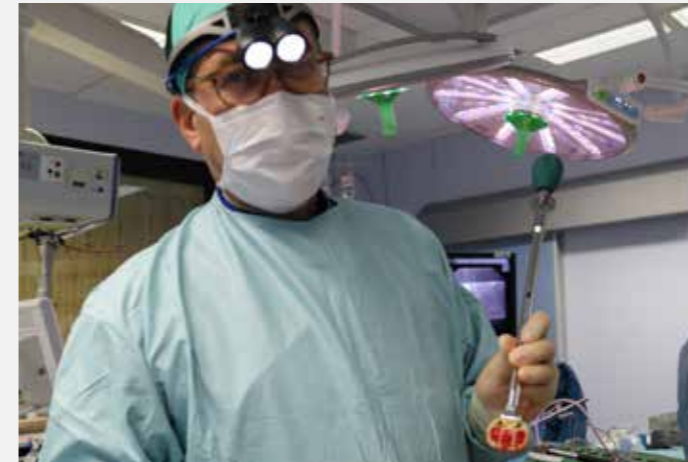Lateral view of ilium incision



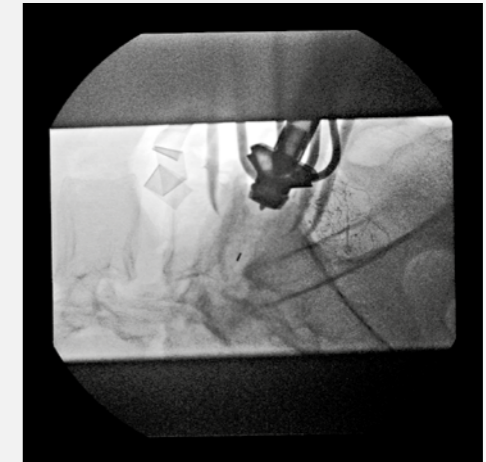
After stabilization of the peritoneal approach, a needle is placed at the center of the vertebral body to materialize the median line to help position the implant in the center of the intervertebral disc space.



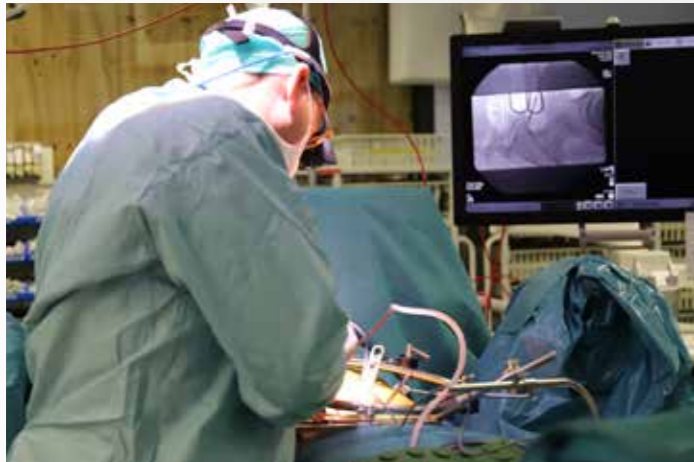AP view of L5 with needle materializing vertebra median line (between the two pedicles)



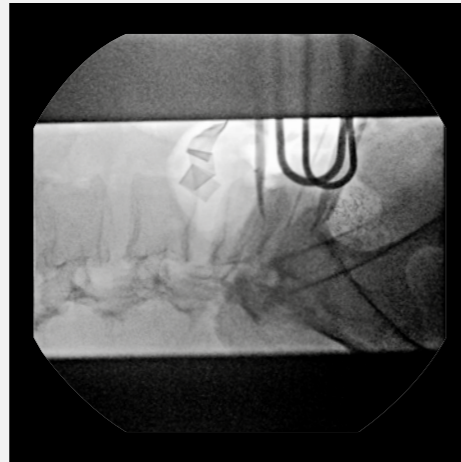
The cage is filled with patient's bone sample



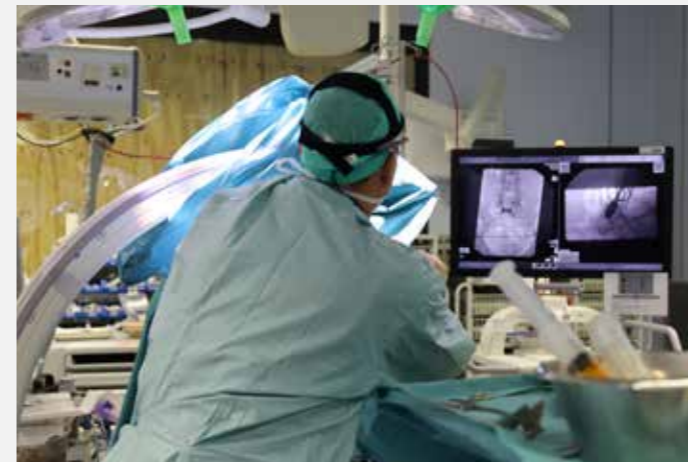Lateral view of the cage placed in L5-S1 intervertebral space



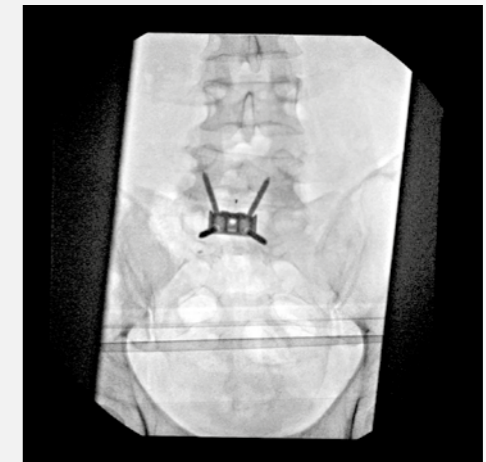S1-L5 discectomy under fluoroscopy guidance



Lateral view of discectomy

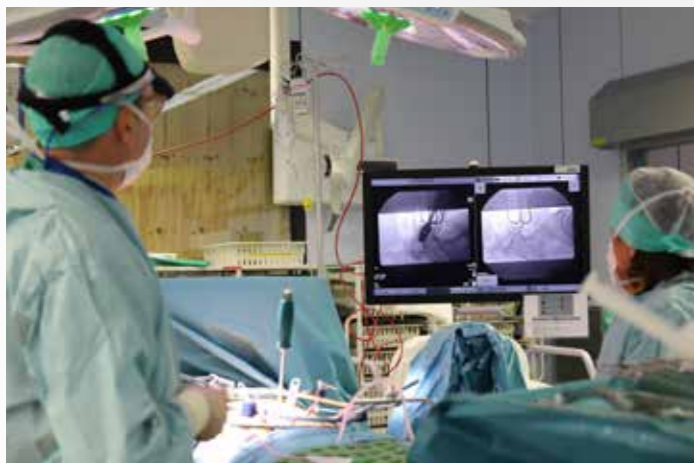

Placement of cage's screws and closure

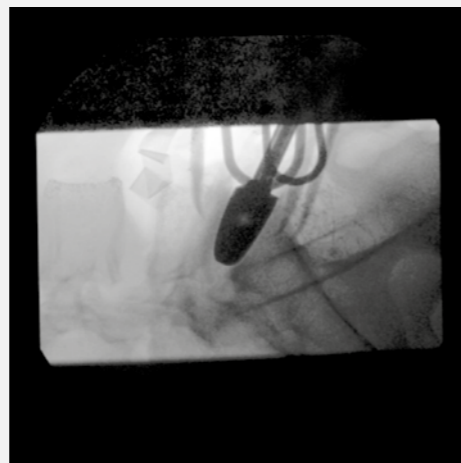


Final control of cage L5-S1 placement. AP view

A total of 38 series of images were taken with a total exposure time of 1 minute, and the total DAP was 7 Gy.cm<sup>2</sup>.



Evaluation of the cage size with the gauge



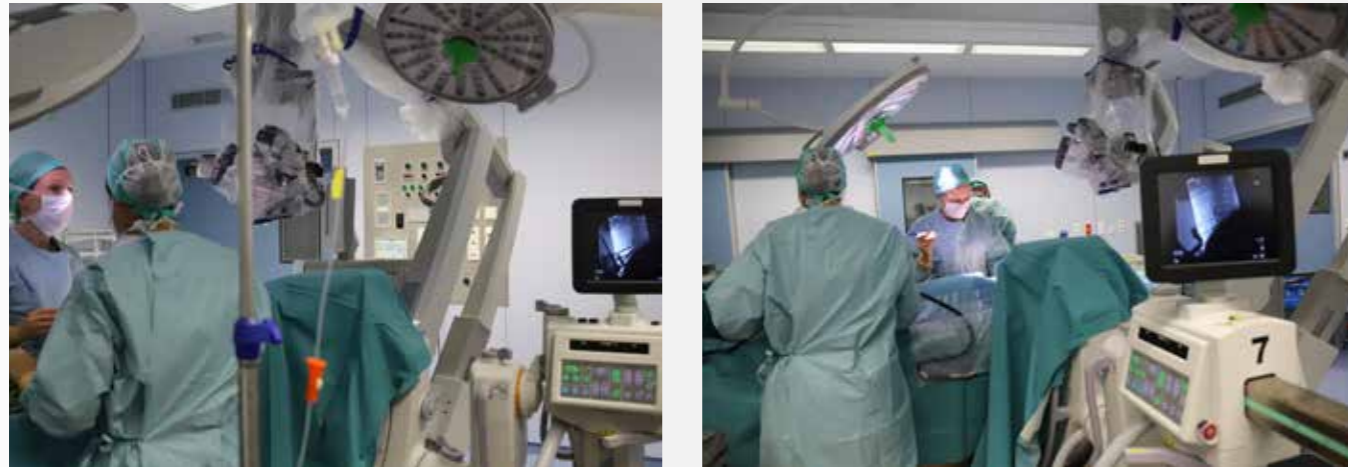Lateral view of the gauge in L5-S1 intervertebral space



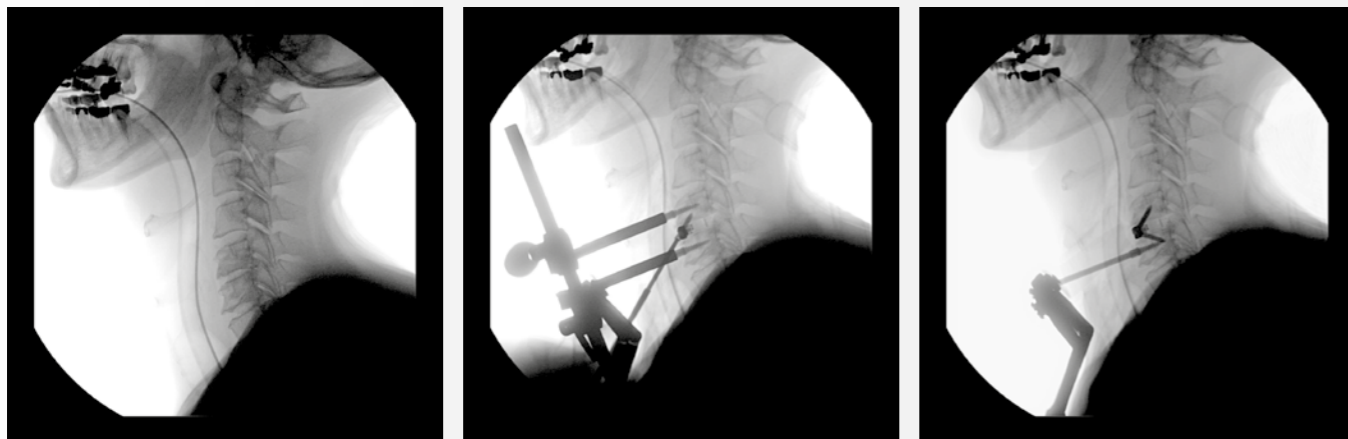**Dr. Giovanni Alessi** is a neurosurgeon and has worked for 17 years at AZ Sint Elizabeth, Zottegem and AZ Sint-Lucas, Ghent. He specializes in complex spine surgery, endoscopic pituitary surgery and posterior fossa surgery. He has a specific interest in anterior spine surgery and the minimally-invasive (percutaneous) spine approach.

# Anterior Cervical Discectomy and Fusion (ACDF) on C5-C6 and C6-C7

Courtesy of Dr. Kristel Vanchaze, Neurosurgeon, AZ Sint-Lucas in Ghent (Belgium)



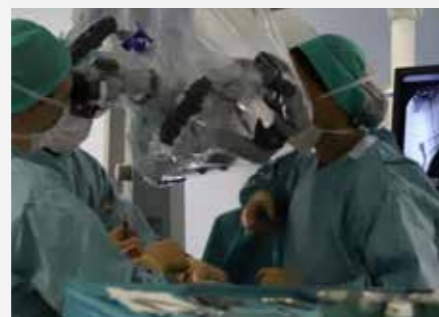The patient is a 48-year-old male. He is placed in a supine position. The C-arm is placed perpendicularly to the patient table to get a lateral view of the neck, excluding the shoulders. The angulation is maintained during the entire procedure. The anatomical profile is set to Spine. Fluoroscopy mode is standard continuous. C5-C6 discectomy and fusion.



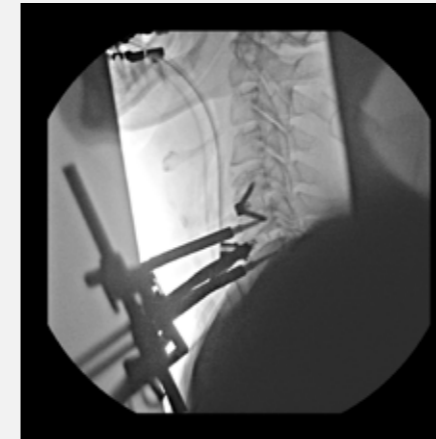Lateral view of C5-C6 and C6-C7 disc compression

C5-C6 cage in place, first screw insertion

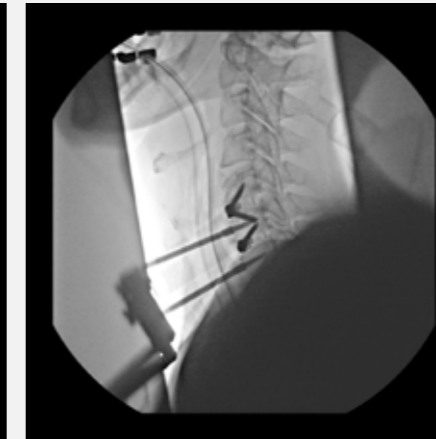
Final control of C5-C6 cage in place, with its two screws in position



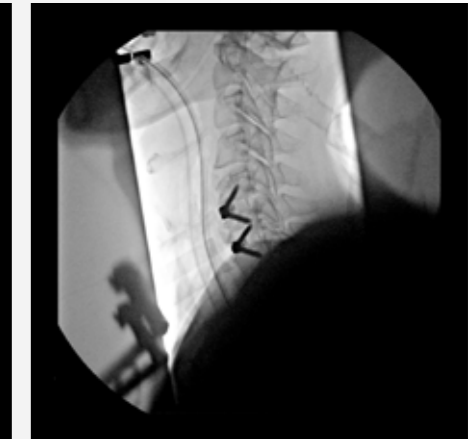C6-C7 discectomy is performed using a microscope



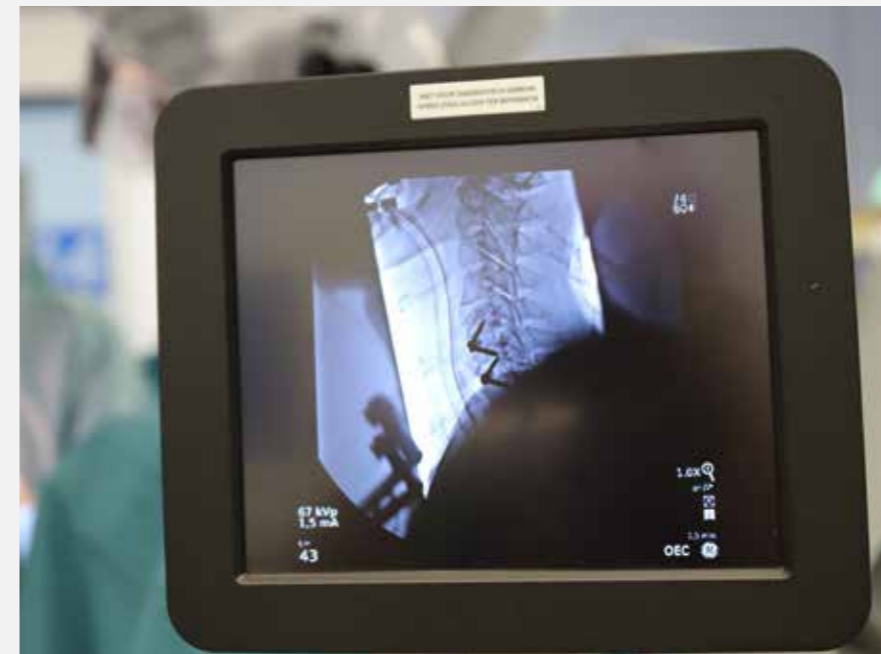C6-C7 cage placement



C6-C7 cage fixation with first screw



C6-C7 cage fixation with second screw



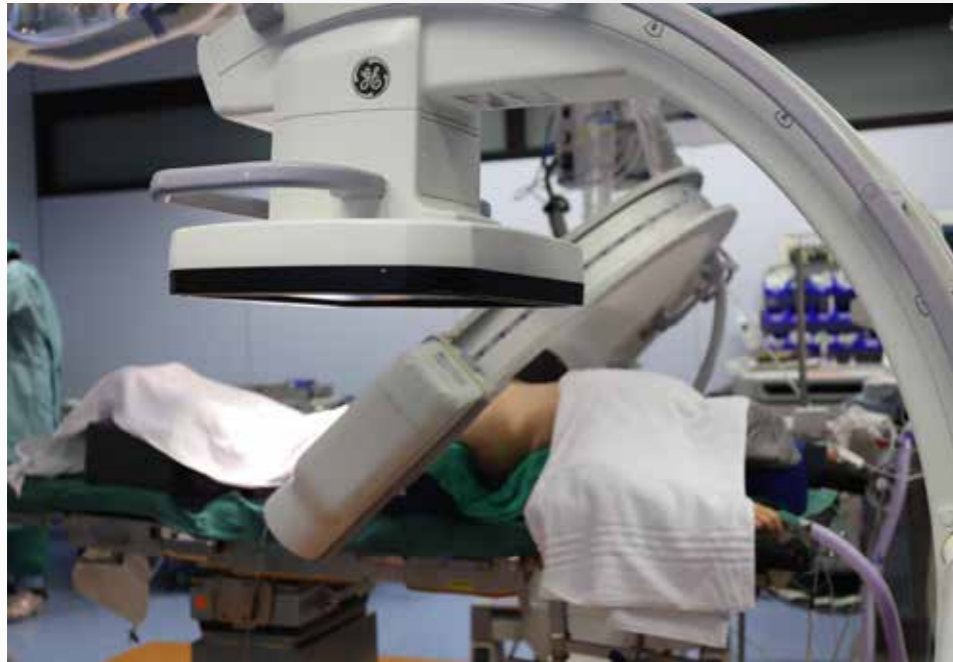A total of 43 series of images were taken with a total exposure time of 1 minute and 5 seconds and the total DAP was 2 Gy.cm<sup>2</sup>.



**Dr. Kristel Vanchaze** is a neurosurgeon working at AZ Sint-Lucas in Ghent and AZ Alma in Eeklo since 2016. She acts as head of department at AZ Alma in Eeklo. She focuses specifically on basic skull surgery, vascular neurosurgery, minimally-invasive spinal surgery, and peripheral nerve surgery.

# Posterior percutaneous arthrodesis L5-S1

Courtesy of Dr. David Colle, Neurosurgeon, AZ Sint-Lucas in Ghent (Belgium)



The patient is a 48-year-old female patient with a history of degenerative disc disease and previous L5-S1 retroperitoneal fusion.

The patient is placed in a prone position. The L5-S1 disc has been removed and replaced by a cage in a previous intervention.

For this procedure, two C-arms are used to capture the AP and Lateral views of the vertebra.

The OEC 9900 Elite C-arm is placed in the rainbow position to obtain the Lateral view, and the OEC Elite CFD Ergo C C-arm is placed vertically to obtain the AP view.

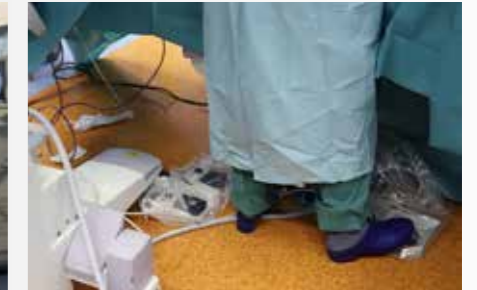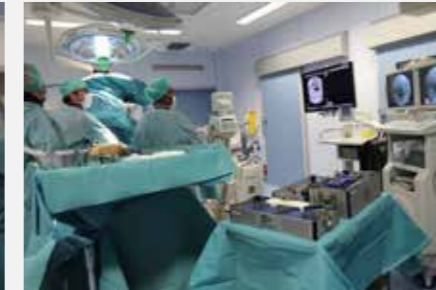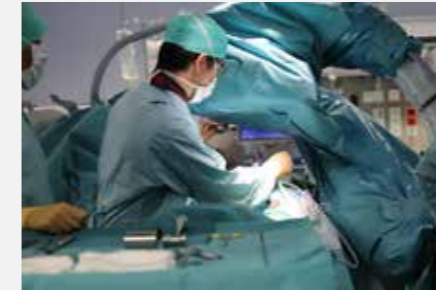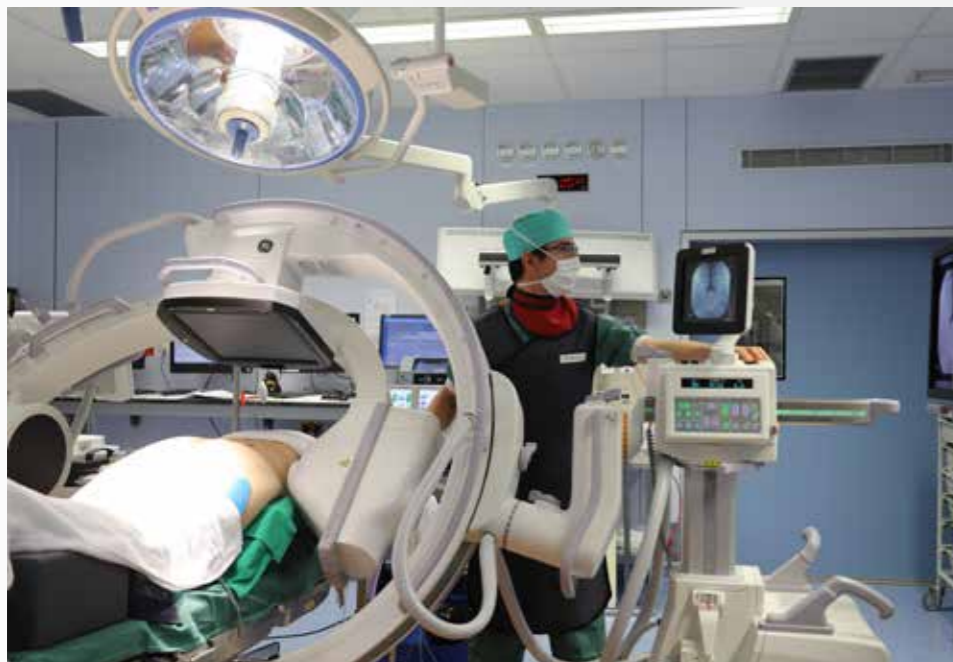Each C-arm angulation is maintained during the procedure, avoiding many manipulations from AP to Lateral and Lateral to AP views.

The anatomical profile is set to Spine, and Fluoroscopy mode is standard continuous.

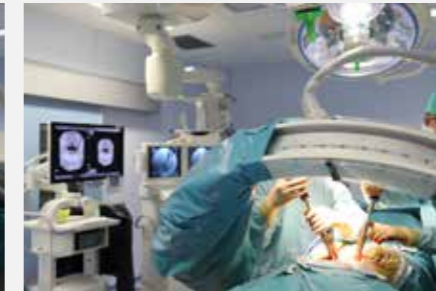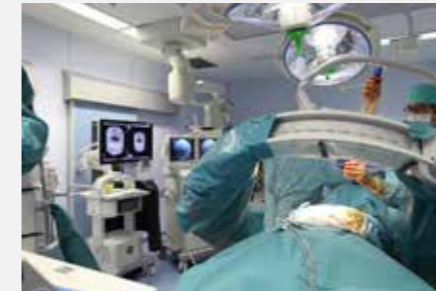Once the C-arms are angulated to obtain the correct projections, they are used to define the incision levels for the percutaneous approach on the patient's skin. The C-arms are covered with sterile drapes and positioned for the full procedure.

At each stage of the procedure the AP view gives an indication of the entry point of the tools, while the Lateral view gives information on the direction and the depth of the tools.

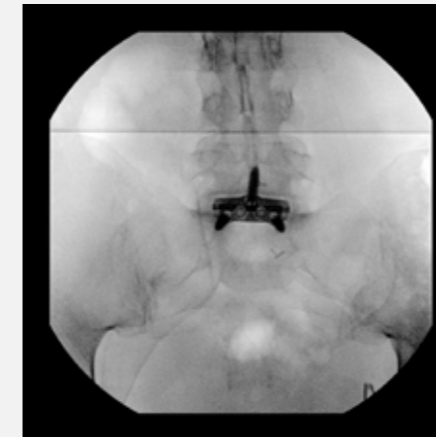
Looking at the two workstations, the practitioner can access to both views and mentally reconstruct the 3D volume of the vertebrae.



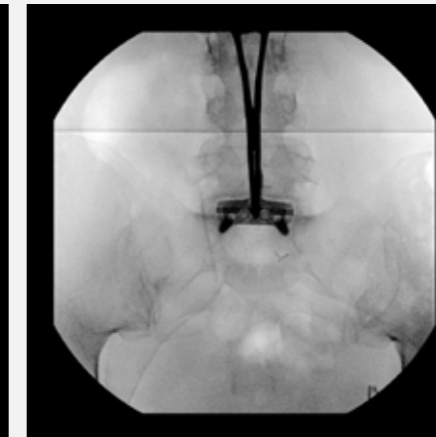
C-arms and video monitors configuration for the percutaneous approach



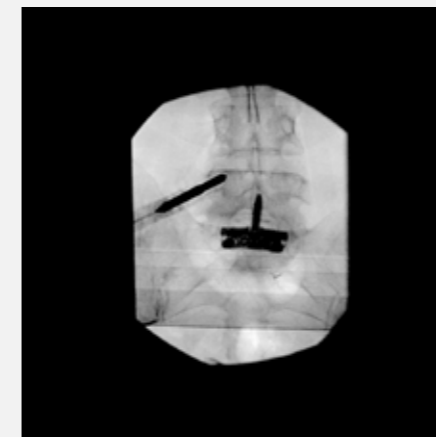Screw insertion with the percutaneous screw guiding tools



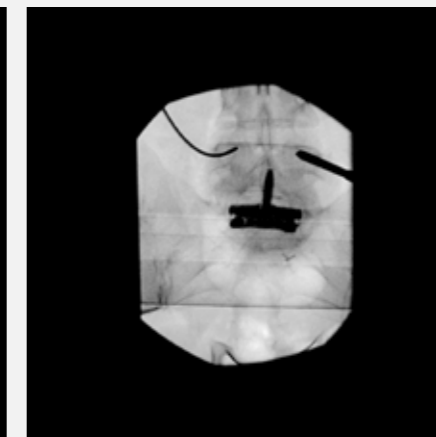
True AP view of L5-S1 disc



Definition of the median line to define incisions for entry points of the 4 screws



First K-wire placement on L5 pedicle



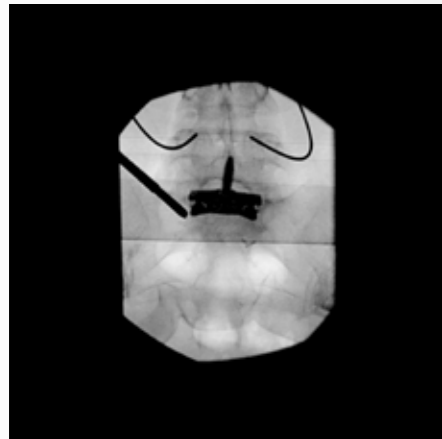
Second K-wire placement on L5 pedicle



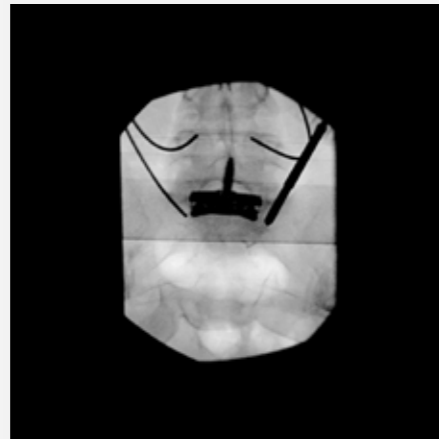
# OEC Elite Touch control panel

Streamline Imaging Workflow during surgery, Synchronize surgical team communication with an interactive live image.

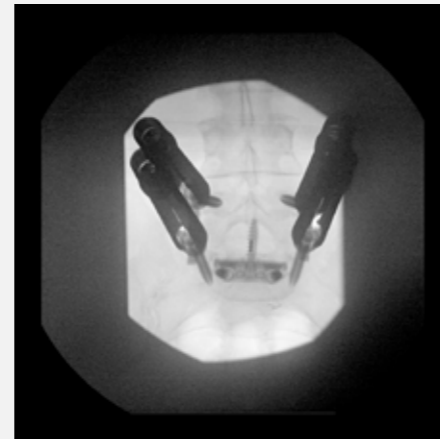
The **intuitive** OEC Elite Touch control panel is designed to bring more control with fewer disruptive steps.



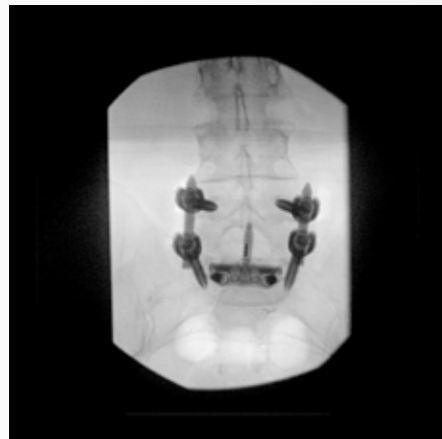First K-wire placement on S1 pedicle



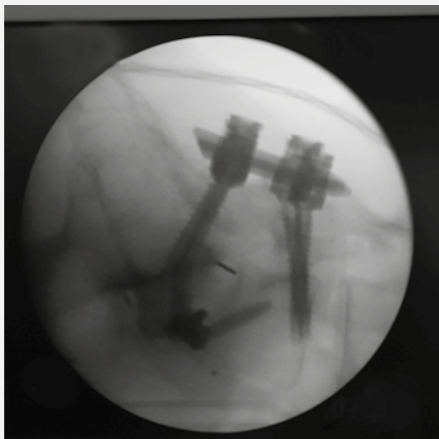
Second K-wire placement on S1 pedicle



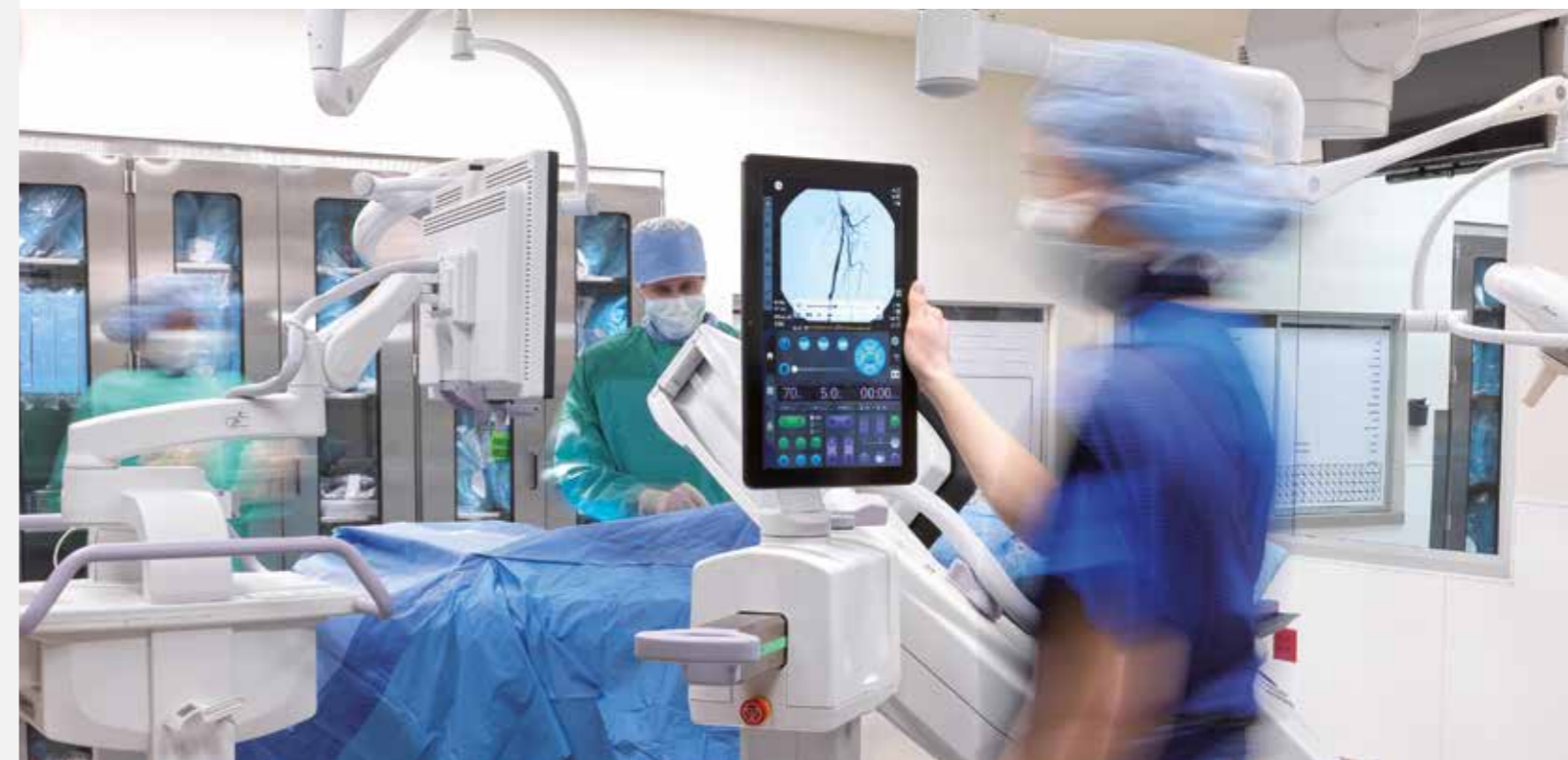Placement of the screws with percutaneous rods



Final AP view control of the pedicle screws and rods

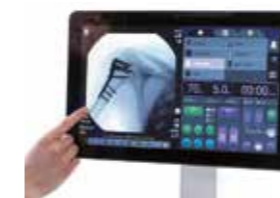

Fluoroscopic image from OEC 9900 Elite. Lateral view.

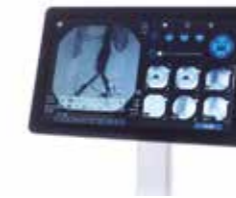

**Dr. David Colle** is a neurosurgeon and has been working at AZ Sint-Lucas in Ghent since 2011. He specializes in spinal instrumentation, brain tumor surgery, and functional surgery. He has specific skills in DBS (Deep Brain Stimulation). He works at AZ Sint-Lucas in Ghent and AZ St-Elisabeth in Zottegem. He is also working in the outpatient clinic in Zelzate.

The statements by GE's customers described here are based on their own opinions and on results that were achieved in the customer's unique setting. Since there is no "typical" hospital and many variables exist, i.e. hospital size, case mix, etc., there can be no guarantee that other customers will achieve the same results.



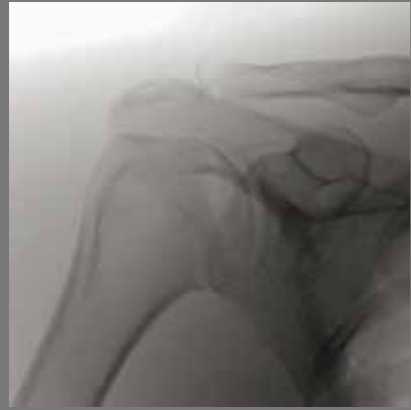**Designed for intuitive operator workflow**



**React instantly during a procedure**



**Position simply for versatile viewing**



# How Live Zoom Imaging Feature Reduces Radiation Dose

OEC Elite CFD feature enables users to enlarge images with less dose

**Author:** Russell Dibb, PhD, Image Quality Scientist, Surgery, GE Healthcare

**Purpose:** Demonstrate the enhanced visualization, fluoroscopic dose savings, and the increased image size advantages of Live Zoom on OEC Elite CFD C-arm systems.

## Introduction

OEC Elite mobile C-arms are designed to produce high-quality, clinically-relevant images at the appropriate dose. Live Zoom, a new imaging feature introduced on OEC Elite premium C-arms, helps minimize dose while delivering excellent, enlarged images. The purpose of this paper is to demonstrate the enhanced visualization, fluoroscopic dose

savings, and the increased image size advantages of Live Zoom on OEC Elite C-arm systems.

## Visualization Advantages of Live Zoom

Designed to enhance clinical decisions and surgical workflow, the Live Zoom feature introduces expanded imaging capabilities for mobile C-arm use.

## Increase up to 4x

Live Zoom enables images to be easily enlarged from 1x to 4x for both static and Cine images (Figure 1). For example, users can freely select between 1x to 4x along a scale, providing greater flexibility enlarging a fluoroscopy or Cine image size compared to the two traditional magnification modes.

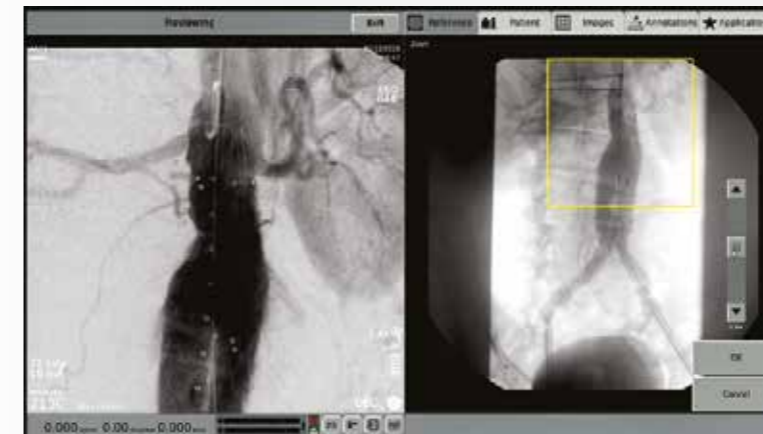

Fig. 1. Live image zoom on left, with area of interest highlighted on right.

## Centering without repositioning the C-arm

Live Zoom enables the user to enlarge a region of the anatomical image on the Live Image display for live fluoroscopy. As opposed to magnification modes, Live Zoom allows any portion of the image to be expanded, allowing even off-center image regions to be viewed in greater detail in real time (Figure 2).

The full-field image is simultaneously displayed on the workstation for context during the exposure and is also available for review after the exposure. This centering feature reduces the disruptive need for the operator to move or reposition the C-arm around the patient during the surgical procedure, which can save time and increase workflow efficiency.

## Dose Advantage of Live Zoom

The following example demonstrates how the use of Live Zoom may lead to

potential dose savings at the beginning of a surgical procedure on a patient's shoulder. The C-arm operator would like to position the C-arm so that the surgeon will have an enlarged image of the joint. An image is requested by the surgeon, and the C-arm operator positions the detector over the patient's shoulder. Two possible approaches to produce the desired image view are:

**Normal + Mag 1:** The C-arm operator performs fluoroscopy for four seconds in Normal to scout, centers the image by moving the C-arm, and then performs a second fluoroscopy for two seconds in Mag 1 to obtain the enlarged image.

**Normal + Live Zoom:** The C-arm operator performs fluoroscopy for two seconds in Normal, then pans to the area of interest to center, then centers the image using Live Zoom, without having to take an additional fluoro image once centered on area of interest.

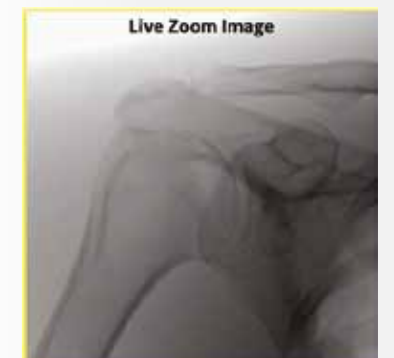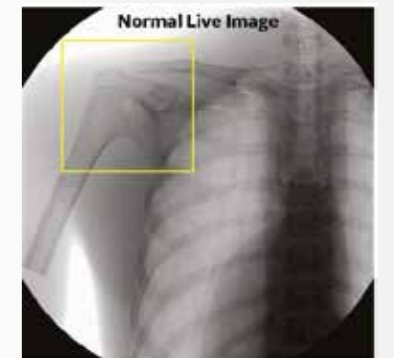
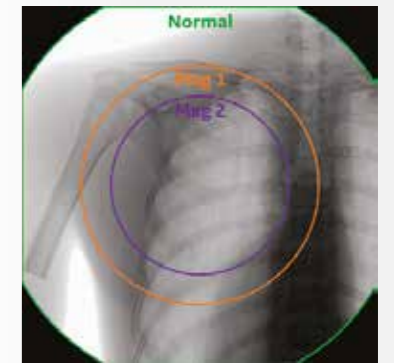


Fig. 2. Comparison of magnification and Live Zoom on a shoulder phantom. Magnification provides an enlarged view of the anatomy of interest by reducing the field of view and displaying a circular image. Live Zoom provides an enlarged view of the anatomy of interest while maintaining the full field of view.



The total dose area product and cumulative Air Kerma generated for each these approaches are shown in Figure 3.

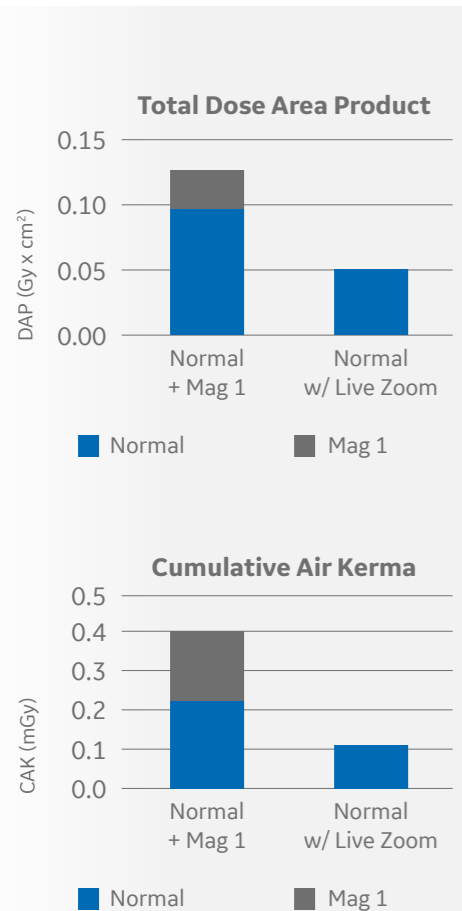


Fig.3. Total dose area product (DAP) and cumulative air kerma (CAK) data collected using a GE OEC Elite CFD, 31 cm detector system performing fluoroscopy on a shoulder phantom.

In this example, Live Zoom yields lower dose than the alternative by requiring shorter and fewer X-ray exposures.

X-ray technique does not change or increase when in Live Zoom, as opposed to the increased technique necessary in magnification modes. As technique drives dose rates, Live Zoom enables less dose and minimizes heat demand on the X-ray tube, particularly during long, complex clinical procedures, such as vascular abdominal aortic or cardiac procedures.

### Persistent Field of View Advantage of Live Zoom

Another advantage of Live Zoom is that once selected, the enlarged field of view is persistent for additional fluoro or Cine images taken. The retention of the zoomed setting reduces the need for the user to re-select the zoomed setting.

Zooming an image while viewing the full field of view can be helpful in many clinical scenarios. It can be used to visualize the entire abdominal area during a vascular procedure while viewing a zoomed image for stent placement. The persistent field of view can also be used to view the entire lumbar spine on the right side of the display to localize a needle insertion site, then use the Live Zoom image on the L4-5 disc region to visualize the disc or joint space in the disc region.

In addition, the image taken in either fluoro or Cine retains the entire field of view imaged, allowing the surgeon to see anatomy outside of the Live Zoom region, while the operator can present the full FOV image by reviewing the image at 1x, thus reducing the need to take another image.

### Conclusion

The Live Zoom feature provides several advantages for generating static and Cine fluoroscopic images and is designed for easy, intuitive use in a variety of surgical procedures and imaging preferences. The most notable advantage of Live Zoom is the ability to easily enlarge and center anatomical images up to 4x while retaining the enlarged image without increasing fluoroscopy dose.

### References

1. Measurements taken on an OEC Elite CFD C-arm with a phantom by GE Healthcare employees.

# CAPITALIZE ON ONLINE RESOURCES to facilitate trainings and increase your professional skills

GE Cares is a **community** where you **connect** with healthcare professionals, **share** your experience, **publish** contents and **learn** new techniques by having a direct access at the clinical webinars, protocols, clinical cases helping you improve your skills. You can also contact GE application specialists whenever you need to ask a question or get supported.



## CONNECT

Connect with other healthcare professionals and grow your network. Interact with key opinion leaders and view their publications.



## SHARE

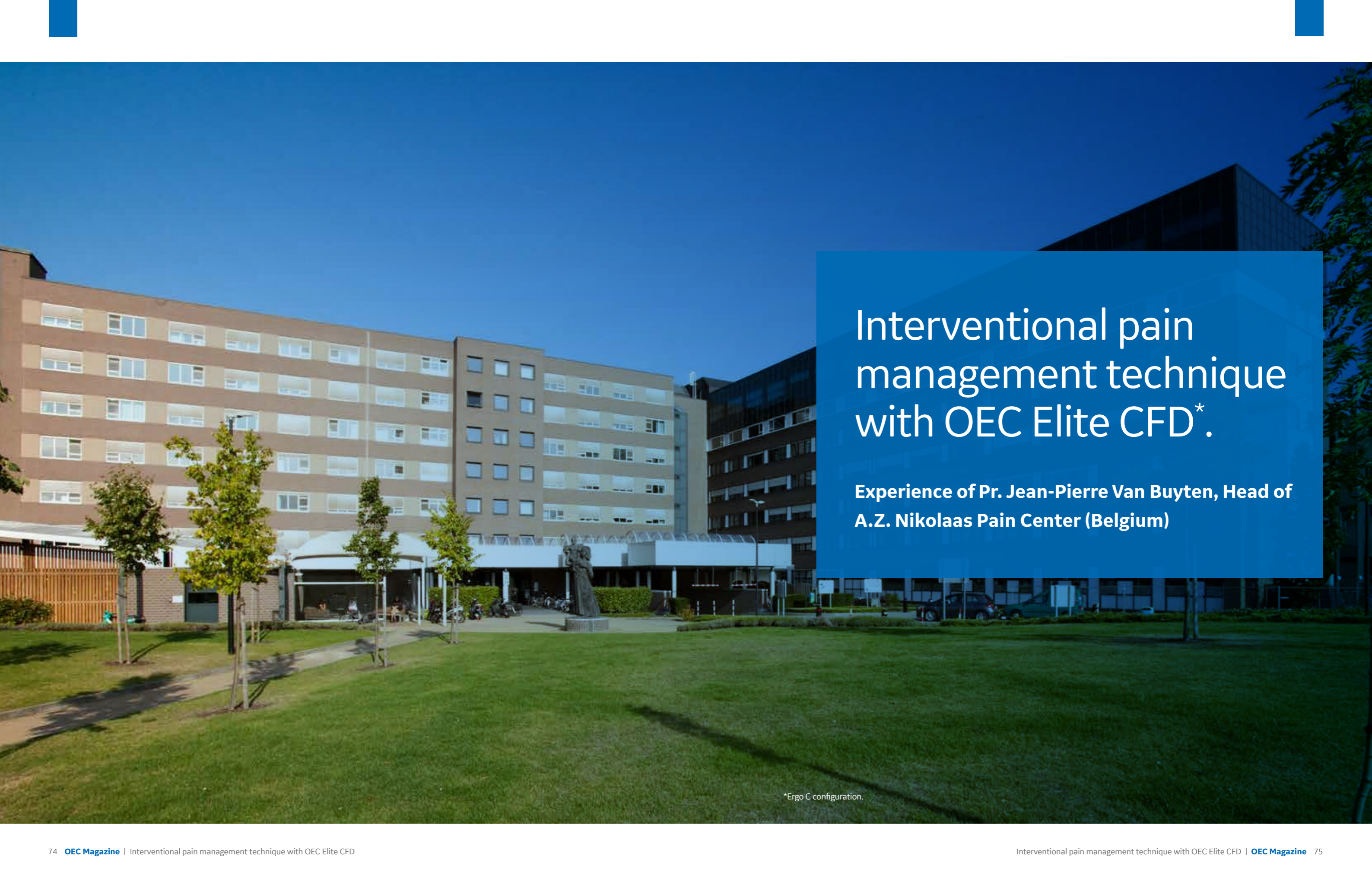
Share your experience, publish content and stay up to date with the latest clinical trends shared by your peers.



## LEARN

Learn new techniques and increase your skills in your daily practice. Access online trainings, educational contents, clinical webinars built by experts for experts.

Join the community now on **GECARES.COM**



# Interventional pain management technique with OEC Elite CFD\*.

**Experience of Pr. Jean-Pierre Van Buyten, Head of A.Z. Nikolaas Pain Center (Belgium)**

\*Ergo C configuration.

The Pain Center is an independent department of the A.Z. Nikolaas Hospital located on the second floor of the main building. It has been designed to welcome the patient in a cozy and calm environment.

The multidisciplinary team performs needle-based treatments that may consist of various therapeutic modalities used alone or together. Physical rehabilitation and psychological support complete the therapeutic care pathway of the patient.

The doctors performing the procedures are always assisted by a nurse dedicated to pain management procedures. The staff is trained to optimize the field of view of the anatomy to be treated and maneuver the C-arm. Located between the interventional rooms, an administrative assistant registers the patient, organizes the agenda and manages the patient's follow up report.

The Pain Center recently acquired an OEC Elite CFD C-arm to equip one of its interventional pain management rooms. The team chose this system for image quality and low dose control. Additionally, they can perform fluoroscopic imaging guidance without support from additional staff.

The center receives patients from Belgium, the Netherlands and northern France, and can treat up to 40 patients per day.

Pr Van Buyten, Head of A.Z. Nikolaas Pain Center, explains why he needs high image quality and anatomical coverage for interventional techniques.

*ease of use, image quality, and radiation-dose management.*

### **What is the challenge for fluoroscopy in needle-based treatments?**

*We work without direct visual control and we need to see what we are doing. Fluoroscopy is, therefore, our eyes. We always work in continuous low dose mode, with collimation, thus obtaining a very good image of the cortical bony landmarks and the needle. When we inject contrast media, we can easily identify the shape of the nerve and predict the spread of the drugs we want to give.*

*The challenge is that unlike bone, the nerve is radiotransparent. In order to position the needle tip in the right location, we use a specific technique called the 'tunnel vision' technique.*

*The needle entry point is defined by palpation, confirmed with fluoroscopy, and marked over the patient's skin. The C-arm is then angulated to get a true AP view of the nerve to be treated using bony anatomical landmarks. When the C-arm angle is correct, the needle is angulated under fluoroscopic imaging guidance until it appears as a dot and not as a line. The needle axis is then aligned with the detector axis, providing a 'tunnel vision' of the needle. Once this dot is obtained, the C-arm is moved to a lateral position and the needle is pushed into the nerve under fluoroscopic imaging control. Contrast media is injected and flows along the nerve. The fluoroscopic image that shows the shape of the nerve confirms that the needle is in place ready for the treatment.*

*It may consist of various interventional procedures such as epidural injections, intrathecal therapy, nerve blocks, neuromodulation or physiotherapy, and psychological support.*

*Interventional pain management involves treating the nerve either at the level of the central nervous system, or more locally at its root, injecting drugs, or applying radiofrequencies. These needle-based procedures require fluoroscopy guidance. Our center chose the OEC Elite CFD because of its*

### **Can you give us an overview of what pain management is?**

*The perception of pain varies from one individual to another. More than just a feeling, it also involves the emotion of suffering, which is specific to the patient's personal history. In our center, clinical psychologists, pain specialists, and physiotherapists work together in collaboration with the patient to assess the clinical and overall situation. Depending on this assessment, the optimal algology treatment is defined.*

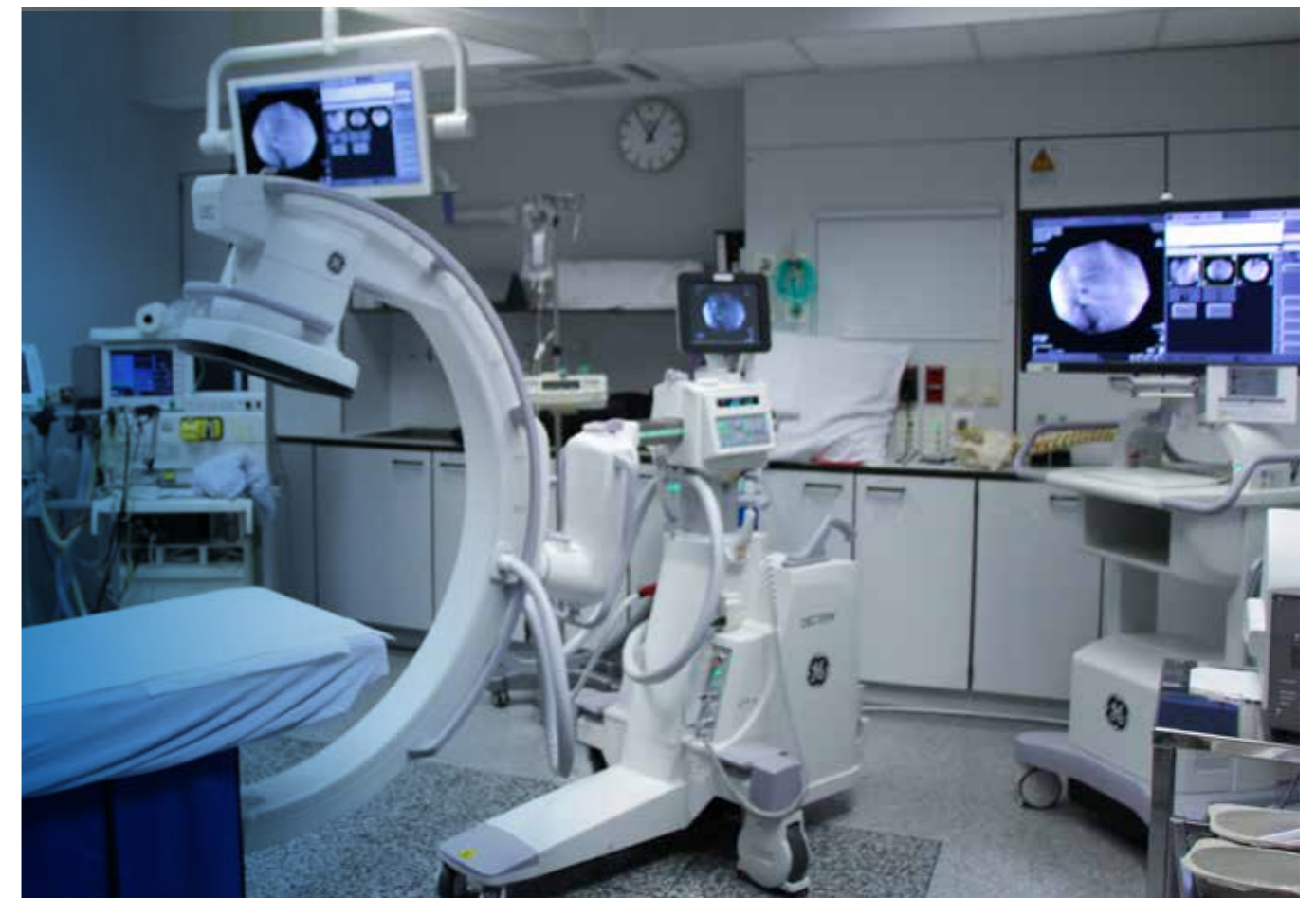*investigate the appropriate access for that patient.*

*The patient is placed on the examination table in prone position. For cervical treatment, the OEC Elite CFD C-arm is placed at the level of the patient's head. For thoraco-lumbar procedures, the C-arm is placed at the side of the patient, orthogonal to the patient table.*

*The OEC Elite CFD C-arm is positioned over the anatomy to be treated. A light tension is applied to all the brakes. When we need to change the view, the nurse moves the C-arm to reposition the detector to the area of interest. Because the C-arm is well balanced, it*

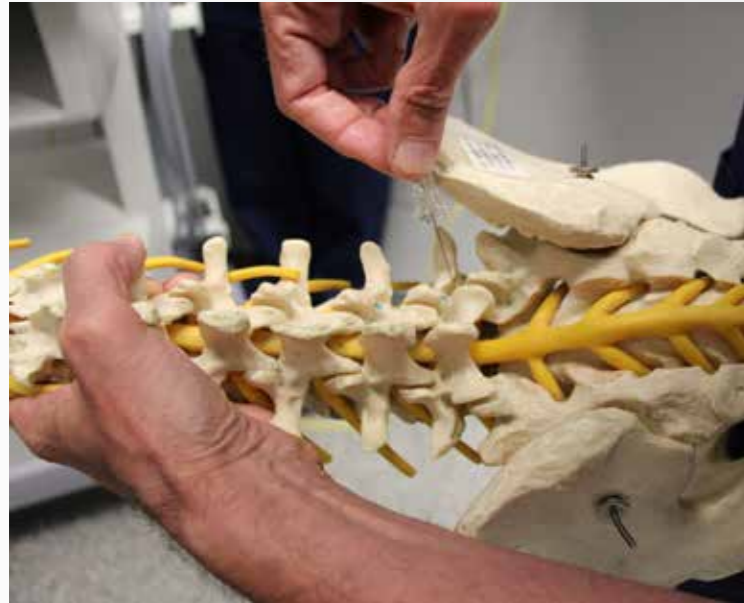*stays in place after motion.*

*The most complex procedures in terms of imaging are those performed on the cervical vertebra area, and on patients who have undergone surgeries involving implants, such as arthrodesis. It is more difficult to find the path to direct the needle to the nerve. OEC Elite CFD image quality allows us to proceed with confidence to correctly position the needle tip for the injection.*

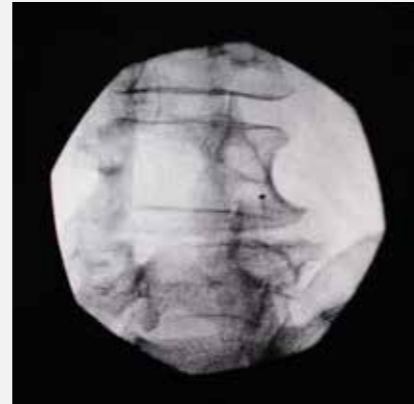

Set-up for cervical spine procedures

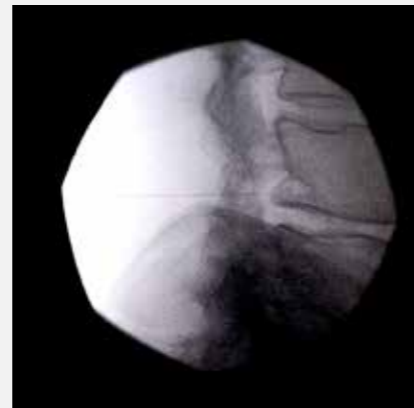## Corticoids injection into the L4 lumbar nerve



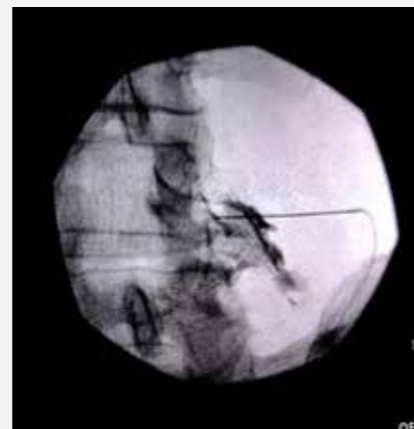
Transforaminal placement of the needle



**Fig. 1.** Antero-Posterior view showing the dot shape of the needle positioned using the tunnel vision technique. The partial scotty dog shape is due to the laminectomy of the L4.

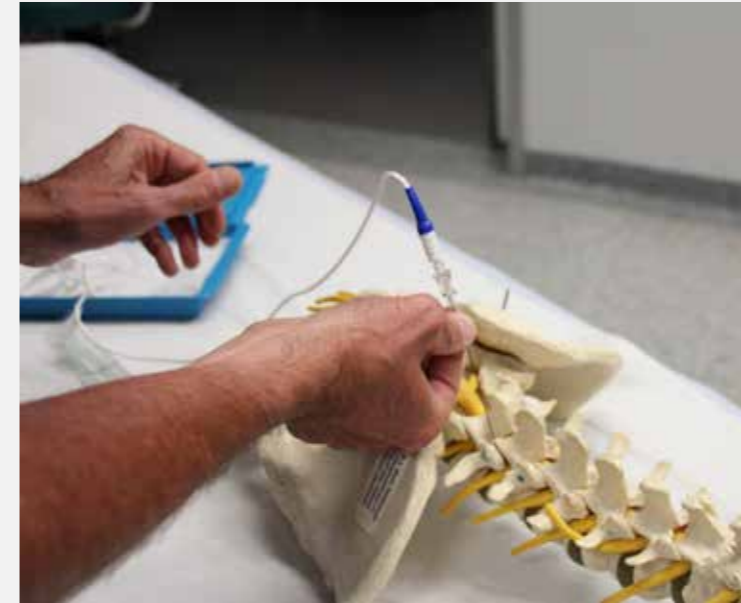

**Fig. 2.** Lateral view showing needle insertion into the neuroforamen.



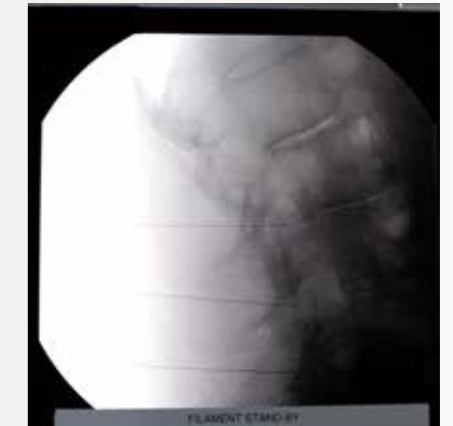**Fig. 3.** Contrast media injection showing nerve root shape at the tip of the needle.

## Radiofrequency treatment

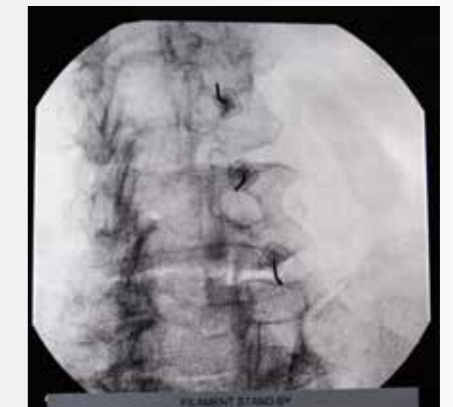

Transforaminal placement of the needle with the probe connected to the RF generator. The RF protocol differs as a function of the localization of the nerve (lumbar or cervical).

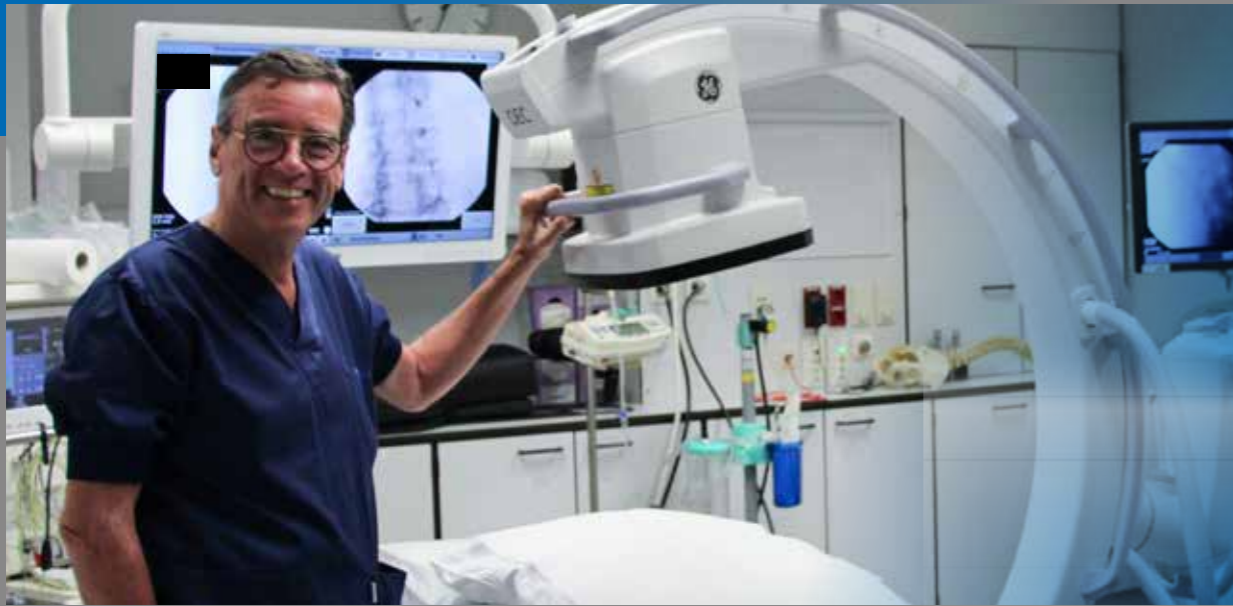The treatment includes heating the nerve. The heat reduces the conductivity of the neurotransmitters of the nerve, reducing the sensation of pain. The procedure is performed by inserting a dedicated needle into the point to be treated with the tunnel vision technique, inside which is inserted a probe conducting the RF sequence. In the lumbar area, the treatment is performed by placing the probe into three needles positioned along the nerve.



**Fig. 1.** Lateral view of lumbar medial branch RF treatment. The fluoroscopy image shows the three needles.



**Fig. 2.** Ap view of lumbar medial branch RF treatment. Fluoroscopy image of tunnel vision view of the three needles and electrodes.



*I trained with the pioneers of pain therapy in Belgium early on in my anesthesiology career, beginning in the early 1980's. I was attracted by the therapeutic techniques, and the contact with the patient.*

*Patients coming to me have complicated medical and psychological issues related to their pain. Some have high pain tolerance thresholds, while others struggle to function. Our goal is to treat their pain holistically so that they can lead a more normal life.*

*With these interventional techniques we can help patients fight the pain. We believe that these therapies are a better alternative than opioid treatments because of the risk of addiction. To that end, I participate in many awareness and educational programs promoting interventional pain management and procedures. I work with the Flemish Pain Relief Association VAVP, and the European Continuing Medical Training (ECMT) program for neuromodulation techniques. I also coach in a pain center in Kuwait to develop these techniques.*

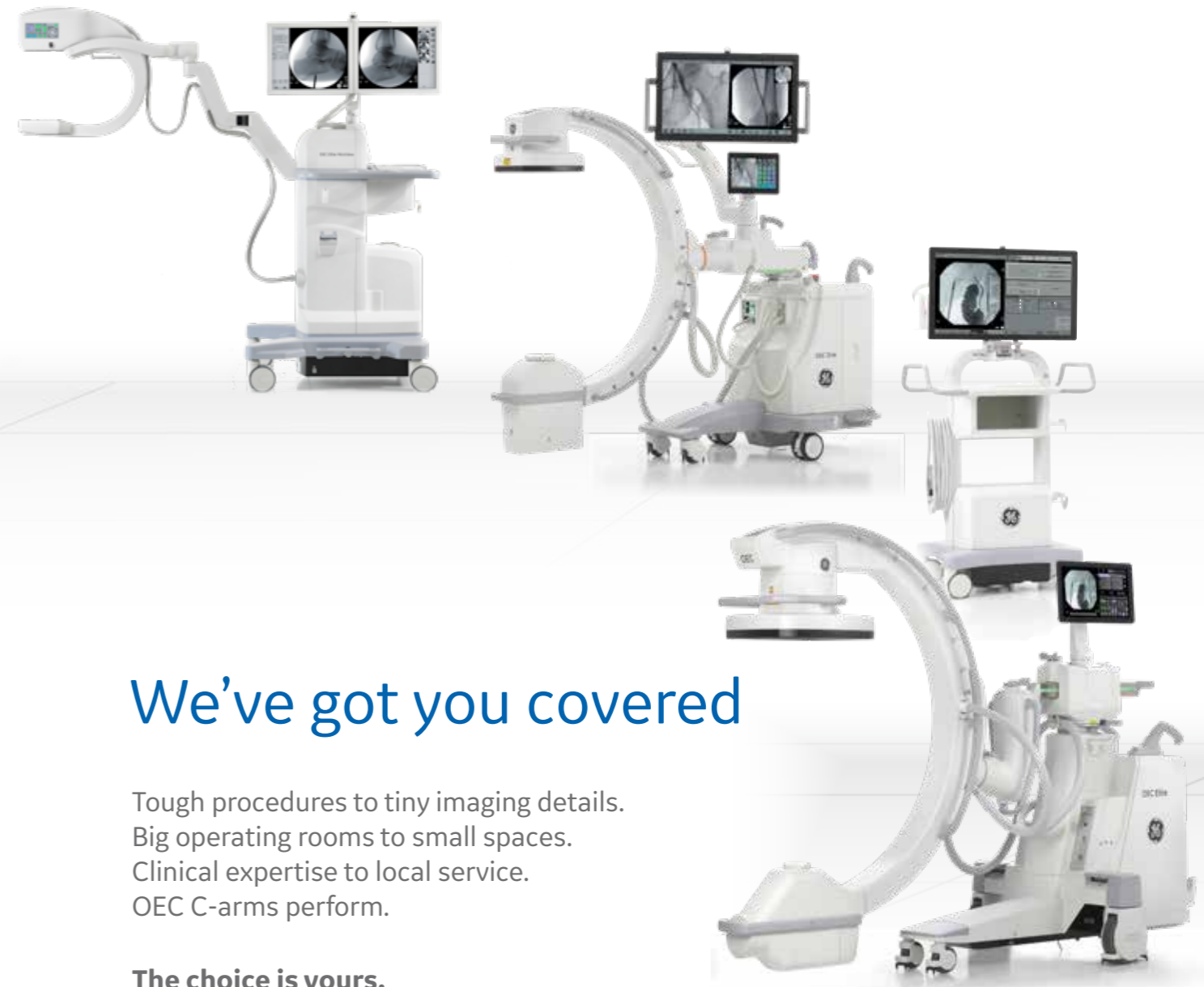*I expect that in the future there will be more and more interventional techniques of neurostimulation of the peripheral nerve. As long as there is surgery, there will be algology.*

*Any surgery done in an innervated zone presents a risk of chronic pain. For example, 15% of patients undergoing inguinal hernia surgery which is a common surgical procedure, have chronic pain after the operation. After a mastectomy, 30% of the patients have neuropathic pain. After thoracotomy for lung intervention, 50% of the patients have post-operative pain. We see more and more facial pain because facial and cosmetic surgery procedures are increasing. The same goes for knee replacement surgery. Many of our patients come to us for back pain intervention after surgery.*

*Also, it is important that we manage the radiation dose to the staff as we work with fluoroscopy every day. I therefore chose to equip the room with the OEC Elite CFD C-arm with a new detector that is designed to provide excellent image quality at low dose. We also acquired an ImagiQ2 table (Stille, Sweden) that helps to optimize radiation dose management with its high transparency. We are trained to practice ALARA fluoroscopy: we take few images, use the collimation, the laser aimer, and bring the detector closer to the patient. We are very comfortable using the OEC Elite CFD C-arm for our interventional procedures.*



The statements by GE's customers described here are based on their own opinions and on results that were achieved in the customer's unique setting. Since there is no "typical" hospital and many variables exist, i.e. hospital size, case mix, etc., there can be no guarantee that other customers will achieve the same results.



## We've got you covered

Tough procedures to tiny imaging details.  
Big operating rooms to small spaces.  
Clinical expertise to local service.  
OEC C-arms perform.

**The choice is yours.**





# GE Healthcare supporting Education and Continuing Professional Development (CPD) for radiographers

Health services across Europe are under increasing pressure, and a principal focus going forward will be managing increasing demands on healthcare staff, whilst supporting enhancement of the knowledge, skills, and competency base.

The general budget constraints affecting the healthcare sector also impact the budgets that can be allocated to the Continuing Professional Development<sup>1</sup> (CPD) of healthcare professionals. Nevertheless, delivering CPD remains critical because it provides benefits not only to every individual, but also to their professions and their patients. CPD ensures that professionals maintain and enhance the knowledge and skills they need to deliver the safest service to their patients, to get the higher rates of patient satisfaction with their care and the lower rates of safety incidents.

GE Healthcare is working with providers to facilitate access to equipment training and best practices, by sharing through its online platform, GE Cares ([gecares.com](http://gecares.com)) which can be accessed using a laptop, smartphone, or tablet.

The OEC C-arm team, at GE Healthcare, has developed an education package under the Brilliant Learning face-to-face training program, a course for CPD, dedicated to surgical imaging and use of technology to review best practices in optimizing image quality, while ensuring that dose is as low as reasonably achievable.

## What is the Brilliant Learning program about?

GE Healthcare has developed the "Optimizing Image Quality (IQ) & Dose using Surgical C-arms" interactive training module as part of the Brilliant Learning program, combining presentations and system hands-on system training which is delivered for free to all who request it and can be delivered in person at the customer site, during congresses, or at user meetings. The duration of this training can be flexible according to the needs, varying from one hour to a full-day training course.

## The Brilliant Learning program is based on 3 pillars:

1. As Low as Reasonably or Diagnostically Achievable (ALARA/ALADA) principles;
2. Best practices to optimize IQ & dose management; and
3. Innovations in Surgical C-arm technology, improving IQ and managing dose.

## The objectives of the Brilliant Learning program are:

- Improve Practical Skills on mobile C-arms;
- Review basic principles of X-Ray radiation safety;
- High-Quality Healthcare service provided to patients; and
- Workforce development and Staff governance.

For more details about this training program, or to check availability, please contact your local OEC C-arm representatives.



## Continuing Professional Development (CPD) in the United Kingdom

In UK, the Brilliant Training received “CPD-Now endorsement”; the training was matched to a range of professional standards from the College of Radiographers.



The first six sessions were offered during UKIO (2019), a national conference for imaging that attracted over 3,000 visitors. Since then, the GE team has been delivering the Brilliant Learning program across the UK.

“GE Healthcare provided a free educational session for our radiographers in September 2019 reviewing image quality and dose reduction in theater using an Image Intensification detector and compared it to the benefits of a CMOS flat detector. A CPD certificate bearing the CoR CPD Now endorsement logo was issued to all our staff and given a ‘Radiation Safety Quick-Guide’ booklet for future reference. The session came at a good time for our newly recruited



staff too, helping them with their induction, and those who have been with us for a while also found it beneficial as technology is always evolving and a face-to-face learning session gave opportunities for questions and answers afterwards. The link for the GE Healthcare new GE Cares Education Portal was also shared with the team for them to sign up for free,

access up-to-date information, and to connect, share, and learn.”

**Beverly Tweed, Radiology Section Manager for Theaters and the General dept. at Hull University Teaching Hospitals NHS Trust.**



For more education content, join us on GE Cares

1. Continuing professional development (CPD) in radiography: A collaborative European meta-ethnography literature review  
2. Accredited CPD Center: The CPD standards office CPD Provider: 60046 (2018 – 2020) www.cpdstandards.com

A. Wareinga,b,\*;Correspondence information about the author A. Wareing;Email the author A. Wareing, C. Buissinkb,c, D. Harperb,d, M. Gellert Olesenb,e, M. Sotob,f, S. Braicob,g, P. Van Laerb,h, I. Gremionb,i, L. Rainfordb,j



## The Society of Radiographers in Finland (SORF)\* and GE Healthcare jointly organized a surgical imaging education event

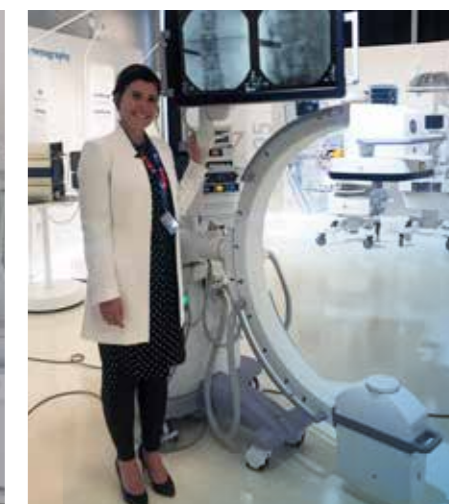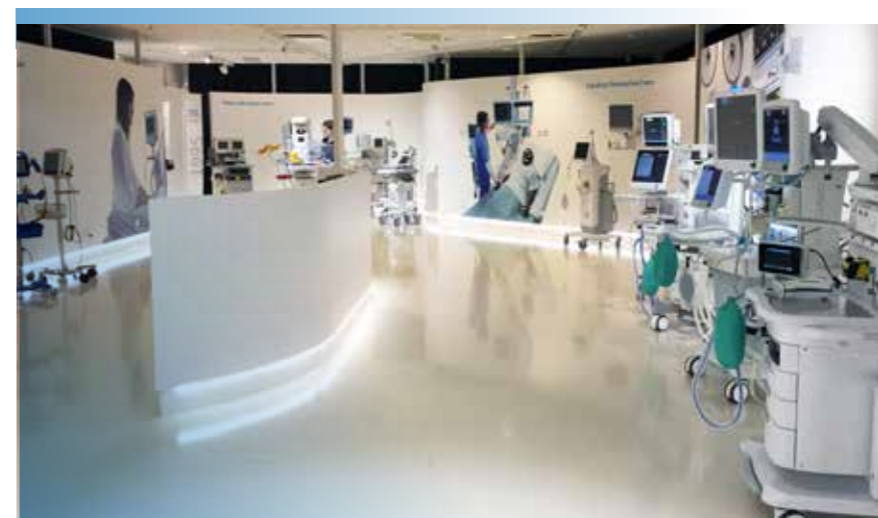This year, 40 participants attended the mobile C-arm education meeting jointly organized by the Society of Radiographers in Finland, and GE Healthcare in the GE Helsinki Customer Center. The target audience of this C-arm educational meeting was surgeons, surgical nurses and other members of the surgical staff that operate the C-arms. In Finland C-arms are seldom operated by radiographers and building a theoretical and practical knowledge about radiation protection is extremely important.

### The 2-day agenda covered the following topics:

- X-ray fundamental refresher;
- Radiation protection of the staff and the patient, presented by a clinical expert from HUS (Helsinki University Hospital);
- Laws and regulations in Finland, regarding the use of C-arms (SORF)
- Workshops/Hands-on session: Compact C-arm, Mini C-arm, Quality assurance, Self-assessment;
- Working in a hybrid room, EVAR delivered by a Vascular surgeon from HUS;
- Technical quality assurance and servicing of C-arms, presented by a

- Physicist at HUS;
- Radiation Biology, presented by a Physicist at HUS;
- Abnormal situations when using X-rays, presented by SORF;
- Safety culture, presented by SORF; and
- Best practice sharing and end session debrief.

Given that the feedback was extremely positive, the dates of next year’s session have already been scheduled by both The Society of Radiographers in Finland (SORF)\* and GE Healthcare. For more details about this education meeting, please contact your local surgery representatives.



\*SORF was founded in 1958 and it now has over 3,500 members. The Society is a professional organization looking after the interests of all radiographers (also including radiation therapists and sonographers). The society promotes clinical radiography in the Finnish society and ensures that radiographers have the readiness to provide high-quality radiography services in the Finnish health care system, both in the public and private healthcare sectors.

The statements by GE’s customers described here are based on their own opinions and on results that were achieved in the customer’s unique setting. Since there is no “typical” hospital and many variables exist, i.e. hospital size, case mix, etc., there can be no guarantee that other customers will achieve the same results.

# OEC C-arms

## MAKE YOUR SURGICAL

Orthopedics, Urology, Pain Management, Spine,

## IMAGING EASY WITH THE OEC C-ARMS

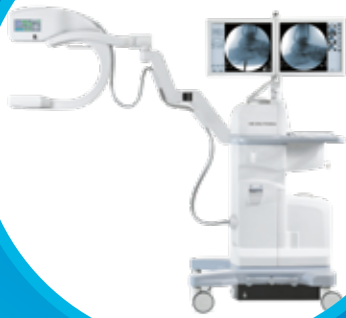Vascular, Cardiac

### EXTREMITIES SURGERY

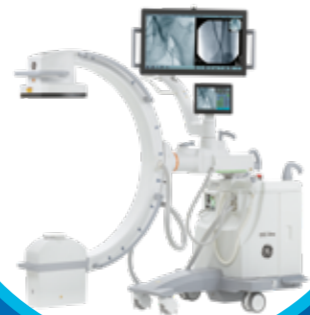### GENERAL SURGERY

### ADVANCED SURGERY

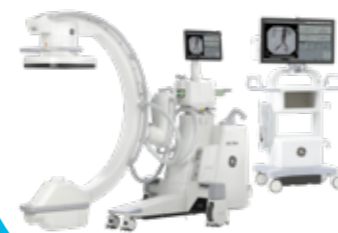OEC Elite MiniView



OEC One CFD

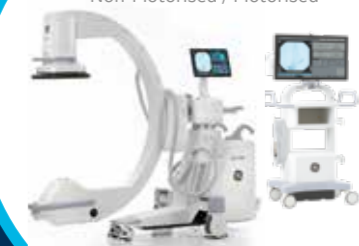

OEC Elite CFD Ergo-C

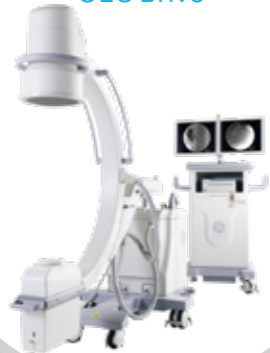

OEC Elite CFD  
Super-C

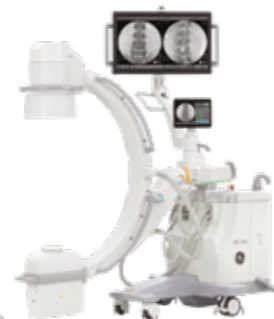Non-Motorised / Motorised



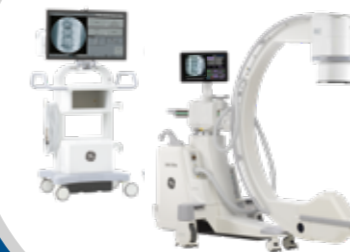OEC Brivo



OEC One



OEC Elite



\* CMOS flat panel detector  
\*\* Image intensifier

INNOVATION. PERFORMANCE. INTUITIVENESS. RELIABILITY.

The OEC family of mobile C-arms has been used by surgeons for more than 40 years enabling clinical and operational excellence.

More than 35,000 systems installed worldwide remain hard at work close to 15 years after their first procedure.



## GE Healthcare

GE Healthcare provides medical technologies and services to help solve the challenges facing healthcare providers around the world. From medical imaging, software, patient monitoring and diagnostics, to biopharmaceutical manufacturing technologies, GE Healthcare solutions are designed to help healthcare professionals deliver better, more efficient and more effective outcomes for more patients.

GE Healthcare is betting big on digital; not just connecting hospital departments and physicians more effectively, but utilizing the masses of data from its equipment and the collaboration between hardware and software – “digital industrial” – to help clinicians make better care decisions. Sensors, software and smart data analytics are converging to enhance GE Healthcare’s offerings not just in diagnostics, but also pathology, gene sequencing and even hospital asset tracking.

[www.gehealthcare.com/surgical\\_imaging](http://www.gehealthcare.com/surgical_imaging)



© 2020 General Electric Company - All rights reserved

GE Healthcare reserves the right to make changes in specifications and features shown herein, or discontinue the product described at any time without notice or obligation. Contact your GE Healthcare representative for the most current information. GE and the GE Monogram are trademarks of General Electric Company. GE Healthcare, a division of General Electric Company. GE Medical Systems, Inc., doing business as GE Healthcare.

Products may not be commercially available in all markets. Please contact your sales representative for more information.

The statements by GE's customers reported here are based on results that were achieved in the customer's unique setting. Since there is no “typical” hospital and many variables exist, i.e., hospital size, case mix, etc., there can be no guarantee that other customers will achieve the same results.

JB80401XE