



Low-dose PET Imaging of Prostate Cancer

Case submitted by Jaslok Hospital & Research Centre, Mumbai, India

Patient history

A 66-year-old patient with known case of adenocarcinoma of the prostate (Gleason's score 3+4=7), multiple skeletal metastases, post-hormonal therapy (2 cycles of ¹⁷⁷Lutetium PSMA therapy); referred for treatment response evaluation.

Imaging results: pre-treatment

Gallium-68 (⁶⁸Ga) PSMA¹ on Discovery IQ 5-Ring was performed. PSMA expression is seen in the lesion involving entire prostate gland, with extension into the bilateral seminal vessels, the posterior wall of the bladder and the anorectum, compatible

with known primary prostatic malignancy. PSMA expression also seen in multiple osseous lesions as well as right pulmonary nodules and bilateral hilar lymph nodes. Bilateral ribs and left peri bronchial lymph nodes are metastatic.

Imaging results: post-treatment

Low-dose (3.23 mCi) ⁶⁸Ga PSMA scan: no new lesions seen; reduction in size and PSMA expression of prostate, lymph nodes and osseous lesions noted; right pulmonary nodule no longer seen. Scan findings are suggestive of response to therapy. ■

1. Radiopharmaceuticals discussed here may not be approved in every country; may not be available in all markets.

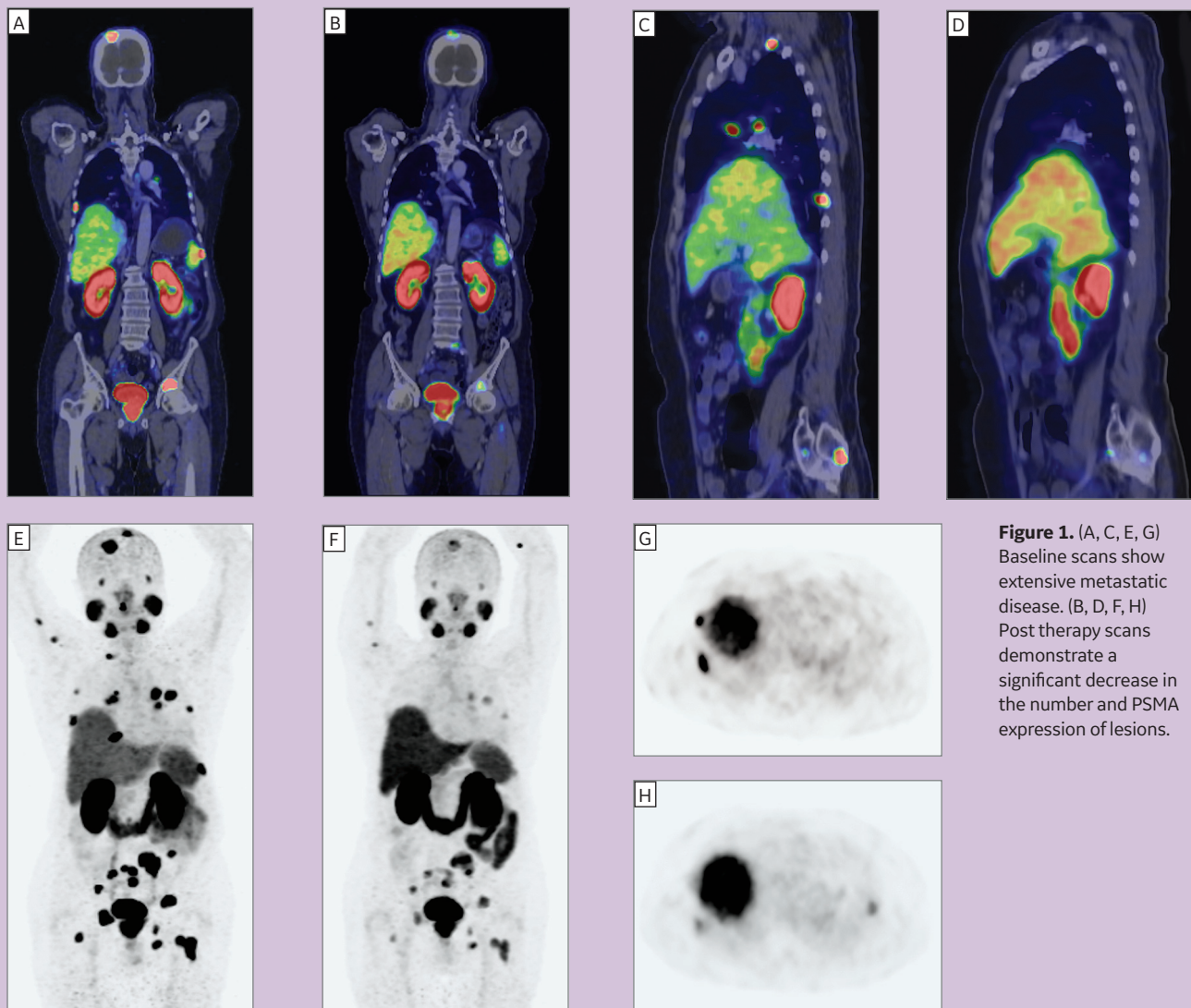


Figure 1. (A, C, E, G) Baseline scans show extensive metastatic disease. (B, D, F, H) Post therapy scans demonstrate a significant decrease in the number and PSMA expression of lesions.