

# Precious hearts. Precise imaging.

## The tiny solution expanding the reach of 4D imaging to more pediatric congenital heart disease patients

Real-time 3D echocardiography is rapidly transforming the diagnosis and management of congenital heart disease (CHD). While it's not yet the standard in pediatric cardiology, the technology is playing a crucial role in patient assessment, pre-surgical planning, and interventional guidance. The world's first mini 4D TEE probe is leading the evolution—unlocking a new dimension of imaging for some of the smallest hearts.





For physicians like Prof. Philippe Acar, who has spent three decades developing 3D imaging technology, the innovation is a long time coming. Dr. Acar, a Professor of Pediatric and Congenital Cardiology at Toulouse University Hospital in southwestern France, was among the first to experience the 9VT-D miniaturized probe. The compact transducer, powered by the Vivid™ E95 Ultra Edition, enables real-time multiplane and 3D imaging in patients as small as 5 kg. Dr. Acar also contributed to growing research that supports the probe's feasibility, handling, and image quality in daily practice.

Congenital heart disease is the most common birth defect worldwide<sup>1</sup> and makes up a large portion of the cardiac caseload at Toulouse

University Hospital. The team performs approximately 200 to 250 surgeries annually, with a similar volume of catheterization procedures. It also conducts 10,000 consultations a year for children, adolescents, and adults with a range of congenital heart defects.

Precise assessment of CHD is essential because each patient's anatomy is unique. Clinicians need the right images for a thorough understanding of cardiac anatomy and hemodynamics to select the best treatment strategy. Unfortunately, 10% of pediatric echo diagnostics are driven by misleading anatomy or physiology.<sup>2</sup>

We recently met with Prof. Acar and three of his colleagues from Toulouse University Hospital: Dr. Clément Karsenty, Head of the Pediatric Cardiology Department; Dr. Khaled Hadeed, pediatric cardiologist; and Dr. Najeeb Bina, pediatric & congenital heart surgeon, to learn more about how the mini 4D TEE probe is impacting care for CHD patients.

**What are the main challenges in treating patients with congenital heart disease and why is imaging precision, especially in echocardiography, so crucial?**

**Dr. Hadeed:** Each heart defect is unique. There are always specific anatomical peculiarities, highlighting the importance of precise evaluation to offer personalized treatment. Congenital heart disease primarily affects young children, including newborns, who are physically fragile, further complicating care. The timing of treatment is also crucial and often stressful for parents. Therefore, it's essential to reassure parents and conduct a precise evaluation to propose the best therapeutic strategy, minimizing medium- and long-term risks.

*Echocardiography is a routine, non-invasive, low-cost, and non-irradiating examination that provides a typically comprehensive anatomical and hemodynamic assessment of the defect, helping to determine the most suitable treatment.*

**Dr. Karsenty:** Advances in imaging over recent years and decades have revolutionized diagnosis and patient management. 4D imaging, in particular, allows us to refine and enhance how we care for our patients.

**Can you describe the probes you used before the introduction of GE HealthCare's mini 4D TEE probe, and what were their inherent limitations?**

**Dr. Hadeed:** For transesophageal echocardiography, we used pediatric 2D mini probes, which allowed for

conventional 2D evaluation of congenital heart defects in children weighing between 5 kg and 25 kg. We also had an adult 3D matrix probe for larger children over 25 kg. However, we were limited for children under 25 kg as we didn't have a 3D matrix probe for this population.

**“** Today, having access to a 4D mini TEE probe is indescribable in terms of ease and comfort.”

**Dr. Bina:** The 2D probes had many limitations. I've worked in various contexts outside of Europe, for example, in Africa or Asia, where we had to use transthoracic probes for transpericardial use. These required sterile conditions and gel application, which were cumbersome. Today, having access to a 4D mini TEE probe is indescribable in terms of ease and comfort. It's extraordinary what can be achieved with 4D imaging.

**How has the mini 4D TEE probe allowed you to extend the use of 4D echocardiography to a broader patient population?**

**Prof. Acar:** The real revolution with this new pediatric probe is the ability to perform 4D imaging in children and even small infants, which was previously impossible due to the need to use adult probes. For children weighing less than 25–30 kg, 3D transesophageal echocardiography was simply not feasible.

**Dr. Hadeed:** The pediatric mini 4D TEE probe is a revolutionary tool for managing congenital heart disease as it brings 4D technology to small children, which wasn't available before. This probe can be used for newborns, infants, and young children weighing as little as 5 kg—providing detailed, dynamic 3D imaging to propose the best-tailored care.

**What is the added value of 4D echocardiography compared to 2D echocardiography in managing congenital heart defects?**

**Dr. Hadeed:** Traditionally, examining congenital heart defects has relied on 2D echocardiography, which involves taking multiple slices to explore the defect. The operator must mentally reconstruct these slices into a 3D image to understand the complexity of the defect. The main limitation of this approach is that the interpretation of 2D echocardiography is operator-dependent and may not always reflect reality.

**“** The pediatric mini 4D TEE probe is a revolutionary tool for managing congenital heart disease as it brings 4D technology to small children, which wasn't available before. This probe can be used for newborns, infants, and young children weighing as little as 5 kg—providing detailed, dynamic 3D imaging to propose the best-tailored care.”



4D echocardiography provides a volumetric, real-time view of the defect, offering a direct visualization of the geometry of the cardiac anomaly and its spatial relationships with other structures. This enables a better spatial understanding of the anomaly and the development of the optimal surgical strategy.

**Dr. Karsenty:** With 2D echocardiography, we view the heart in specific slices but only within a single plane. Thanks to 4D imaging, we can be completely immersed in the heart, enabling us to understand malformations at a glance. This immediate comprehension allows us to choose the best treatment strategy for our patients.

**Prof. Acar:** 4D imaging provides a superior advantage by allowing us to visualize not just a single slice but the entire intracardiac view. For many malformations, it delivers critical anatomical insights.

**Dr. Bina:** As a pediatric & congenital heart surgeon at the University Hospital of Toulouse, I must emphasize how much easier things are today with the introduction of 4D probes compared to a few years ago. As you know, pediatric cardiac surgery is about anatomical heart repair. This means we need a wealth of information—not only about anatomy but also about the histopathology and internal structures of the heart.

Today, with 4D probes, we can gather information not just on the heart's anatomical structure but also on tissue quality. This is particularly useful in valve repairs, such as for

atrioventricular canal defects, ventricular septal defects, or Ebstein's anomaly. These insights significantly enhance our ability to assess tissue quality and aid in making better surgical decisions.

**What were your first impressions when you discovered the mini 4D TEE probe?**

**Dr. Karsenty:** The first time we used the mini 4D TEE probe, we were genuinely impressed. The image quality was exceptional, both in small children and older ones, whether using 2D or 4D imaging. The image quality of this probe was truly astonishing from the first use.

**Prof. Acar:** Having been involved in pediatric probe development, where adult probes are often adapted for pediatric use, earlier models were not always optimal for children. With this probe, we immediately recognized its high quality in 2D imaging. The 4D volumetric imaging, which we had previously explored with transthoracic approaches, provided excellent volumetric rendering with smooth frame rates, offering valuable information.

**Dr. Bina:** Firstly, the ease of insertion and the compact size of the probe impressed me. Once anesthesia is administered, we can gather all the necessary information within two minutes, collaborating with the cardiology and anesthesia teams. Before making the incision, we conduct a 5- to 10-minute debrief based on the echocardiographic images obtained in the operating room. This provides us

with a wealth of information. The images are fresh in our memory, allowing us to save valuable time assessing anatomical structures. This is particularly helpful as we can view not only the surgical field but also anatomical structures through the TEE probe—such as transventricular and transatrial views.

“The first time we used the mini 4D TEE probe, we were genuinely impressed. The image quality was exceptional, both in small children and older ones, whether using 2D or 4D imaging. The image quality of this probe was truly astonishing from the first use.”

**Your team published a prospective study on the mini 4D TEE probe: ‘Advancing paediatric cardiac imaging: a comprehensive analysis of the feasibility and accuracy of a novel 3D paediatric transesophageal probe’<sup>3</sup> in 2023. Can you share the key results?**

**Dr. Karsenty:** We published a study on the first 4D TEE procedures performed with this mini 4D TEE probe at the University Hospital of Toulouse. The results align with our daily practice, demonstrating excellent outcomes.

“The image quality is outstanding, regardless of the patient's size, from newborns to larger children of adult size. Both 2D and 4D imaging provide nearly perfect resolution. In our study, we also showed that for two patients, the probe enabled us to revise the diagnosis, leading to better patient management.”

The probe is easy to insert, even in patients as small as 5 kg and as large as 75 kg. The image quality is outstanding, regardless of the patient's size, from newborns to larger children of adult size. Both 2D and 4D imaging provide nearly perfect resolution. In our study, we also showed that for two patients, the probe enabled us to revise the diagnosis, leading to better patient management.

**Can you explain in more detail how you are currently utilizing the 4D mini probe in practice and what is the main benefit?**

**Dr. Karsenty:** We use the 4D probe in two main pediatric situations: in the operating room, before and especially after cardiac surgery, to confirm successful outcomes and check for residual lesions. We also use the probe in the catheterization lab, which is of particular interest to me, to guide the

procedure throughout the intervention. The primary advantage of this 4D probe, especially in interventional catheterization, is the ability to guide the procedure with precision across all planes simultaneously.

**Prof. Acar:** Each professional, whether a catheterization specialist, surgeon, or imager, has their own perspective. From my standpoint, as someone more experienced in cardiac imaging, I find the technology astonishing. To fit this matrix into a tiny, flexible probe and make it usable in children as small as 5 kg is remarkable, all while maintaining excellent 2D image quality.

**Has the mini 4D TEE probe changed how surgeons and interventional cardiologists approach procedures?**

**Dr. Karsenty:** The transition from 2D to 4D imaging has significantly improved communication between echocardiographers, surgeons, and interventionalists. A single image now provides all the necessary information to cardiologists or surgeons. Additionally, the ability to place 4D markers on different areas of interest simplifies discussions and communication among team members.

**Dr. Bina:** Communication is essential, particularly in cardiac surgery. Using these 4D markers allows us to achieve the desired anatomical position and function. It facilitates debriefing for each patient and significantly improves communication within the heart team.





**“** I find the technology astonishing. To fit this matrix into a tiny, flexible probe and make it usable in children as small as 5 kg is remarkable, all while maintaining excellent 2D image quality.”

**Besides 4D Markers, what other features available on the Vivid E95 ultrasound system are beneficial for your team?**

**Dr. Hadeed:** 4D Markers and FlexiSlice allow us to navigate 2D views within the 4D volume and create slices focused on areas of interest. These features help guide percutaneous interventions more effectively, enabling the most precise procedures.

**Dr. Karsenty:** The 4D probe enables bi-plane, tri-plane, and FlexiSlice imaging. These features are particularly useful, for instance, in bi-plane mode to confirm the exact position of an atrial or ventricular septal defect. FlexiSlice allows us to ensure that we are in the correct plane, perpendicular to a structure, and to take very precise measurements. These features are extremely helpful.

During catheterization, an interesting mode is dual cropping, which allows us to view both sides of the 4D image simultaneously. For example, when closing an atrial septal defect, we can see the left and right discs being positioned simultaneously in a single view. For complex procedures, 4D

imaging is highly valuable. In the case of a challenging ventricular septal defect, 4D imaging can precisely define its anatomy and size, enabling the selection of the most suitable device.

**Dr. Bina:** The advantages of these tools are immense. They allow us to make decisions immediately, reducing clamp time and extracorporeal circulation (ECC) time. Post-declamping, when evaluating the surgery, we find that in 90% of cases, the correction aligns with what we aimed to achieve, thanks to our collaboration with colleagues. This is incredible.

**What additional advantages do you see with the mini 4D TEE probe in percutaneous procedures?**

**Dr. Hadeed:** For guiding percutaneous interventions, 4D echocardiography allows detailed visualization of septal defects, the geometry of interatrial or interventricular communications, their precise location, and spatial relationships with other structures. This enables better guidance for choosing and positioning the device most appropriately. It likely reduces procedure time, radiation exposure, and the use of contrast agents, making it an essential tool for interventions.

**“** The advantages of these tools are immense. They allow us to make decisions immediately, reducing clamp time and extracorporeal circulation (ECC) time.”

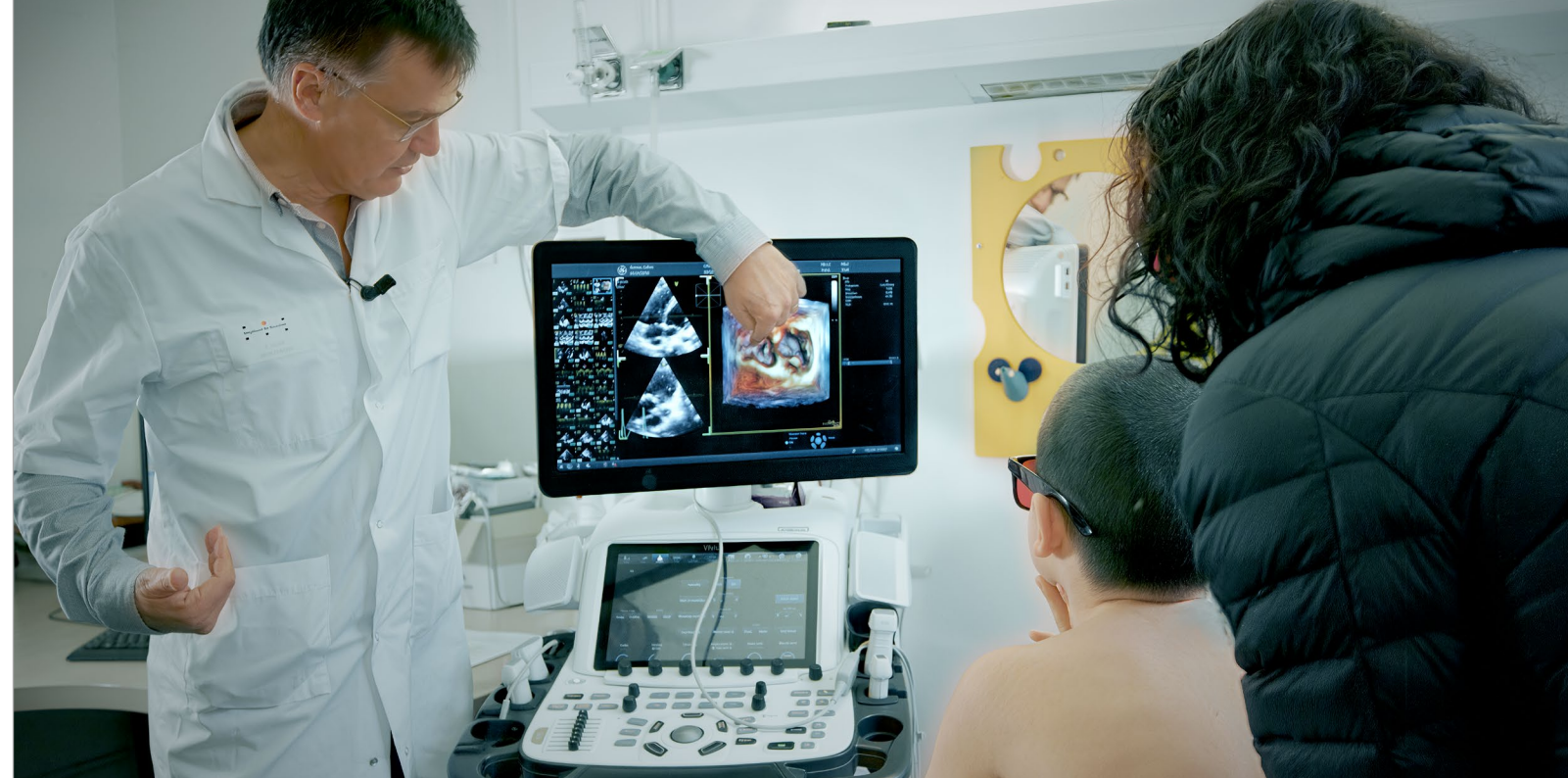**Did you encounter a learning curve with the mini 4D TEE probe?**

**Dr. Karsenty:** The Mini 4D probe is very easy to insert and use, so there is no real learning curve.

**Dr. Hadeed:** Using the mini 4D TEE probe is straightforward and similar to using any transesophageal probe in terms of insertion and manipulation. There is no significant learning curve. It's the same technique but with the added advantage of a third dimension, providing a more detailed view of congenital heart defects.

**“** It likely reduces procedure time, radiation exposure, and the use of contrast agents, making it an essential tool for interventions.”

**Dr. Bina:** There is a learning curve for the surgical team. In our workflow, decisions are primarily based on the surgeon's view. With the mini 4D TEE probe, we have additional perspectives, such as transatrial and transventricular views, both left and right. Initially, finding landmarks can be challenging. The learning curve typically lasts 1 to 2 months. However, reviewing many images with cardiologists helps immensely, and soon after, everything becomes much faster.



## 3D Glasses make CHD clearer for pediatric patients

Picture this: 3D glasses at the pediatric cardiologist's office—not the cinema. Physicians at University Hospital Toulouse are using the glasses to help families better understand CHD and what's happening inside their child's heart.

“Look, this is your heart in 3D. Focus mainly on the right, where it's orange. This is the mitral valve,” Prof. Philippe Acar directs 10 year-old Cylia to look at his latest scans. “You look really stylish in the glasses.”

Cylia was born with an arterial trunk and has undergone one Blalock surgery and an open-heart surgery with extracorporeal circulation over the last decade. The third grader has spent a lot of time in doctors' offices. His mother acknowledges there have been many long days.

Prof. Acar recognizes the emotional weight that comes with a CHD diagnosis and how it often turns a joyful time into one of fear and uncertainty. The glasses are just one part of the team's plan to ensure families are supported at every step. “You need to approach a diagnosis with pedagogy, humanity, and over multiple consultations. The entire diagnosis cannot be delivered abruptly or in one go, especially when the congenital heart disease is complex.”

Engaging young patients and parents is also important to Prof. Acar. The 3D glasses transform the clinical consultation into an interactive learning experience that's more meaningful for families. “It's a moment of sharing and exchange. You can't just stay in front of the screen. You have to share something using an image, in a face-to-face interaction.”

While some might dismiss the glasses as simple and fun, Cylia's family believes they point to something far more significant. The real importance lies in the 3D imaging they support—offering crucial, detailed views of Cylia's heart. “As parents of a child with congenital heart disease, we've learned a lot. The 3D technology is impressive,” his mother says. “For me, it's essential to know the facts clearly, without sugar-coating. It's important that the University Hospital of Toulouse remains at the forefront of innovation—otherwise, it complicates things for families like ours.”





**4D echocardiography is not yet standard in pediatric care. We understand that you are actively involved in global projects aimed at raising awareness and training medical teams on the advantages of this technology. What is at issue?**

**Prof. Acar:** *It ultimately comes down to the discretion of each team to decide whether or not to use 4D. It should be noted that most transthoracic probes today, and increasingly transesophageal probes as well, are now three-dimensional. So, the question is more about whether pediatric cardiology teams are adopting this new mode and engaging with them to promote this technique in all its facets—both the anatomical visualization aspect and the quantification aspect.*


**How do you envision the future of echocardiography in pediatric cardiology, and what impact do you think it will have on patient care in the coming years?**

**Prof. Acar:** *Regarding care, it's a bit challenging to define, as it remains ultrasound imaging—it's neither surgery nor catheterization. However, in all cases, it aids surgeons in better understanding and helps interventionalists guide their procedures. Ultimately, it's an operative and interventional support tool.*


*In my opinion, the applications are numerous. Certainly, they pertain to care, but they also extend to the realm of communication and education. For instance, with students and trainees,*

*we use it to explain intracardiac anatomy through 3D imaging—similar to what is done with CT scans, but here it's done with 3D ultrasound. Similarly, it enhances communication with patients and families, helping to explain concepts like an atrial septal defect using a 3D model.*

*We also have new systems that allow us to export 3D imaging for 3D printing. With these small 3D-printed models, we can represent and even touch the anatomy. Additionally, we have virtual reality systems with headsets that enable us to better visualize and understand intracardiac anatomy. ■*



**Philippe Acar, M.D., Ph.D.**, is a Professor of Pediatric Cardiology at Toulouse Children Hospital at Toulouse University. Prof. Acar has been an expert in 3D echocardiography for more than 20 years and was instrumental in developing the echo lab in 3D pediatric cardiac imaging at Toulouse. He's published more than 150 peer reviewed articles, mostly focused on 3D echocardiography. Prof Acar is Associate Editor of the Archive of Cardiovascular Diseases Journal and former president of the French Pediatric and Congenital Cardiology Association.



**Dr Clément Karsenty, M.D., Ph.D.**, is a pediatric and interventional cardiologist. He currently leads the pediatric cardiology department at the Children's Hospital in Toulouse, part of the Toulouse University Hospital. He has been actively involved in research on cardiac diseases, publishing numerous peer-reviewed articles that primarily focus on interventional catheterization, echocardiography, and congenital heart defects.



**Khaled Hadeed, M.D.**, is a pediatric cardiologist specializing in both diagnostic and interventional echocardiography. He is a hospital practitioner in pediatric cardiology at Toulouse University Hospital. Dr. Hadeed has published numerous scientific publications and is actively involved in research and teaching. His expertise focuses on advanced imaging of congenital heart diseases, with a particular interest in 3D echocardiography, percutaneous interventions in children, and 3D modeling and printing, which he uses for preoperative planning, education, and interventional guidance.



**Najeebullah Bina, M.D., Ph.D.**, is a senior pediatric and congenital cardiac surgeon at Toulouse Teaching Hospital. His expertise lies in leading cardiac surgery teams across various regions of the world and in establishing and developing cardiac surgery centers in Asia, as well as East and West Africa. Dr. Bina is the member of French and German Societies of Cardio-thoracic Surgery and an active member of the “Académie Nationale de Chirurgie” in France.

- 1 Bouma BJ, Mulder BJ. Changing landscape of congenital heart disease. *Circ Res* 2017;120:908–22.
- 2 Oscar J. Benavidez et.al. | Diagnostic Errors in Pediatric Echocardiography Development of Taxonomy and Identification of Risk Factors | <https://www.ahajournals.org/doi/full/10.1161/CIRCULATIONAHA.107.758532>
- 3 Karsenty C, Hadeed K, Pyra P, Guitarte A, Djedjai C, Vincent R, Dulac Y, Silagdze I, Gobin J, Combes N, Ratsimandresy M, Berthomieu L, Calvaruso D, Acar P. Advancing paediatric cardiac imaging: a comprehensive analysis of the feasibility and accuracy of a novel 3D paediatric transoesophageal probe. *Front Cardiovasc Med.* 2023 Dec 5;10:1294109. doi: 10.3389/fcvm.2023.1294109. PMID: 38116539; PMCID: PMC10728472.

9VT-D is exclusively available on Vivid E95 and Vivid E90 with the Ultra Edition release since August 2022.

The statements by Prof. Acar, Dr Karsenty, Dr. Hadeed and Dr. Bina are based on their own opinions and on results that were achieved in their unique setting. Since there is no “typical” hospital/clinical setting and many variables exist, i.e., hospital size, case mix, staff expertise, etc. there can be no guarantee that others will achieve the same results.

JB32342XX