



# Study Demonstrates Economic Value of SPECT/CT for PE Diagnosis

Ventilation/perfusion (V/Q) SPECT and V/Q SPECT/CT can play an important role in the evaluation of lung diseases such as pulmonary embolism (PE). Many studies have demonstrated the diagnostic accuracy (sensitivity and specificity) of SPECT and SPECT/CT for detecting acute PE.<sup>1-4</sup>

An August 2017 publication study examined the economic value of SPECT, SPECT/CT, planar NM and CTPA for PE diagnosis. The authors reported that SPECT/CT may be an economically favorable test for diagnostic workup of pulmonary embolus in the emergency department setting.<sup>5</sup>

“We concluded that V/Q SPECT in combination with low-dose CT without contrast enhancement has excellent diagnostic performance and should therefore be considered for first-line imaging in the work-up of PE,” says lead author Lauren K. Toney, MD, a nuclear medicine physician at Vantage Radiology (Auburn, WA), serving Valley Medical Center (Renton, WA) and MultiCare Auburn Medical Center (Auburn, WA).

The authors developed a simulation model that compared each imaging technique from a cost perspective. A literature review captured clinical endpoints, such as diagnosis, treatment, complication and mortality, and outcomes were measured based on total costs, excess costs and annual death rates.

According to Dr. Toney, the model included input parameters that were pooled from 81 previously published studies of patients evaluated for PE. Specifically among these, V/Q SPECT had a sensitivity of 97% and a specificity of 88%. When low-dose CT was added, the sensitivity was still 97% and the specificity increased to 100%. CT angiography alone had a sensitivity of 68% and a specificity of 100%.

Dr. Toney explains that in developing the study and building the economic model, which focused on evaluation of patients in the emergency department setting, it was important to include all costs and possible scenarios. Three scenarios were evaluated with the economic model encompassing treatment, alternative reimbursement models and a head-to-head comparison of SPECT/CT with CTPA.

The study reported that SPECT/CT had the lowest total annual cost at \$3.2 million, followed by SPECT at \$3.6 million,

CT pulmonary angiogram (CTPA) at \$3.8 million and planar NM V/Q scan at \$5.8 million. Potentially wasteful excess costs topped out at over \$3 million for planar NM, \$1.17 million for CTPA, \$617,311 for SPECT and \$182,293 for SPECT/CT.

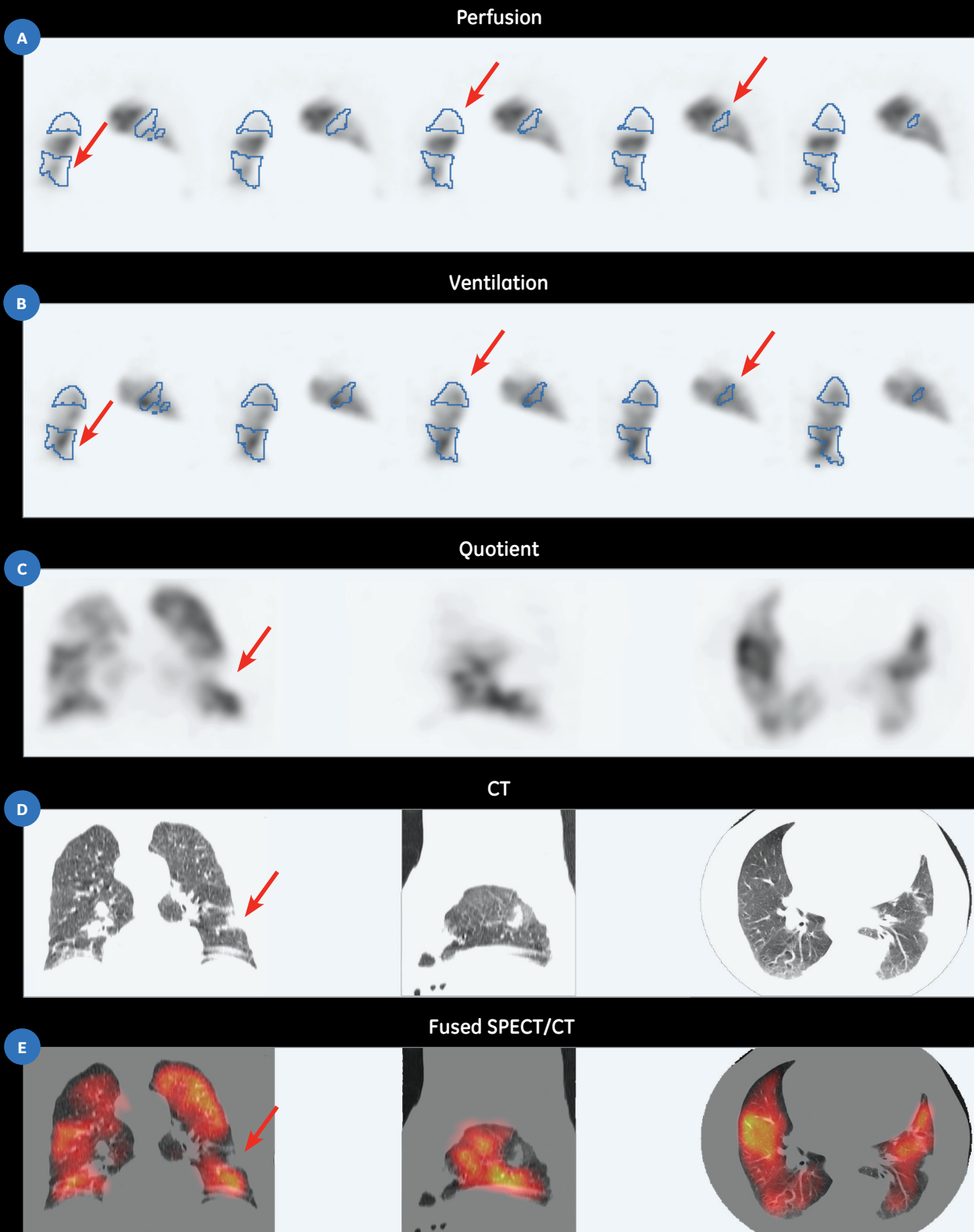
By switching to SPECT/CT, a hospital may realize per-patient-per-month cost savings of \$51.80 (vs. CTPA), \$213.80 (vs. planar NM), and \$36.30 (vs. SPECT), as well as save \$994,777 (vs. CTPA), \$2,852,014 (vs. planar NM), and \$435,038 (vs. SPECT) in “potentially avoidable” excess costs per annum for a payer or health plan. The overall economic burden of SPECT/CT for every 1,000 suspected PE patients was \$600,000 less than CTPA, \$400,000 less than SPECT and \$2.6 million less than planar NM.<sup>5</sup>

Initially, Dr. Toney and co-authors thought the economic model would hinge more on the different costs of the test itself. However, they found that the imaging test cost had less of an impact on the economic model than other factors, such as: the cost of managing a person suffering from renal failure associated with contrast media use; not treating a person who was missed by the test; or not picking up the PE in the first diagnostic evaluation.

“No imaging test is a perfect yes or no,” Dr. Toney says. “While uncommon, the impact of an inconclusive test or missed diagnosis is tremendous, not only to the patient but also the health system. These scenarios have a high economic burden and are a driving force in the model.”

Another key point that can be derived from the study is that patients sent to the nuclear medicine department for a V/Q scan—whether there is a contraindication for CTPA or based on the institutions’ protocol and clinical pathway—could be imaged with SPECT instead of planar NM. Dr. Toney refers to the significant potential cost savings for utilizing SPECT V/Q over CTPA and also notes that a SPECT camera can acquire the study in the same or less time than planar NM with the added benefit of generating additional imaging data.

The study also supports that SPECT V/Q (without non-contrast CT) is an economically favorable test for investigating PE in the emergency setting. Dr. Toney explains, “SPECT has high accuracy for PE and would be useful if this was the primary



**Figure 1.** (A, B, C) SPECT V/Q images; (D) CT images; (E) Fused SPECT/CT V/Q. Mismatch of total volume is 21%.

Case courtesy of Concord Repatriation Hospital, Sydney Australia.



## Patient History

A 64-year-old male with recent tachycardia, and fever in context of recent surgery and immobilization.

## Acquisition

### SPECT

1.08 mCi of <sup>99m</sup>Tc Technegas

20 sec/step, 6 degrees/step

12 min SPECT

5.9 mCi of <sup>99m</sup>Tc MAA

15 sec/step, 10 min SPECT

### CT

120 kV

50-100 mAs

0.8 sec rotation (free breathing)

ASiR™ 50%

## Findings

### SPECT

Multiple bilateral PE involving 30-35% of the lung segments (21% of total volume), while the remainder of the segmental perfusion defects are mismatched, there is a partly matched segmental perfusion defect in the lateral basal segment of the left lower lobe.

### CT

The partly matched segmental perfusion defect in the lateral basal segment of the left lower lobe is associated with CT change (indicative of infarct).

diagnostic consideration. However, a patient may have other pulmonary issues, which would be difficult to assess without CT. Therefore, although SPECT alone can usually provide a yes or no answer regarding PE, it is possible that further testing would be needed if other diagnoses were considered."

Utilizing SPECT or SPECT/CT for suspected PE cases also opens the door to discussion with emergency department colleagues who are also under pressure to reduce costs. "We work closely with our emergency physician colleagues on a number of issues, and having this discussion in a meeting, face-to-face, is the best place to start," Dr. Toney explains. "Some ER doctors, while very familiar with the planar NM V/Q scan, may not have familiarity with SPECT or SPECT/CT. Showing them a few cases is a great way to begin this discussion."

An important metric is each institution's emergency patient population and workflow. Dr. Toney recalls a few published articles exploring the use of SPECT/CT V/Q exams in less than 30 minutes. While a CTPA exam may be shorter, the sensitivity and specificity of SPECT V/Q, and its economic advantage, should lead institutions to take a closer look. If staffing NM technologists is an issue in evenings and weekends, Dr. Toney recommends that sites look to utilize SPECT or SPECT/CT V/Q during weekdays and use CT during off-hours for suspected PE cases.

There are also several ways that hospital administrators can utilize the data in this study, and any changes in patient pathways will be incumbent on the type of equipment and

staffing at the facility. For example, a radiology department with a modern SPECT/CT and 24x7 radiology staffing may be well suited to first utilize SPECT/CT for patients with suspected PE. For facilities that don't have SPECT/CT, this data could support a discussion on equipment acquisition.

Today, many patients have complex medical issues making diagnosis not as simple as in years past. Imaging is also well integrated into the patient clinical work-up.

"No one wants to miss a diagnosis," Dr. Toney says. "In medicine, we are constantly recalibrating what is the right test at the right time for the right patient. Economic studies could play an increasing role in deciding how and when to image a patient."

Her recommendation to other institutions is to take a closer look at SPECT or SPECT/CT for certain patient population, such as suspected PE. She adds, "SPECT is a very valuable tool. Once the protocol is set up properly the imaging can be done fairly quickly." ■

### References

1. Milà M, Bechini J, Vázquez A, et al. Acute pulmonary embolism detection with ventilation/perfusion SPECT combined with full dose CT: What is the best option? *Rev Esp Med Nucl Imagen Mol.* 2017 May - Jun; 36(3):139-145.
2. Bajc M, Jonson B. Ventilation/Perfusion SPECT for Diagnosis of Pulmonary Embolism and Other Diseases. *Int J Mol Imaging.* 2011; 2011: 682949. Published online 2010 Dec 19. doi: 10.1155/2011/682949.
3. Bajc M, Olsson CG, Olsson B, Palmer J, Jonson B. Diagnostic evaluation of planar and tomographic ventilation/perfusion lung images in patients with suspected pulmonary emboli. *Clin Physiol Funct Imaging.* 2004; 24:249-256.
4. Mortensen J, Gutte H. SPECT/CT and pulmonary embolism. *Eur J Nucl Med Mol Imaging.* 2014; 41 (Suppl 1):S81-S90.
5. Toney LK, Kim RD, Palli SR. The Economic Value of Hybrid Single-photon Emission Computed Tomography With Computed Tomography Imaging in Pulmonary Embolism Diagnosis *Acad Emerg Med.* 2017 Sep;24(9):1110-1123. doi: 10.1111/acem.13247. Epub 2017 Aug 14.