

Optimized clinical pathway

propels high utilization of PET/MR at Pitié-Salpêtrière Hospital

As one of Europe's largest teaching hospitals, Pitié-Salpêtrière Hospital is renowned for its innovative research and delivery of high-quality care to patients. In 2015, the Alzheimer Research Foundation in France, a partnership between the public hospital system and the University Hospital Brain and Spine Institute (IHU-A-ICM), provided funding for a PET/MR project at the hospital.

According to Aurelie Kas, MD, PhD, Head of the Department of Nuclear Medicine at Pitié-Salpêtrière Hospital Group, the utilization of the SIGNA™ PET/MR is equally divided between clinical and research use, with 2.5 days a week dedicated to each. The institution is currently participating in 45 clinical trials in oncology and neurology.

"In our experience, PET/MR imaging is feasible in a clinical setting with a throughput of 11 to 15 patients each day," Professor Kas says.

The hospital conducts a staggering high volume of clinical PET/MR exams. SIGNA PET/MR complements a robust imaging environment in the nuclear medicine department that includes two PET/CT systems, two SPECT/CT systems and one ultrasound system. The department also provides radioactive iodine therapy for thyroid cancer patients with six beds that accommodate 12 patients each week. Six MR systems are also located in the radiology department primarily for neurology, oncology and cardiac imaging.

The clinical PET/MR service is a collaboration between the nuclear medicine and radiology departments. Professor Kas explains that in addition to radiology, the PET/MR implementation has further promoted the development of new collaborations with neurology, neuro-oncology, urology, gynecology and surgery.

At Pitié-Salpêtrière Hospital, patients with brain tumors, rare cancers and rare neurodegenerative disorders, such as atypical presentation of Alzheimer's

Neuro Case 1

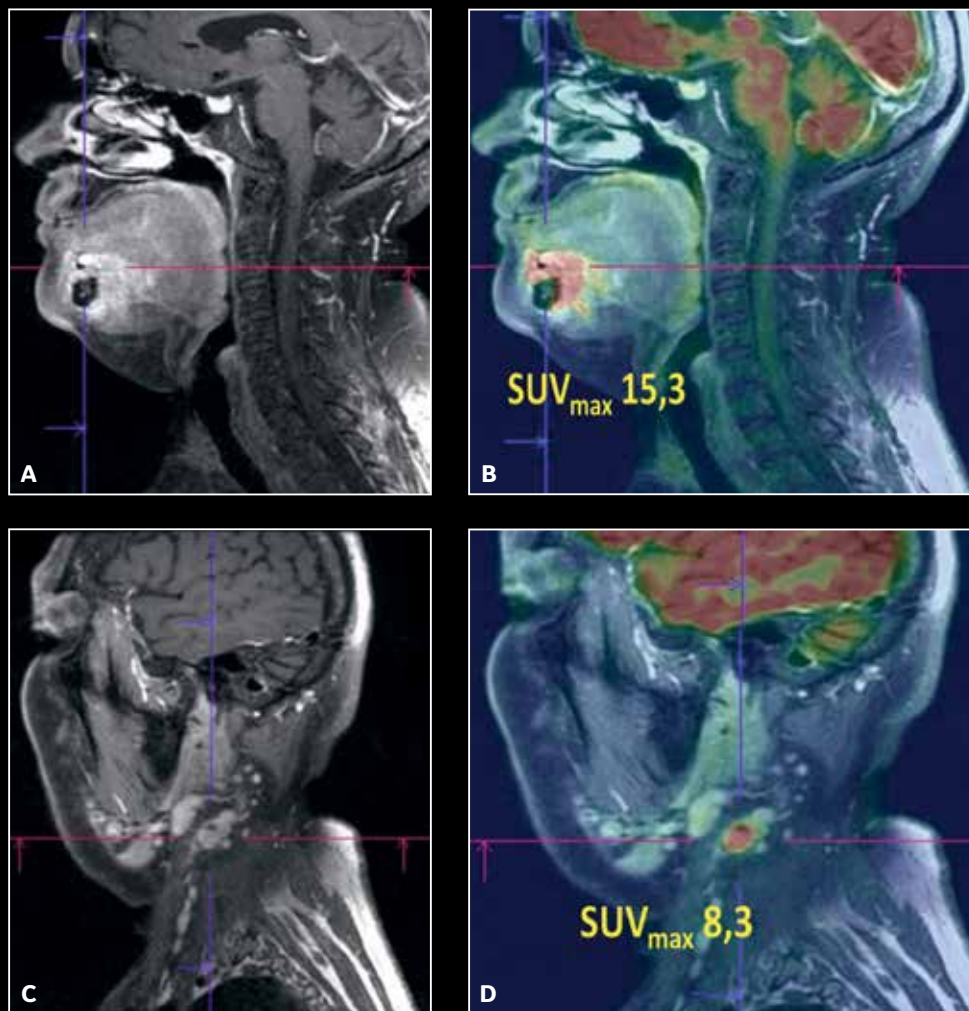


Figure 1. Pre-surgical assessment of a mandibular gingiva squamous cell carcinoma with FDG PET/MR imaging. MR findings: mandibular gingiva lesion with trabecular bone invasion, left necrotic lymph node. PET findings: hypermetabolism of the lesion and the left lymph node. Pathology confirms PET/MR findings.

disease (AD), are now preferably referred to PET/MR rather than PET/CT or MR alone to obtain detailed images to aid in the detection, localization and diagnosis of diseases and disorders. Clinically, 75% of PET/MR imaging studies are for neurodegenerative disorders such as Alzheimer's and Parkinsonism, 23% for oncology (approximately 33% neuro, 34% maxillofacial and 33% abdominal/pelvic) and 2% for drug-resistant partial epilepsy.

“We believe the diagnostic accuracy may be improved by combining metabolic information provided by PET with the structural and multi-parametric imaging of MR. This is especially helpful in the areas of neurodegenerative disorders with atypical presentation or vascular comorbidities, for the diagnosis of cancer recurrence and for tumor delineation before surgery in regions with complex anatomy.”

Professor Aurelie Kas

Neuro Case 2

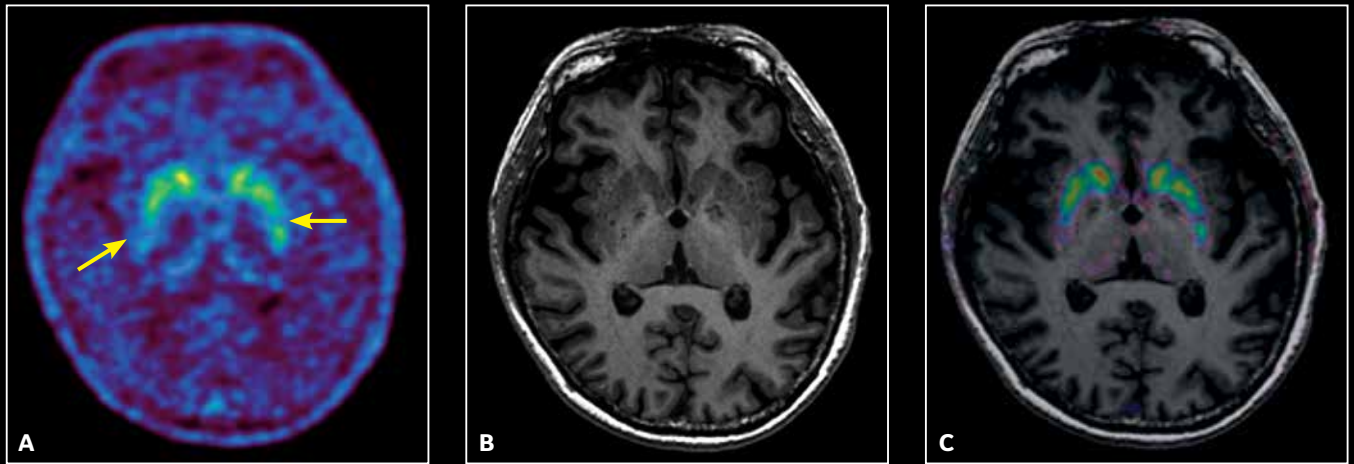


Figure 2. Dopaminergic exploration for suspicion of Parkinson's disease with 182 MBq ^{18}F -DOPA, post 85 min uptake with an acquisition of 25 min. (A) Axial PET, (B) Axial MR T1w and (C) fused PET/MR.

“In our facility, our research has found that PET imaging provides early biomarkers of many neurodegenerative disorders, but MR provides unique imaging information on age-related or pathological cerebral atrophy, vascular lesions such as stroke sequelae, microbleeds and leukopathy, and inflammatory abnormalities that cannot be reliably assessed with PET alone. In addition, using PET/MR image interpretation and comparing imaging biomarkers is optimal since the imaging studies are acquired simultaneously.”

Diagnostic power of PET/MR

In complex neurology and oncology cases requiring PET imaging, PET/MR is now preferred rather than PET/CT at Pitié-Salpêtrière Hospital. This is especially important if MR imaging is also indicated.

Professor Kas explains, “We utilize PET/MR for visualization of advanced head and neck cancers to assist with the assessment of disease status and, more specifically, to help with tumor

delineation before surgery in this region with such complex anatomy. In follow-up examinations, hybrid PET/MR has advantages in the visualization of tumor differentiation, scars and edema after radiation therapy in head and neck cancer. It is also of great interest in brain tumors when MR images alone may not enable us to differentiate the viable tumor from necrosis with post-therapeutic changes, especially after radiation therapy.

“Hybrid PET/MR is also a helpful imaging tool in cases of atypical presentation or early-onset AD, Parkinson's-plus syndromes and suspected mixed dementia when neurodegenerative and vascular processes coexist,” Professor Kas adds.

Prior to implementation of the SIGNA PET/MR, patients with complex indications in which PET and MR were both recommended often underwent two imaging exams. Now, a single imaging exam—PET/MR—can assist us in directly answering the clinical question.

“Our patients benefit with less examination time and an increase in comfort, especially the older patients with comorbidities.”

Professor Aurelie Kas

She adds, “Clinicians gain the advantage of a reliable imaging exam with increased diagnostic confidence as the combination of these imaging tools aid in accumulating evidence for a specific diagnosis. Additional gains in diagnostic accuracy can be achieved since PET/MR studies are interpreted by experts in both radiology and nuclear medicine, who together provide a single report.”

Since October 2015, more than 2,000 patients have undergone clinical PET/MR examinations in the facility. The department averages 11-15 clinical patients each day from 8 am to 5:30 pm, of which three to five exams are whole body and eight to 10 are brain exams.

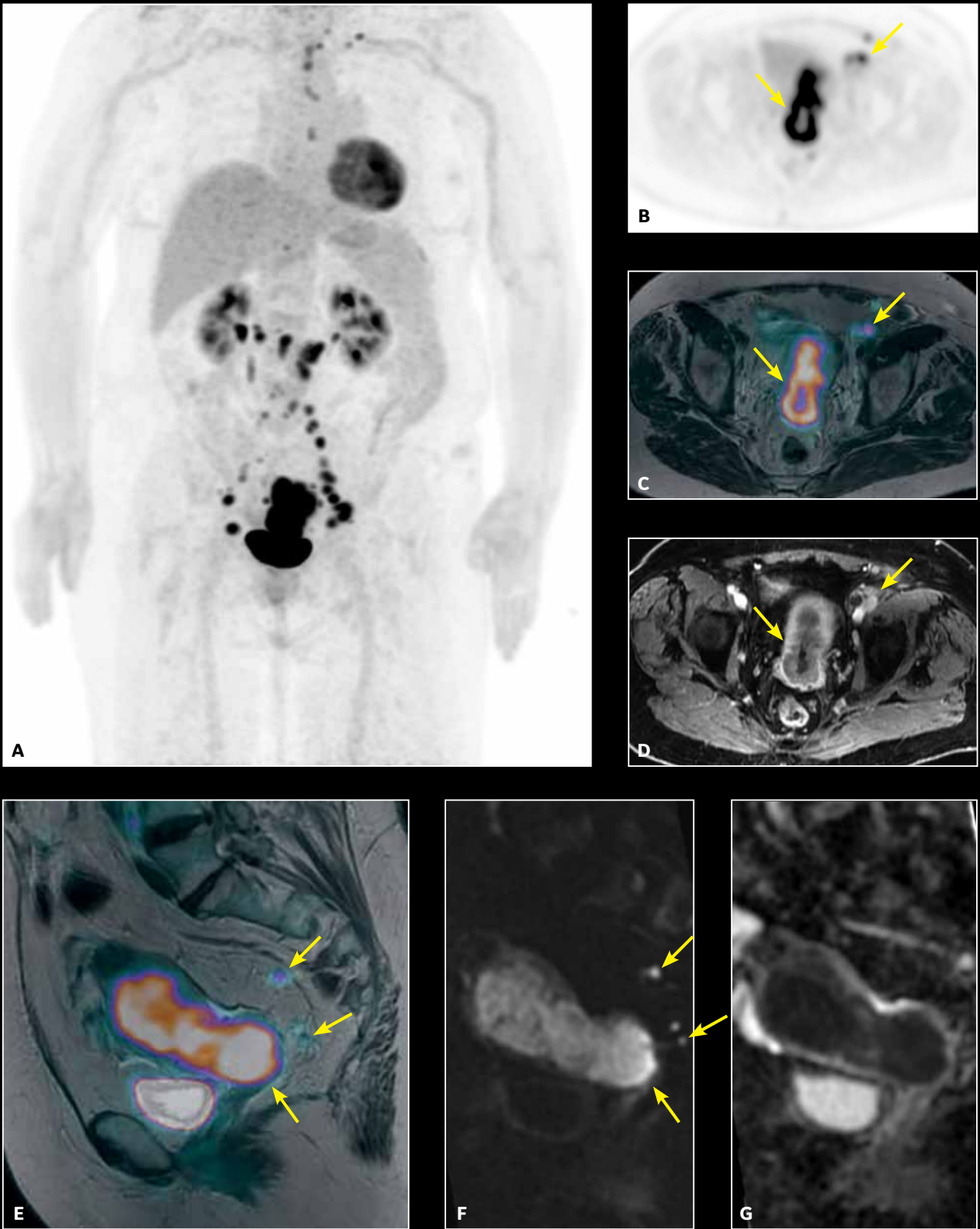


Figure 3. Pelvic MR exam on a patient with endometrial adenocarcinoma. (A) Whole-body PET, 4 bed positions at 3 min/bed; (B) pelvic PET acquired in 16 min; (C) fused PET with Axial T2w PROPELLER; (D) Axial T1w LAVA post-contrast; (E) fused PET with Sagittal T2w PROPELLER; (F) Sagittal FOCUS DWI, b1000; (G) ADC map.

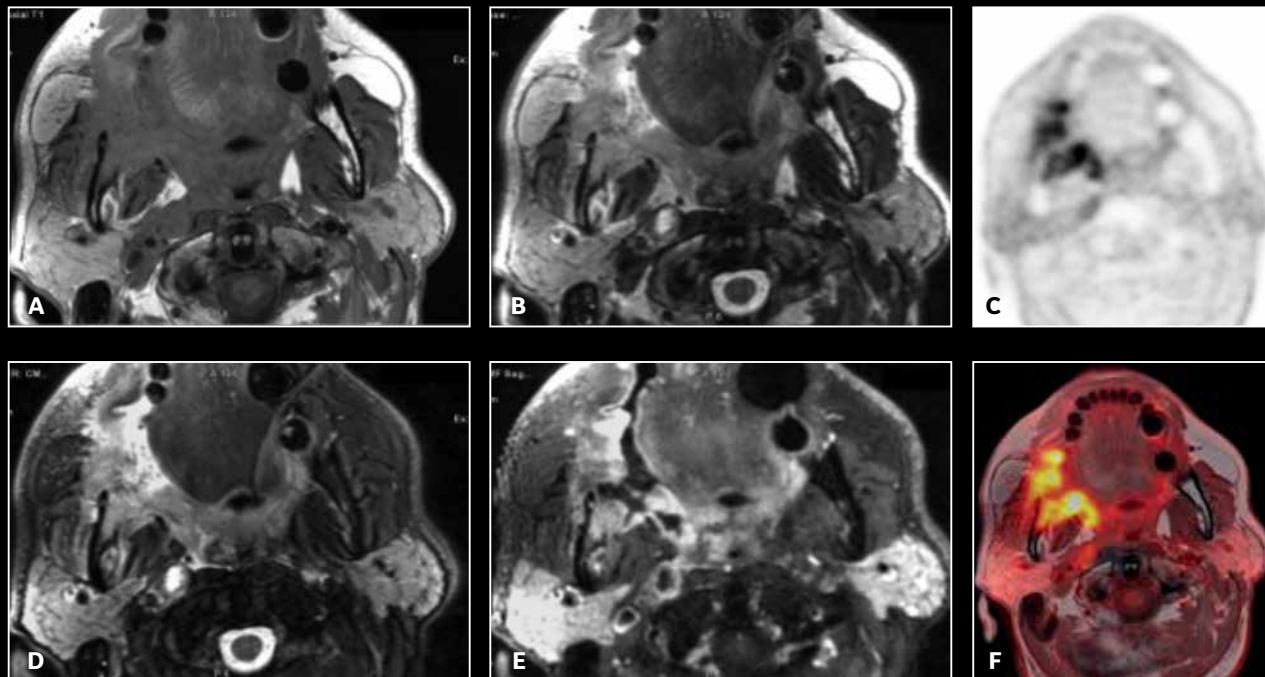


Figure 4. PET/MR exam of a squamous cell carcinoma of the right intermaxillary commissure. PET/MR enables precise tumor delineation for pre-surgical planning.

At Pitié-Salpêtrière Hospital, the typical protocol for neurodegenerative disorders averages 25 minutes. For oncology, it is slightly longer at a median of 45 minutes which also includes a regional multi-modal exam—for example one bed position on the neck or pancreatic area—and a whole-body PET. Often, ^{18}F -DOPA PET/MR exams for brain tumors or atypical Parkinsonism syndrome indications last 45 minutes.

Optimizing the clinical pathway

To maximize clinical utilization and benefit of the PET/MR system in as many patients as possible, Professor Kas and her colleagues in nuclear medicine and radiology focused on optimizing the clinical pathway. One of the first steps was to start using the system in well-defined areas of MR

imaging expertise, such as head and neck, digestive and pelvis, with very specific indications for each organ or anatomic area being examined.

The PET/MR imaging service was organized with a dedicated staff that includes four trained technologists with prior experience in MR, six physicians, two physicists and one administrative support position. The unit was designed with the PET/MR exam room, reading room and patient preparation room in close proximity to facilitate communication between technologists and clinicians in order to help reduce time between exams and enhance patient safety and satisfaction.

All acquisition protocols were evaluated and optimized by experts in nuclear medicine and radiology to avoid the collection of redundant information

by the two imaging modalities and to ensure that protocols obtained all the required information for diagnosis. They also collaborated to determine the minimal scanner occupancy times to maximize clinical utilization since the scanner would be used only 50% for clinical applications. Regularly scheduled meetings were held with all PET/MR medical staff to review patient flow, optimize MR sequences and discuss any potential issues. Today, the PET/MR team regularly holds multi-disciplinary meetings to discuss the contribution of PET/MR imaging to help clinicians diagnose complex cases.

“Efforts have been made to optimize the imaging protocol to maintain short PET/MR acquisition times to ensure that we can acquire more than 11 clinical imaging studies in one day. On the other hand, it was obvious to us that the protocol had to achieve the highest diagnostic capability to provide at least as much information as sequential PET/CT and MR examinations.”

Professor Aurelie Kas

Therefore scan times are balanced between the desire for shorter acquisition times and high-quality imaging. While the hospital's current acquisition protocols typically last 25 minutes for a neuro protocol and up to 50 minutes for exams that include whole-body PET for oncology, Professor Kas is currently working on new ways to further reduce scan times.

La Pitié looking forward

One area of research that Professor Kas and her colleagues plan to investigate is to study the added value of combined PET/MR biomarker imaging. Specifically, Professor Kas and her colleagues will examine the diagnosis of neurodegenerative disease and brain tumors and the prognosis and evaluation of therapeutic response in cancer patients.

The group is also examining the reliability of Zero Echo Time (ZTE) based attenuation correction (AC) for brain, head and neck PET/MR images. Currently, AC techniques in these anatomic areas are based on a CT atlas and the Dixon sequence to identify air, water and soft tissue. This approach, explains Professor Kas, is not always satisfactory for the AC of bony regions, especially in patients with a cancer of the jaw or a tumor extending to the base of the skull. The first results are encouraging, she adds, and suggests that ZTE sequences enable bone visualization and are appropriate for AC of the oral cavity.

Overall, the utilization of PET/MR in a dual clinical and research environment has been successful. Professor Kas says, “It is important to optimize imaging protocols to ensure complementary imaging data and avoid redundant information between these modalities.” **S**