

# Innova\* 4100<sup>IQ</sup>

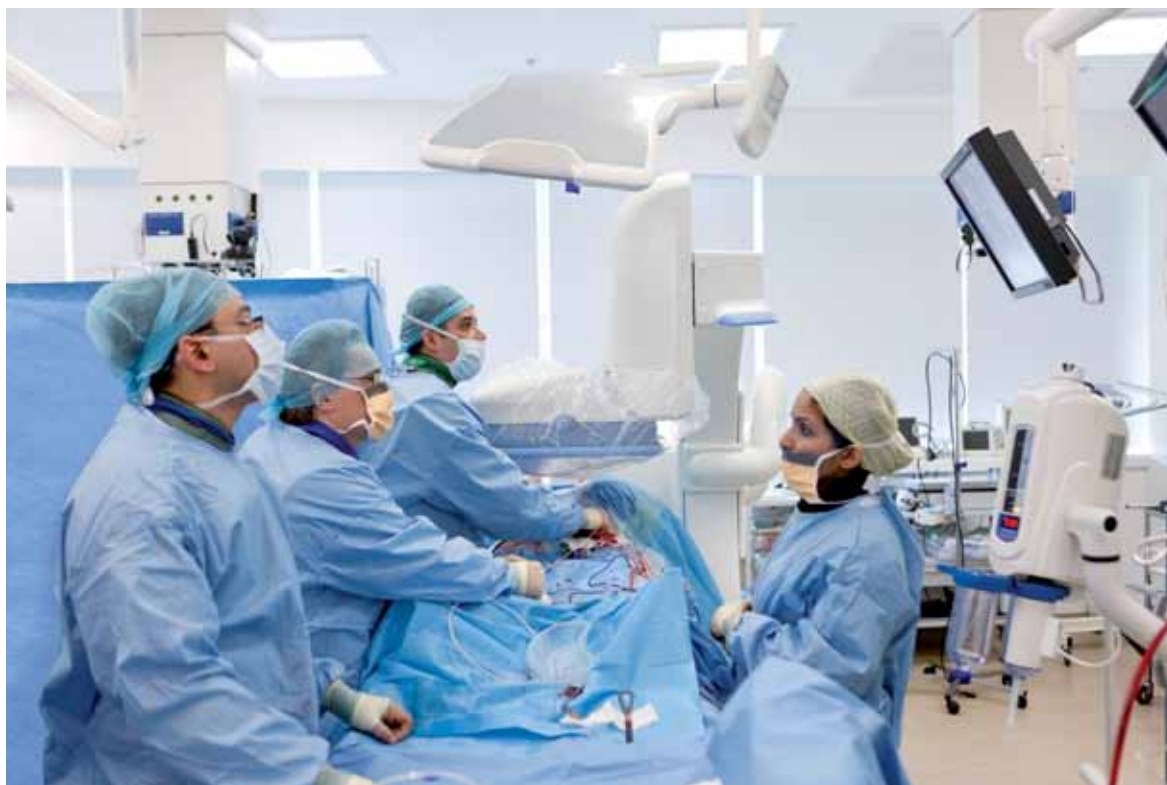Clinical benefits for complex EVAR procedures performed in an OR environment

**Interview with Pr. Krassi Ivancev, MD, PhD  
University College London Hospitals (UCLH),  
London, UK**

The University College London (UCL) is part of one of the largest NHS trusts in the United Kingdom. Its vascular service has a major emphasis on endovascular treatments, strengthened by a multidisciplinary endovascular team comprising vascular and cardiothoracic surgeons, interventional radiologists and neuro-radiologists. The vascular service each year treats about

80 patients with aortic aneurysms and 600 to 700 more across the full range of vascular procedures.

Professor Ivancev is an internationally recognised specialist in endovascular treatments and shares his experience of more than two years using the Innova 4100<sup>IQ</sup> during complex EVAR procedures.



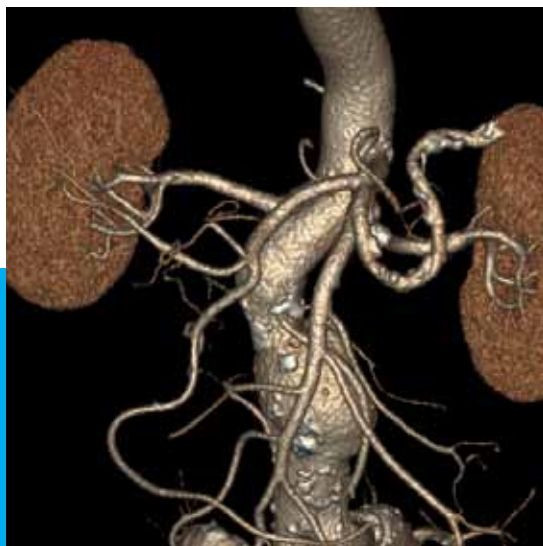

**As a specialist in endovascular complex procedures, with so many studies published on aortic aneurysm treatment, can you tell us what has changed in your daily practice, as a result of advanced imaging technologies?**

Today, endovascular treatment of complex aortic aneurysms could not exist without advanced imaging technologies. Pre-operative CTA and intra-operative advanced imaging capabilities, help us identify and map the aneurysms providing precise anatomical information. We can now collect comprehensive information - not only the size of the aneurysm as in the past but also more precise data on the tortuosity and anatomical details of the arteries (cf. *figure 1*). These findings are crucial for a successful endovascular treatment.

It is essential to begin with a pre-operative CT-scan to obtain sufficiently accurate information in order to set up the correct procedure plan.

Next, during the procedure, modern technology lets us benefit from three-dimensional (3D) information through pre-operative CT or intra-operative C-arm CT acquisitions. These methods have many advantages in terms of deploying the stent graft in the correct position, catheterizing the branch vessels, and placing the bridging stents.



**Figure 1:** Pre-operative CTA showing anatomical details of the aneurysm and the branched vessels.

**You are currently using an Innova 4100<sup>IQ</sup> system with 3D and advanced multimodality capabilities. How does the equipment help you to face daily clinical challenges?**

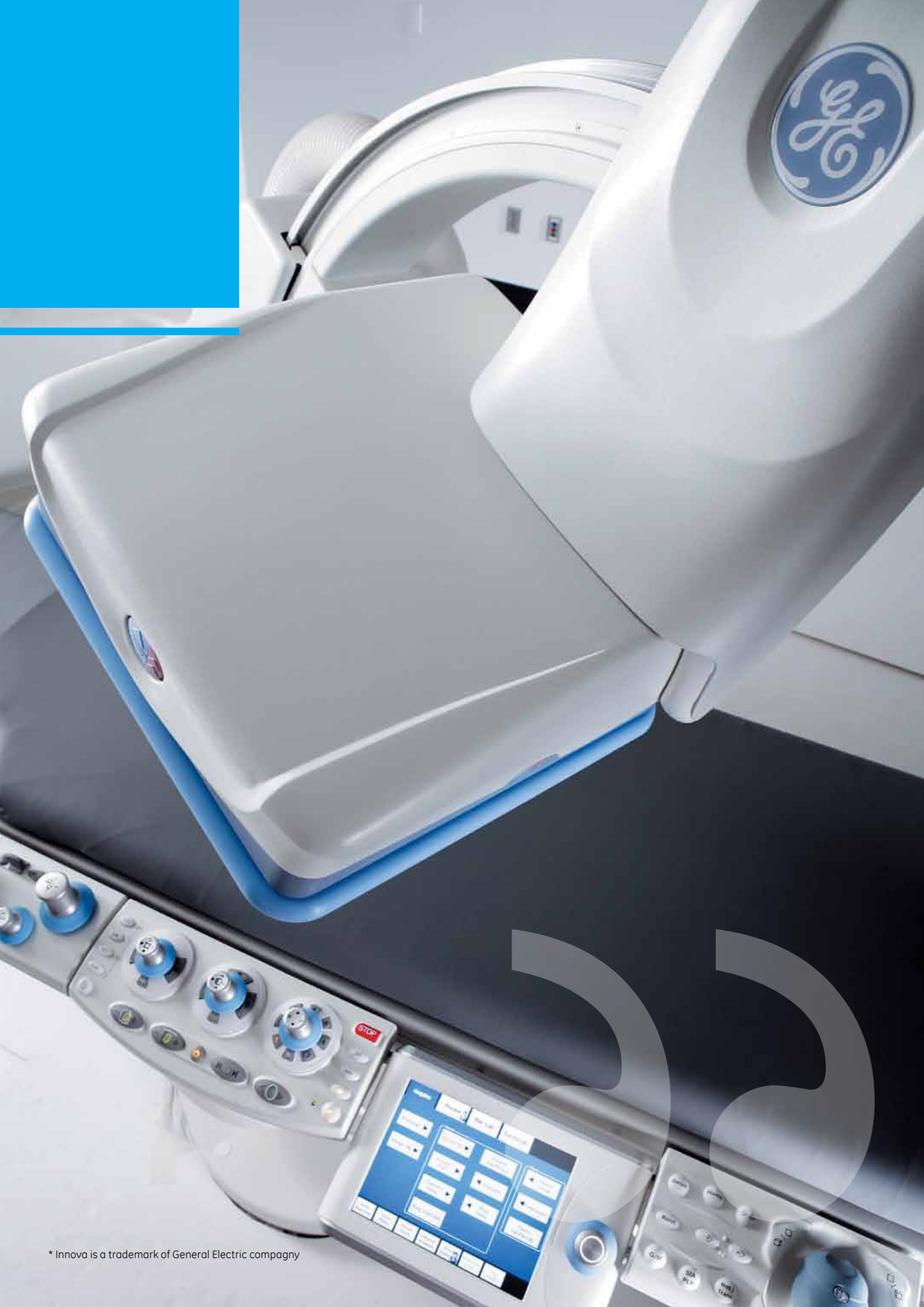Imaging systems used during complex endovascular aneurysm repair (EVAR) procedures help us understand the vascular anatomy, to precisely visualize branch vessels such as the renal arteries and visualize with certainty the position and orientation of the devices including the stent graft.

One of the problems we face is the distortion of vessels during an intervention. This happens mainly as the stent graft, which is a rigid device, is inserted into the aorta and crosses its tortuous path. Such distortion can be predicted to a certain extent based on a pre-operative CTA, but can never be as accurate as intra-operative imaging with the stent graft in place.

The imaging system has to allow us to assess all this information while minimizing the quantity of contrast media injected.

With that in mind, I am constantly using the Innova's three-dimensional capabilities to understand the vessel anatomy and the position of the devices.

- To begin with, the simplest technique is to use the antero posterior and lateral views which are easy to acquire thanks to the manoeuvrability of the Innova C-arm.
- Another very simple technique is to use catheters as landmarks that one can place in vessels of interest such as the renal artery before the endograft placement.
- Then, when the stent graft is in place, we can acquire antero-posterior and lateral images or a C-arm CT image without contrast media to visualize the position and orientation of the endograft with respect to the landmarked vessel (cf. *figure 2*).
- In addition, one of the great advantages of the Innova system is its ability to reduce the need for contrast media by registering images from a pre-operative CTA with the intra-operative C-arm CT using bony landmarks. The pre-operative CT is registered to the current position of the patient and can then be overlaid on the fluoro live images to combine the 3D vascular information from the CT with the current live image of the Innova 4100<sup>IQ</sup> (cf. *figure 3*).



\* Innova is a trademark of General Electric company

### Do you think that Innova 4100<sup>IQ</sup> with 3D capabilities offers the possibility to manage more complex cases?

The answer is yes. To catheterise small blood vessels without damaging them, it is critical to see perfectly what you are doing. Image quality is essential. The Innova 4100<sup>IQ</sup> system provides very high quality images, and a precise 3D spatial orientation, with reasonable doses of radiation.

The Innova 3D images show changes in the vessels shape due to the insertion of the stent graft that are especially important in tortuous vessels. This information enables the operator to adjust the pre-operative plan.

Accurate positioning of the fenestrated stent graft involves not only up and down and left to right positioning but also an appropriate rotation to properly orientate the fenestrations. The 3D capabilities of the Innova 4100<sup>IQ</sup> system can tell one where the branch vessels are. The advantage is mainly in the ability to catheterise not just any branch vessel, but preferably the one that is the most difficult to catheterise from the fenestration. If the fenestration corresponding to this particular target vessel is properly positioned based on the Innova 3D images, that position should be appropriate for the rest of the procedure.

Before the introduction of CTA and intra-operative 3D capabilities, all that I have described was based on extensive experience. That experience, of course, included failures. The Innova 3D capabilities

make it possible to avoid mistakes by immediately showing images that provide key information and illustrate anatomic arrangements.

### Why did you choose a floor-mounted Innova system to install in your OR environment?

When stent grafting is performed, it is essential, even crucial, to maintain sterility as high as possible. For me, sterility is the main reason to choose a floor-mounted system.

It is much easier to maintain sterile conditions with a floor-mounted gantry than with a ceiling-mounted system. Actually, with a ceiling-mounted system there is a potential risk of dust or other particles falling from the suspension.

### Briefly, can you tell us about the types of patients treated in your facility and the latest associated treatment techniques?

Here, in the multidisciplinary endovascular facility of the University College London Hospitals, we perform procedures using cutting-edge techniques that are new to the medical community and enable us to do cases that have never yet been done before.

We perform one or two complex EVARs every week. We rarely see double fenestrations or straight infra-renal stent

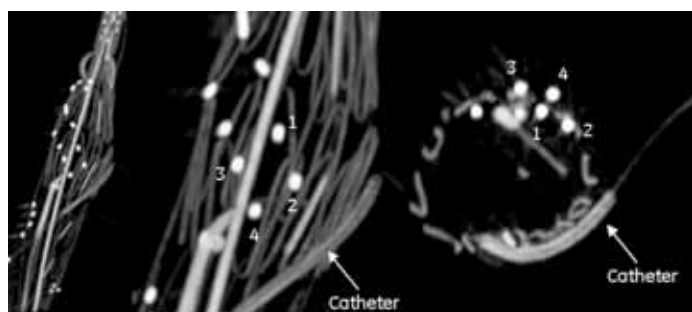


Pr. Krassi Ivancev

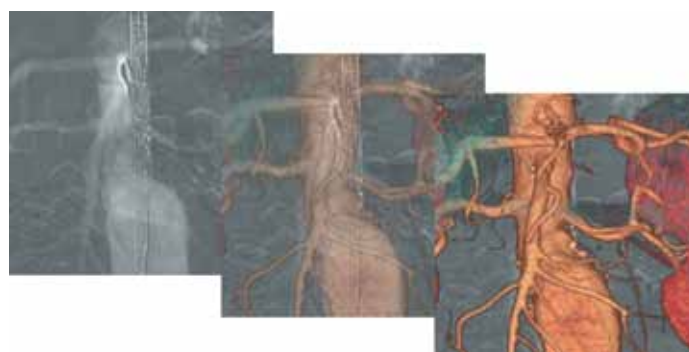
grafts as they are not treated here.

We treat nearly exclusively juxta-renal or para-renal aortic aneurysms with triple fenestration, or thoraco-abdominal aneurysms that require branched stent grafts with or without fenestrations. We have already done about 80 complex EVAR cases.

These cases are very challenging and may require up to six hours of intervention while an infra-renal aortic stent graft procedure can be as quick as 45 minutes.



**Figure 2:** C-arm CT acquisition. The catheter placed in the renal artery is used as a landmark to localize the position of the vessel ostia. The image shows that the endograft orientation needs to be modified to align the fenestration markers (1,2,3,4) with the ostia of the renal artery.



**Figure 3:** InnovaVision image showing pre-operative CTA images overlaid on top of the fluoroscopy image with different levels of transparency.

\* Innova is a trademark of General Electric company

### Can you illustrate how advanced imaging capabilities can contribute to improved patients follow-up?

A rotational C-arm CT acquired at the end of the procedure can be used as a control that may replace the follow-up CTA. If this control demonstrates the treatment has been effective, there is no need to image the patient within the next 12 months.

Essentially, the new technology of the Innova system has the potential to minimize the need for follow-up (cf. figure 4).

### Based on both your knowledge of innovations and your everyday practice, what do you think is the future of endovascular techniques?

I think that in the immediate future the advanced imaging technologies, as they simplify the procedures, will contribute to the increased usage of stent grafts. They will allow more operators to perform more complex procedures.

Stent grafts will also keep growing because they present several advantages. First, the procedure is less traumatic than open surgery. Another big advantage is that the endovascular approach uses digital techniques that simplify procedure planning. Not only is it possible to plan the intervention before it starts but the new Innova system with intra-operative 3D techniques also helps the operator to correct the plan during the intervention.

On the other hand, open surgery cannot really be planned.

Once the surgeon makes an incision and is inside the body, most of the time he must improvise.

In terms of clinical trends, I don't think that it is possible to return to open surgery.

### Have these new modalities changed the profile of endovascular specialists' profession?

First of all, I want to make it clear that the endovascular specialty combines many different areas of medicine.

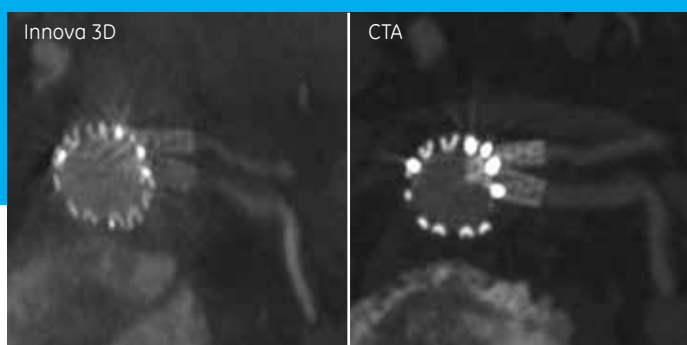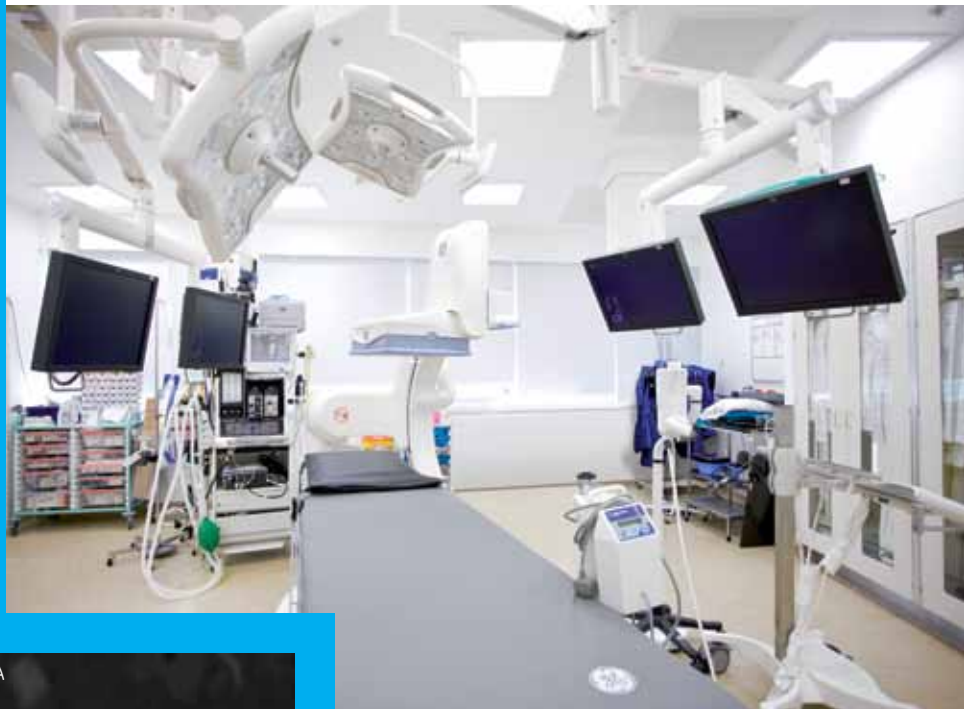An endovascular specialist can be a vascular surgeon, a radiologist, a cardiologist, or a cardiac surgeon.

On top of this, he or she must be

qualified to solve problems that may occur during endovascular procedures.

The capabilities offered by the new technologies have clearly changed the profile of my profession - I would say the profession has considerably progressed. Since I first started, I have performed every type of endovascular procedure, even the most complex ones. Now, I dedicate my time to teach other doctors how to use these techniques. The new imaging techniques make it easier for me to teach other operators, because I can guide them by showing what to do.

It considerably shortens the learning curve because this information, which is based on imaging, is much easier to transfer than a manual technique such as in an open surgery.



**Figure 4:** Innova 3D image performed at the end of the procedure that demonstrates the patency of the renal arteries. The follow up CTA confirmed that information.



Data subject to change.  
Marketing Communications GE Medical Systems  
Société en Commandite Simple au capital de 63.875.865 Euros  
RCS Versailles B 315 013 359  
A General Electric company, doing business as GE Healthcare  
GE is a trademark of General Electric Company.

\*Trademark of General Electric Company.

France - Buc  
Tel: +33 (0)1 30 70 40 40  
Vélizy  
Tel: +33 (0)1 34 49 50 00

Germany - Solingen  
Tel: +49 (0)21 228 020

Italy - Milan  
Tel: +39 02 260 01111

Spain - Madrid  
Tel: +34 91 663 2500

Turkey - Istanbul  
Tel: +90 212 36 62 900

UK - Slough  
Tel: +44 1 75 387 4000

## About GE Healthcare

GE Healthcare provides transformational medical technologies and services that are shaping a new age of patient care. Our broad expertise in medical imaging and information technologies, medical diagnostics, patient monitoring systems, drug discovery, biopharmaceutical manufacturing technologies, performance improvement and performance solutions services help our customers to deliver better care to more people around the world at a lower cost. In addition, we partner with healthcare leaders, striving to leverage the global policy change necessary to implement a successful shift to sustainable healthcare systems.

Our “healthymagination” vision for the future invites the world to join us on our journey as we continuously develop innovations focused on reducing costs, increasing access and improving quality around the world.

Headquartered in the United Kingdom, GE Healthcare is a unit of General Electric Company (NYSE: GE). Worldwide, GE Healthcare employees are committed to serving healthcare professionals and their patients in more than 100 countries. For more information about GE Healthcare, visit our website at [www.gehealthcare.com](http://www.gehealthcare.com).

GE Healthcare  
Chalfont St.Giles,  
Buckinghamshire,  
UK



GE imagination at work