

ViewPoint 6

GE Healthcare



Requesting Provider:
Brandon Edwards, MD
Women First, PC
4100 Peachtree Street, Suite 1250
Atlanta GA 30303

WH GE-DEMO
DOB: 2/15/1988, 31 years
MRN: 458321
Exam Date: 10/3/2019
Report finalized

Second / Third Trimester Ultrasound

Indication

Fetal Anatomy Screening

Pregnancy

Singleton pregnancy. Number of fetuses: 1

Dating

	Date	Details	Gest. age	EDD
LMP	6/8/2019		16 w + 5 d	3/14/2020
U/S	10/3/2019	based upon AC, BPD, Femur, HC	17 w + 0 d	3/12/2020
Assigned dating	based on the LMP, selected on 10/3/2019		16 w + 5 d	3/14/2020

Fetal Biometry

BPD	34.4 mm	16w 4d	44%	Hadlock
HC	122.4 mm	16w 1d	12%	Hadlock
AC	120.0 mm	17w 5d	81%	Hadlock
Femur	24.8 mm	17w 3d	75%	Hadlock

Fetal Weight Calculation:

EFW	194 g	85%	Hadlock
EFW (lb,oz)	0 lb 7 oz		

General Evaluation

Cardiac activity present. FHR 150 bpm. **Fetal movements:** visualized. **Presentation:** breech

Placenta: Placental site: anterior, fundal. Placental edge-to-cervical os distance 10 mm

Umbilical cord: 3 vessel cord

Amniotic fluid: Amount of AF: normal

Fetal Anatomy

The following structures appear normal:

Cranium. Lateral ventricles. Choroid plexus. Midline falx. Cavum septi pellucidi. Cerebellum. Cisterna magna. Lips. 4-chamber view. RVOT view. LVOT view. 3-vessel view. 3-vessel-trachea view. Stomach. Kidneys. Bladder. Cervical spine. Thoracic spine. Lumbar spine. Sacral spine. Arms. Hands. Legs. Feet.

The following structures could not be adequately visualized:

Cord insertion.

Maternal Structures

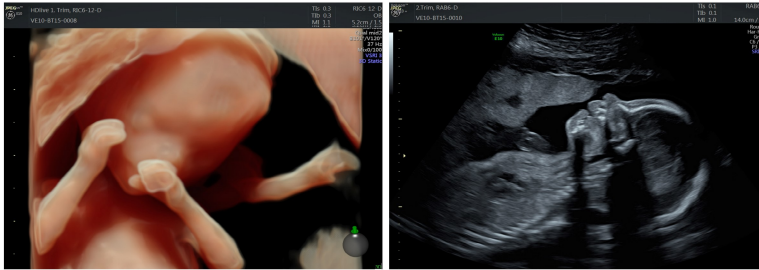
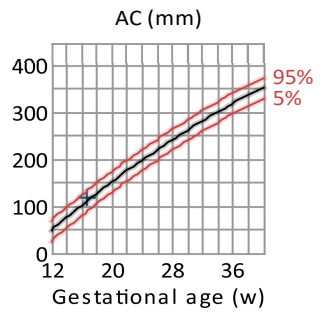
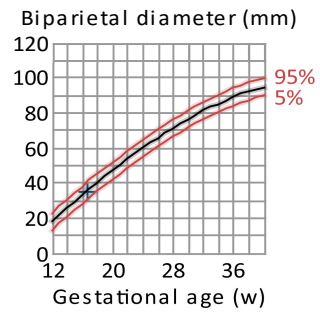
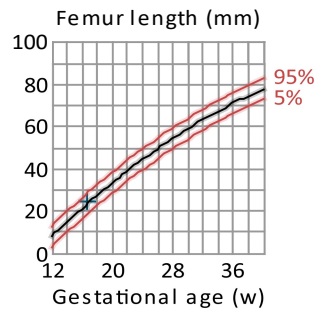
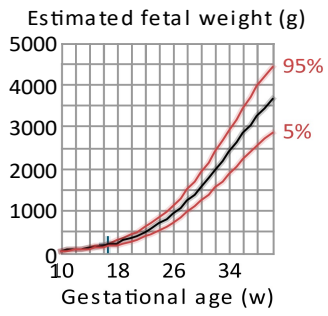
Uterus Normal
Cervix Normal
Cervical length 45.0 mm
Right Ovary Visualized
Left Ovary Visualized

Impression

Fetal biometry averages 16w 5d.

No anatomic malformations or evidence of aneuploidy are noted.

Placental location and amniotic fluid volume are normal.



Alan Jeffries, MD
 Reading physician
 Electronically signed by Alan Jeffries, MD at 11:49 AM on 11/10/2020

Lisa Brown, RDMS
 Sonographer