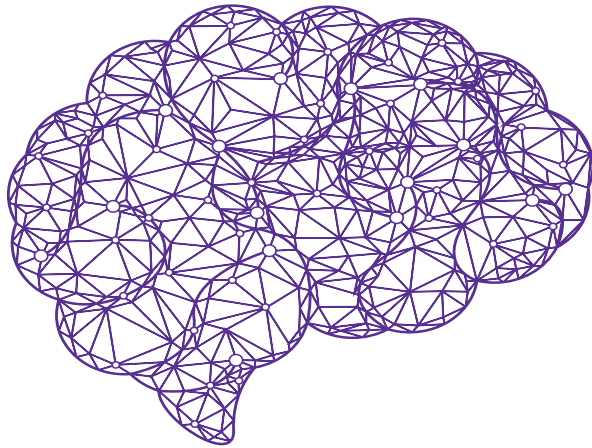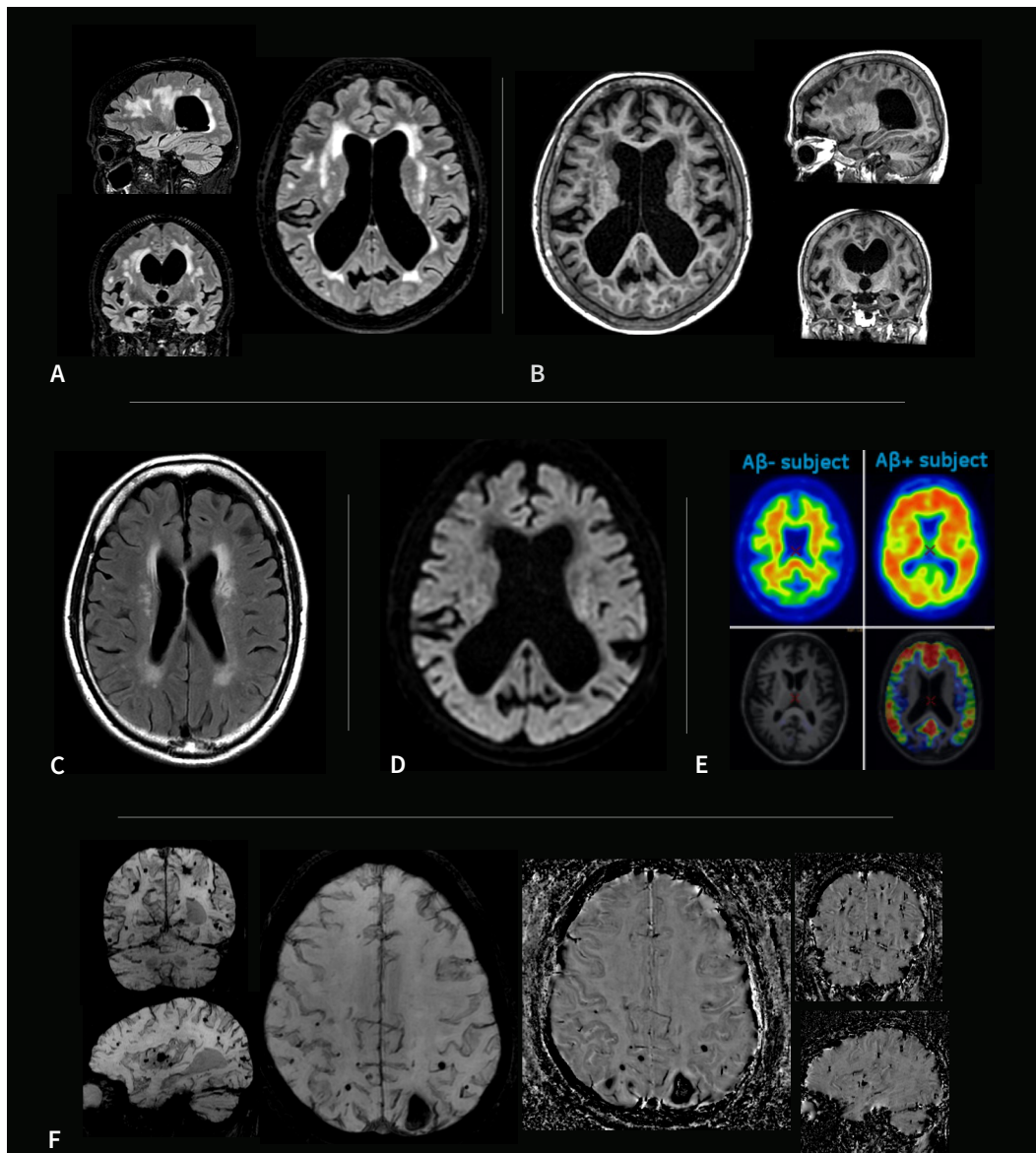


Imaging of Alzheimer's Disease

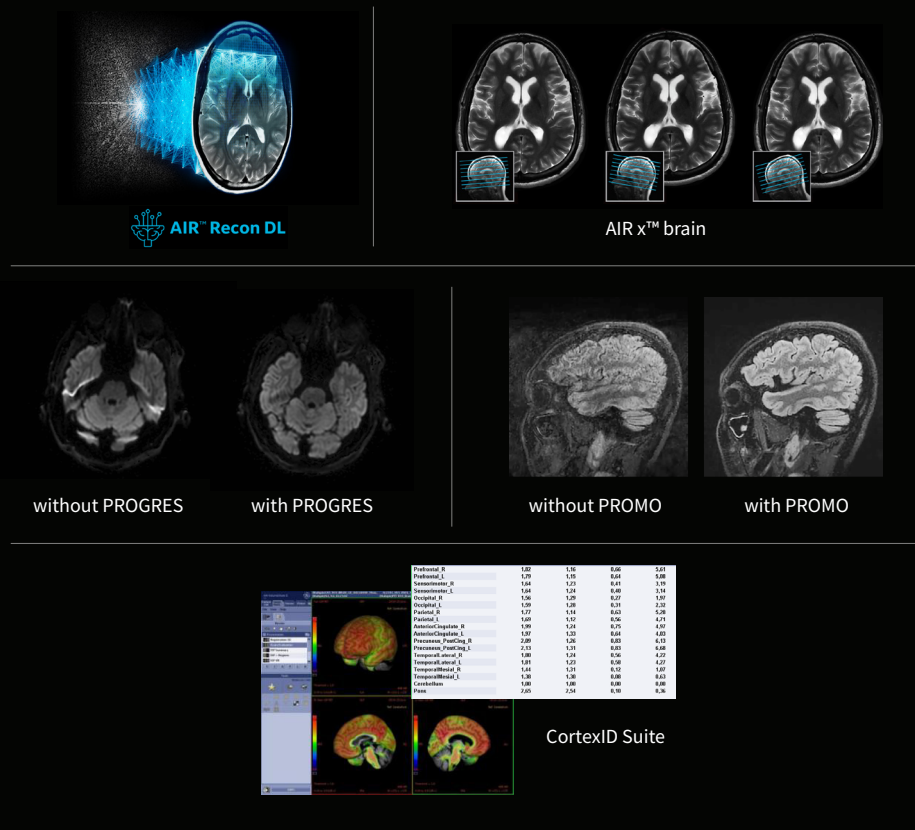


Alzheimer's Disease (AD) is the most common type of dementia, believed to affect over 10% of adults over the age of 65. AD is incurable and, thus far, treatment has focused on improving the quality of life for patients by maintaining brain health, managing behavioral symptoms and slowing or delaying symptoms of the disease [1,2].

In 2021, a new drug was approved by the US FDA for the treatment of AD. Clinical use of these drug therapies require MR imaging to aid



- A – 3D Cube T2 FLAIR with HyperSense acceleration and HyperCube volume localization
- B – 3D MP-RAGE with HyperSense acceleration for T1-weighted imaging
- C – 2D T2 FLAIR with AIR™ Recon DL
- D – Diffusion-weighted EPI with PROGRES distortion correction
- E – PET with Vizamyli™ fused on 3D BRAVO
- F – 3D SWAN for susceptibility weighted imaging, with magnitude and phase images



Is your neuro imaging practice ready for monitoring amyloid-related imaging abnormality (ARIA)?

Such side effects include edema, microbleeds and siderosis that can be monitored with MR. Do you have tools to help interpret beta-amyloid images? With GE Healthcare MR and PET/MR imaging equipment, you can be confident in having robust solutions for AD patient management. Differentiated solutions include:

- **AIR™ Recon DL** - GE HealthCare's pioneering, deep-learning-based reconstruction for improving SNR and image sharpness, while enabling shorter scan times.
- **AIR x™** - a deep-learning-based workflow tool that automatically identifies anatomical landmarks and prescribes slices reproducibly, for more consistent longitudinal scanning.
- **HyperSense** - delivers a compressed-sensing boost to image acceleration for faster and higher-resolution acquisitions.
- **PROMO** - a real-time prospective motion correction technique with minimal scan time penalty and without the need for external cameras or fiducial markers.
- **PROGRES** - effective for reducing unwanted distortion artifacts in diffusion-weighted and diffusion-tensor imaging in challenging anatomical regions.
- **CortexID Suite** - fully automated, post-processing solution to quantify PET beta amyloid and FDG scans acquired on PET/MR and other hybrid PET scanners. May aid in the interpretation of PET studies on patients evaluated for cognitive impairment or other causes of cognitive decline, and is an adjunct to other diagnostic evaluations.
- **Post-processing applications** - access to the latest cutting-edge applications for quantitative report generation including atrophy reports with Quantib™ Brain, NeuroQuant and Icometrix.

in patient selection, detect signs of adverse reactions and ultimately monitor the drug's effectiveness and disease progression.

Users of GE HealthCare's industry-leading PET/MR, that simultaneously scans with PET and MR, know the value of co-registered PET and MR images for AD. PET measures the accumulation of beta-amyloid plaque, which can't be detected with MR or CT. Beta-amyloid plaque deposition may begin as early as 10 to 15 years before cognitive impairment symptoms.

Want to learn more?
Contact your local GE representative.

References:

1. "2021 Alzheimer's disease facts and figures." Alzheimer's Association. 2021. <<https://www.alz.org/media/Documents/alzheimers-facts-and-figures-infographic.pdf>>.
2. "What Is Alzheimer's?" Alzheimer's Association. 5 December 2018. <<https://www.alz.org/alzheimers-dementia/what-is-alzheimers>>.
3. Thakar, S. "MRI scans using diffusion tensor imaging can predict Alzheimer's disease." Radiology Business. 20 November 2018. <<https://www.radiologybusiness.com/topics/care-delivery/mri-diffusion-tensor-imaging-promising-alzheimers>>.
4. Mattsson, N., et al. Predicting diagnosis and cognition with 18F-AV-1451 tau PET and structural MRI in Alzheimer's disease. *Alzheimer's & Dementia*. 15(4): 570-580, (April 2019). <https://doi.org/10.1016/j.jalz.2018.12.001>.
5. Racine, A.M., Merluzzi, A.P., Adluru, N. et al. Association of longitudinal white matter degeneration and cerebrospinal fluid biomarkers of neurodegeneration, inflammation and Alzheimer's disease in late-middle-aged adults. *Brain Imaging and Behavior* 13, 41-52 (2019). <https://doi.org/10.1007/s11682-017-9732-9>.
6. Xekardaki, A., Rodriguez, C., Montandon, M-L., et al. Arterial spin labeling may contribute to the Prediction of cognitive Deterioration in healthy elderly individuals. *Radiology*: 274(2):490-499, (October 2014). <https://doi.org/10.1148/radiol.14140680>

© 2023 GE HealthCare. GE is a trademark of General Electric Company used under trademark license. GE HealthCare reserves the right to make changes in specifications and features shown herein, or discontinue the product described at any time without notice or obligation. Contact your GE HealthCare representative for the most current information. SIGNA and AIR are trademarks of GE HealthCare.