

ViewPoint 6

GE Healthcare



Requesting Provider:
Brandon Edwards, MD
Women First, PC
4100 Peachtree Street, Suite 1250
Atlanta GA 30303

WH GE-DEMO
DOB: 2/15/1988, 31 years
MRN: 458321
Exam Date: 8/12/2019
Report finalized

Early Pregnancy Assessment

Indication

First Trimester Bleeding

Pregnancy

Singleton pregnancy. Number of embryos: 1

Dating

	Date	Details	Gest. age	EDD
LMP	6/8/2019		9 w + 2 d	3/14/2020
Assigned dating	based on the LMP, selected on 08/12/2019		9 w + 2 d	3/14/2020

Assessment

Gestational sac: visualized. Location: intrauterine
Yolk sac: visualized
Embryo: visualized
Cardiac activity: present

CRL	28.3 mm	73%	Rempen
FHR	160 bpm		

Maternal Structures

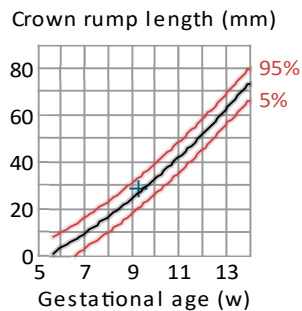
Uterus and adnexa normal

Impression

Intrauterine pregnancy seen measuring 9w 2d and corresponding to an EDD of 03/14/2020. Cardiac activity is noted at 160 bpm. Maternal uterus, ovaries and adnexa appear normal.

Follow-up

Repeat evaluation for fetal growth and anatomy survey is recommended between 18 to 22 weeks.



Alan Jeffries, MD
Reading physician
Electronically signed by Alan Jeffries, MD at 11:05 AM on 11/10/2020

Lisa Brown, RDMS
Sonographer