

LOGIQ E9 Shear Wave Elastography

Introduction

Tissue stiffness is often related to underlying disease. For millennia, physicians have used palpation as a diagnostic tool to detect various ailments such as lesions, aneurysms, and inflammation. Stiff masses found during routine physical exams can be an early indication of disease, as in the cases of breast and prostate cancer. In some ailments, such as liver fibrosis, disease progression is marked by a gradual change in tissue stiffness. The ability to non-invasively measure tissue stiffness can therefore be a valuable tool in the diagnosis, staging, and management of disease¹.

Elastography

Over the past 20 years, a number of approaches have been developed to image the mechanical properties of soft tissue non-invasively and in vivo². Analogous to the process of palpation, these so-called “elastography” techniques image the tissue response to a mechanical stimulus. The tissue deformation is then used to obtain a qualitative or quantitative measure of stiffness. These methods can be classified according to the type of information portrayed, the source of excitation, and the imaging modality used to monitor tissue response, as shown in *Table 1*.

	Method	Description
Excitation Source	Mechanical	Devices such as plates, actuators, or the imaging transducer can be applied to the skin surface to deform the tissue underneath. They can be used to apply static compression or dynamic excitation. Interstitial devices, such as intravascular balloons, can be used to induce strain in arteries.
	Acoustic Radiation Force	Force generated by ultrasound in tissue can be used to provide excitation to the focal region of an acoustic beam, allowing localized mechanical energy to be delivered directly to deep-lying tissue. Can be used to generate Shear Waves in tissue.
	Physiological Motion	Motion due to respiration, arterial pressure, cardiac, or other muscle activity can be used to derive elasticity information in arteries, skeletal muscle, and myocardium.
Imaging Modality	Ultrasound	The first non-invasive measurements of tissue stiffness were made using ultrasound and took advantage of its real-time imaging capabilities and Doppler processing techniques for detecting tissue motion. Today, it remains the most widely used imaging modality for elastography, due to fast measurement speeds (within seconds), portability, low cost, and its ability to also provide excitation with acoustic radiation force.
	MR	Elastography using MR is often referred to as magnetic resonance elastography (MRE). Typically, MRE systems use mechanical drivers to generate Shear Waves in the body. MR has the advantage of being a 3D imaging modality, and has the capability to measure motion with equal sensitivity in any direction. However, it is expensive, not suitable for use in all clinical settings, and has acquisition times on the order of minutes.
	Strain Elastography	Qualitative 2D image of stiffness displaying the tissue strain. High strain corresponds to a soft medium, low strain a hard medium.
Property Displayed	Acoustic Radiation Force Impulse (ARFI)	Qualitative 2D image of stiffness displaying acoustic radiation force induced tissue displacement amplitude. High displacement corresponds to a soft medium, low displacement a hard medium.
	Shear Wave Elastography	Quantitative stiffness measurement displaying the Shear Wave speed or Young’s modulus (a measure of stiffness). Point Shear Wave elastography measures the average stiffness within a small region of interest and does not show an image of stiffness. “Transient elastography” is an example of a point Shear Wave elastography method. 2D Shear Wave elastography displays an image of stiffness within a region of interest.

Table 1. Summary of the major techniques used in elastography.

Shear Wave Elastography

Shear Wave elastography is an imaging technique which quantifies tissue stiffness by measuring the speed of Shear Waves in tissue³. As shown in *Figure 1*, Shear Waves are a type of mechanical wave which can only propagate in a solid. Shear Wave elastography techniques use dynamic excitation to generate Shear Waves in the body. The Shear Waves are monitored as they travel through tissue by a real-time imaging modality. Under simplifying assumptions, the Shear Wave speed (c_t) in a medium is related to the Young's Modulus (E), which is a measure of stiffness: $E = 3\rho c_t^2$, where ρ is density. Therefore, by estimating the Shear Wave speed, the underlying tissue stiffness can be quantified. A low speed corresponds to a soft medium, while a high speed indicates a stiff medium. The Shear Wave speed can be directly used as a proxy for stiffness or converted to Young's Modulus. Unlike strain elastography, which produces a qualitative measurement of stiffness, Shear Wave elastography quantifies tissue stiffness on an absolute scale.

Shear Wave Elastography with Ultrasound

Ultrasound technology is well suited for implementing Shear Wave elastography. First, ultrasound can be used to generate Shear Waves in tissue. As sound waves propagate, a portion of their energy is transferred to the surrounding medium by absorption or reflection, as shown in *Figure 2*. In soft tissue, the acoustic radiation force (F) imparted by ultrasound to the medium is given by $F = \frac{2aI}{c_t}$, where a is the absorption coefficient, I the temporal average intensity, and c_t the speed of sound⁴. In diagnostic imaging, the magnitude of this force is negligible. However, by increasing the intensity of the sound waves, micron levels of displacement can be induced in tissue using a diagnostic ultrasound transducer. Application of high intensity ultrasound for a duration on the order of 100 μs generates Shear Waves in tissue⁵.

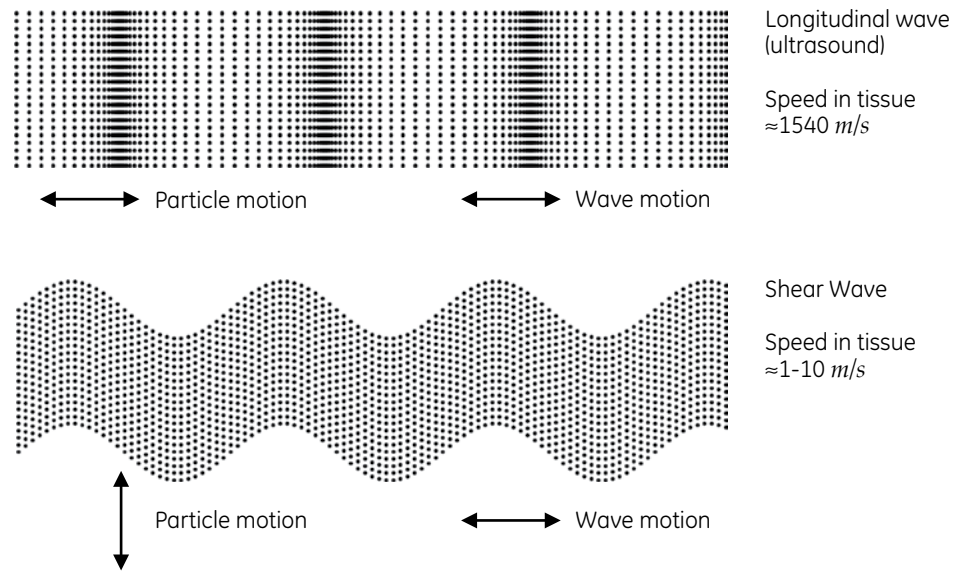
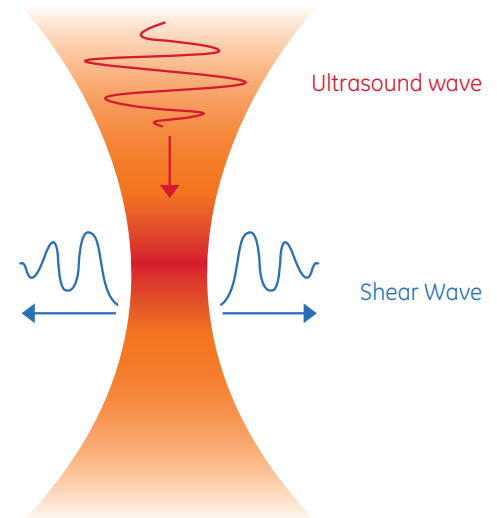


Figure 1. Shear Wave and longitudinal wave motion. In a longitudinal wave, particle motion is parallel to the wave propagation direction. Ultrasound is a type of longitudinal wave. In a Shear Wave, particle motion is perpendicular to the propagation direction.

Figure 2. The acoustic radiation force field from a focused ultrasound beam. The force field (or region of excitation) always lies within the geometric shadow of the active transmit aperture and is typically most energetic near the focal point. High intensity focused ultrasound beams can be used to push on tissue to generate Shear Waves, which propagate laterally away from the region of excitation.



Another advantage of ultrasound is its capability to image motion. The micron-level Shear Wave displacements induced by acoustic radiation force can be detected by speckle tracking methods used in color flow imaging⁶. Since the speed of sound in tissue is approximately 1000 times faster than the Shear Wave speed, it is possible to use ultrasound to fully monitor the dynamics of Shear Wave propagation through tissue.

The fact that ultrasound can provide both the stimulus to generate Shear Waves in tissue and the means to observe the resulting tissue response enables Shear Wave elastography to be performed using a single diagnostic ultrasound probe. This facilitates the integration of Shear Wave elastography onto existing diagnostic ultrasound systems. Such a system can be used for other diagnostic purposes in addition to Shear Wave elastography, whereas dedicated Shear Wave elastography systems can only perform a single type of exam. Furthermore, the B-mode imaging capabilities of a diagnostic ultrasound system can be leveraged to provide image guidance of the exact location where Shear Wave elastography is performed, helping to ensure that a stiffness measurement is taken in the intended location.

Finally, ultrasound is a low-cost, readily accessible, and portable imaging modality. Shear Wave elastography measurements can be acquired by ultrasound in seconds, compared to minutes with MR. These factors enable ultrasound Shear Wave elastography to be used in a variety of different clinical settings.

Shear Wave Elastography Implementation on the LOGIQ E9

GE's implementation of Shear Wave elastography on the LOGIQ E9 displays 2D images of Shear Wave speed or Young's Modulus in a region of interest (ROI). This Shear Wave elastography image is overlaid on top of a larger B-mode image at the same location. The user can adjust the size and position of the ROI using the B-mode image for guidance so that it is at the anatomy of interest. The stiffness at any location within the ROI can then be sampled using measurement tools to obtain a quantitative measurement of stiffness either in terms of Shear Wave speed (m/s), or Young's Modulus (kPa). This differs from point Shear Wave elastography systems which measure the average stiffness within a ROI and do not display an image of stiffness.

Creating an image offers several benefits. First, it enables spatial variations in stiffness to be instantly observed. This could be useful for the detection and characterization of focal lesions. In the breast, a Shear Wave elastography image enables the stiffness of the hardest part of the lesion to be quantified and compared to adjacent tissue.

Secondly, because acoustic radiation force induced Shear Waves are small, factors such as tissue motion or poor B-mode image quality can degrade the result. By generating a Shear Wave image instead of a single measurement value, the LOGIQ E9 helps the user to instantly perform

a visual quality assessment of the result, as shown in *Figure 3*. This feedback gives the user additional information on the quality of the measurement that point Shear Wave elastography systems do not provide.

Shear Wave elastography on the LOGIQ E9 has the capability to acquire images continuously. It is important that the image displayed to the user is updated at a sufficient rate. This frame-rate is dictated by two factors: the acquisition time and cooling time. The acquisition time is the time needed for the system to acquire all the data needed to generate the image. The cooling time is the period after acquisition that the system is required to wait before it can begin to acquire data for the next frame. This cooling period is unique to Shear Wave elastography mode and is needed to ensure the acoustic output of the pushing pulses are under regulatory safety levels. On the LOGIQ E9, the acquisition time is typically on the order of 100 ms , whereas the cooling time is typically 2-3 s and is the dominant factor in limiting the frame-rate. Even though the acquisition time does not significantly contribute to the frame-rate, it is important to minimize it to reduce tissue motion artifacts. To minimize both acquisition and cooling time, Shear Wave elastography on the LOGIQ E9 uses several innovative techniques.

Comb-Push Excitation

A significant challenge in using acoustic radiation force for Shear Wave elastography is that the region of tissue interrogated by Shear Waves generated by a single focused pushing beam is limited. The reason for this is two-fold. One is that Shear Waves of very small amplitude are generated with acoustic radiation force and these waves are quickly attenuated as they propagate away from the region of excitation. The other reason is that Shear Waves are not generated at the pushing location due to inertial effects. To reconstruct the tissue stiffness over a ROI, data from multiple push locations can be combined. However, the need to transmit multiple pushes sequentially to synthesize a single Shear Wave elastography image results in increased acquisition time. To achieve a large size ROI without increasing the acquisition time, multiple pushing beams are transmitted on the LOGIQ E9 simultaneously in a comb-like pattern, as illustrated in *Figure 4*⁷. Each pushing beam can be treated as an independent source of Shear Waves. As they propagate, the wave fronts generated by each push eventually meet, and pass through each other. All of these wave fronts combined are able to interrogate a much larger region of tissue in a single transmit event.

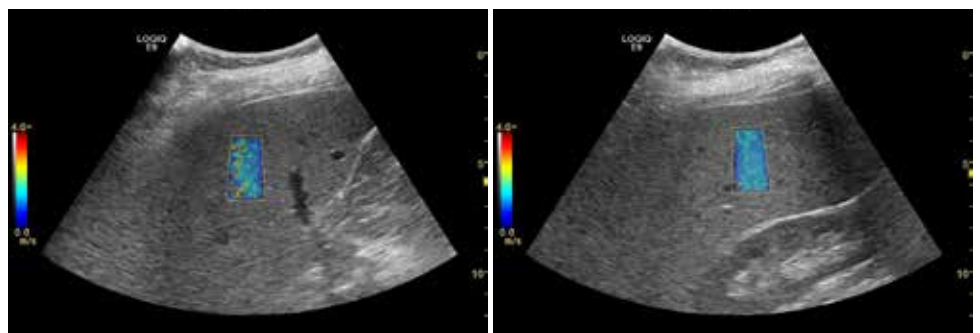


Figure 3. Examples of liver Shear Wave elastography images obtained on a patient with elevated liver function tests. The image on the left is degraded by artifacts on the left side of the ROI, possibly due to poor probe contact or rib shadowing. By moving the ROI to another location as shown on the right, a more homogeneous image filling the entire ROI is obtained.

Time-Interleaved Shear Wave Tracking

On a conventional ultrasound scanner, the number of image lines that can be formed in parallel from a single transmit is limited. For example, a 2 cm wide ROI may be composed of 30 image lines. Shear Wave motion can only be measured in a small portion of this ROI at any given instant in time. To perform Shear Wave elastography in a region of this size, the comb-push must be transmitted multiple times, and the tissue response tracked in a different region of the ROI each time until the entire ROI is filled. The need to retransmit the same high-intensity pushing beams multiple times necessitates a significant decrease in Shear Wave elastography frame-rate due to transducer and system heating issues as well as acoustic output concerns.

To overcome this challenge, the LOGIQ E9 uses a time-interleaved tracking scheme as shown in *Figure 5*. In the case of conventional Shear Wave tracking, as shown on the left, the comb-push is transmitted, then the tissue response is measured at all time points at a single group of image lines. The same comb-push is then retransmitted, and the motion measured at a different group. This is repeated until the tissue response in the entire ROI is measured. In the example shown in *Figure 5*, four repeated pushes are necessary. In the case of time-interleaved Shear Wave tracking, as shown on the right, the tissue response is sampled at a different location at every time point. This enables Shear Wave motion to be monitored over a wider lateral region and therefore reduces the number of repeat pushes. In the example shown in *Figure 5*, only a single push is required to measure the tissue response in the entire ROI. This technique reduces the effective temporal sampling rate, but missing data points in time are approximately recovered by interpolation. Time-interleaved tracking enables Shear Wave elastography to be performed over larger ROIs without a significant reduction in frame-rate.

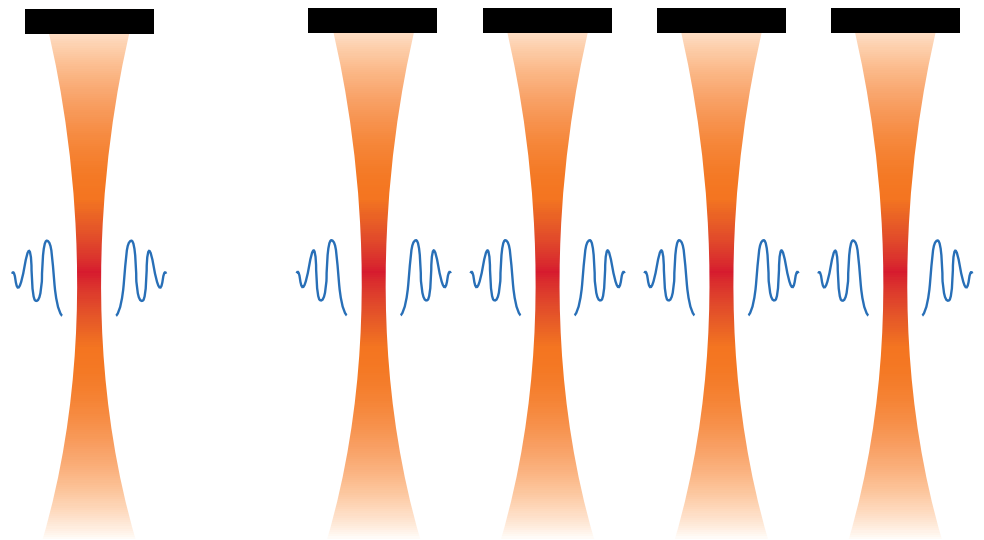


Figure 4. Comparison of single push beams and simultaneous pushing beams in a comb-like pattern. The black squares indicate the active aperture. A single push beam is only able to generate Shear Wave propagation in a limited region of tissue (left). By transmitting multiple pushes in a comb-like pattern, Shear Waves are generated in a much larger region of tissue (right).

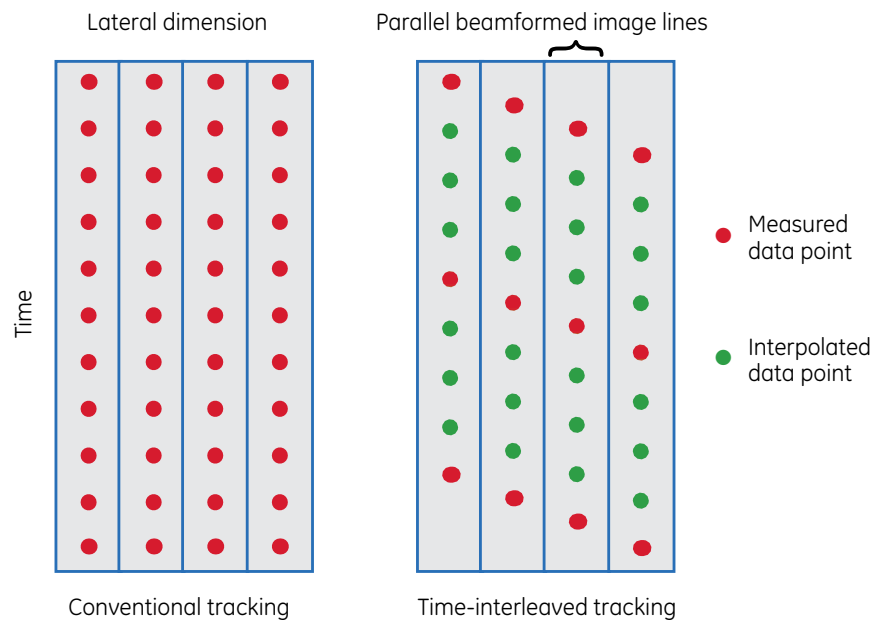


Figure 5. Conventional Shear Wave tracking scheme compared to time-interleaved Shear Wave tracking. Each column represents a group of parallel beamformed image lines within the Shear Wave elastography ROI.

Directional Filtering

One consequence of transmitting multiple push beams simultaneously is that a complicated Shear Wave field is generated, as shown in *Figure 6*. In particular, each push creates a left and right propagating wave which constructively and destructively interferes with waves generated by neighboring pushes. To make the calculation of Shear Wave speed easier, a directional filter is applied to separate the left and right propagating waves so that they can be processed separately⁸.

Local Shear Wave Speed Estimation

A time-of-flight algorithm is used to estimate the local Shear Wave speed at every location in the Shear Wave elastography ROI. The speed at a location of interest is calculated by cross-correlating the Shear Wave displacement time profiles at two neighboring points, as shown in *Figure 7*. The output of the cross-correlation function gives the time taken for the Shear Wave to travel between the two points. By dividing the distance between the two points by the transit time, the Shear Wave speed is obtained. The cross-correlation function also provides the correlation coefficient, which is used to assess the quality of the measurement.

This algorithm is applied independently to both the left and right propagating wave fields obtained after directional filtering, as shown in *Figure 8*. For each direction, a Shear Wave speed image and a correlation coefficient map is generated. The two Shear Wave speed images are blended together using the correlation coefficient maps as weights to produce the final displayed Shear Wave elastography image. The correlation coefficient maps are also blended together to produce a quality map which can be used by the user to prevent areas with low measurement quality from being displayed. In the example shown in *Figure 8*, artifacts caused by blood vessels within the ROI can be removed by applying the quality threshold.

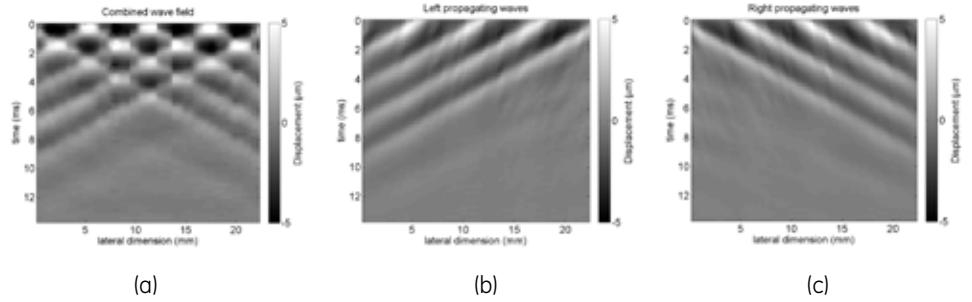


Figure 6. The Shear Wave displacement magnitude as a function of time and lateral location before and after directional filtering. The displacement field before directional filtering is shown in (a). There are five push beams and each of these generates a left and right propagating wave which interfere with each other, complicating Shear Wave speed estimation. After directional filtering, this interference is removed and only waves travelling in the same direction are present, as shown in (b) for left propagating waves and (c) for right propagating waves.

Figure 7. Shear Wave displacement time profile at two locations 3.6 mm laterally apart. The time delay between the two waveforms corresponds to the time taken by the Shear Wave to travel between the two points. This transit time is measured by calculating the cross-correlation of the two waveforms. Dividing the distance between the two points by the transit time yields the Shear Wave speed between the two points, which in this case is 2.4 m/s.

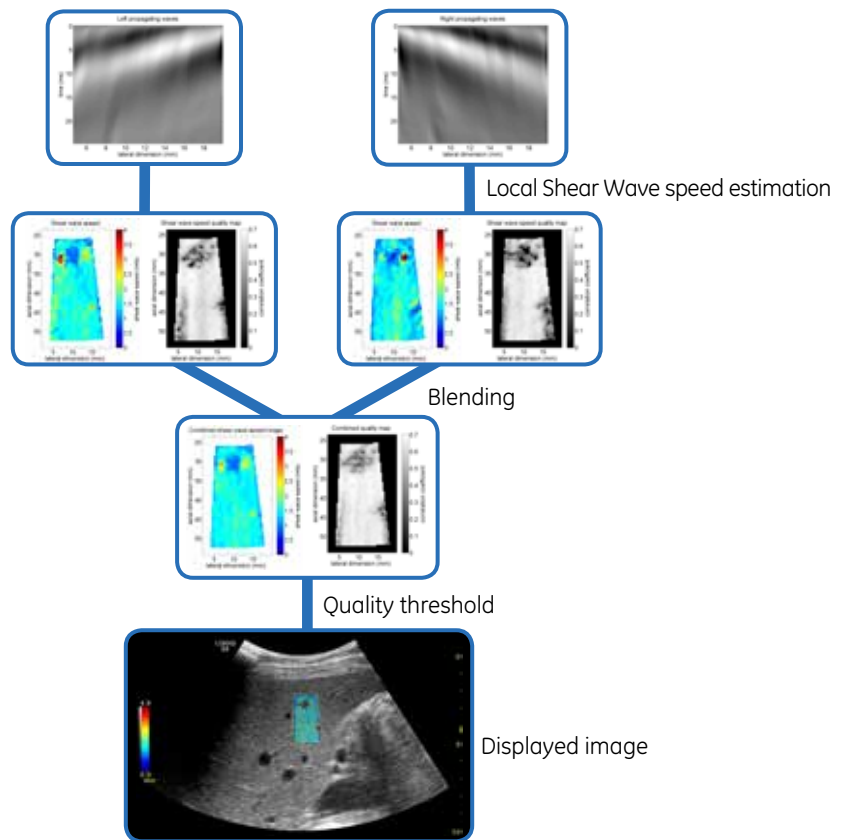
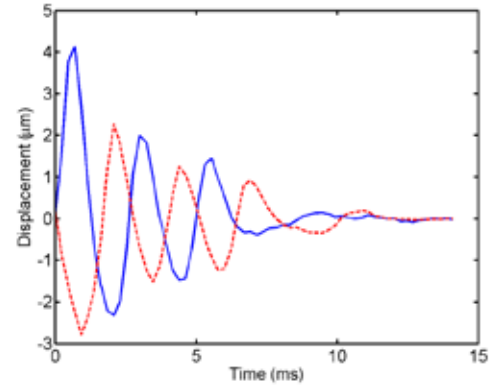


Figure 8. Shear Wave speed estimation algorithm.

Clinical Application: Liver Fibrosis Staging

Liver fibrosis can result from various types of chronic damage to the liver including infections, toxins, autoimmune disorders as well as cholestatic and metabolic diseases. Cirrhosis, the end stage of fibrosis, affects millions of people worldwide. Liver fibrosis is currently staged using needle biopsy, a highly invasive procedure with a number of disadvantages⁹. These include potential morbidity and mortality, as well as susceptibility to inter-observer variability and sampling error. Finally, repeat biopsies are not well-tolerated and therefore not suitable for monitoring disease progression.

It is well-known that liver stiffness increases with the progression of fibrosis. In recent years, there has been increasing interest in liver stiffness as a marker for hepatic fibrosis.

Ultrasound Shear Wave elastography is an attractive technology for assessment of liver fibrosis as it is non-invasive, low cost, portable, and suitable for use in a variety of clinical settings. The LOGIQ E9 enables Shear Wave elastography to be performed rapidly at the same time as an abdominal ultrasound exam. The LOGIQ E9 C1-6-D and C1-6VN-D probes are optimized for liver Shear Wave elastography. Measurement tools are available, allowing the user to sample areas within the displayed Shear Wave elastography image to quantify liver stiffness. Measurements from a single exam are collected in a worksheet and summary statistics are automatically shown.

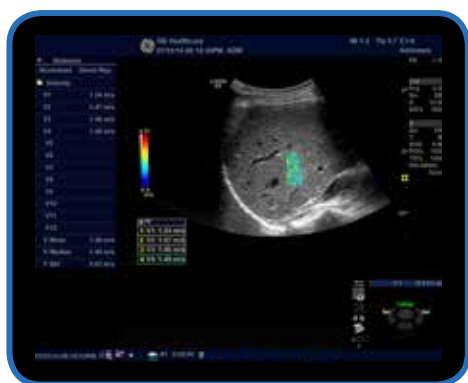

Image 1. The stiffness within multiple regions in a single Shear Wave image can be sampled using the measurement tool. All measurements collected in a single liver exam are listed on the left side of the display, as well as summary statistics.

Parameter	Value	m/s	m2	m3	m4	m5	m6
E1	0.70 kPa	0.70					
E2	0.91 kPa	0.91					
E3	0.74 kPa	0.74					
E4	0.68 kPa	0.68					
E5	0.54 kPa	0.58					
E6	0.64 kPa	0.64					
E7	0.60 kPa	0.60					
E8	0.60 kPa	0.60					
E9	0.63 kPa	0.63					
E10	0.73 kPa	0.73					
E Mean	0.68 kPa	0.68					
E Median	0.65 kPa	0.65					
E Std	0.10 kPa	0.10					

Image 2. Stiffness measurements recalled from the worksheet. The user can select measurements for deletion or exclusion from calculation of the mean, median, and standard deviation.

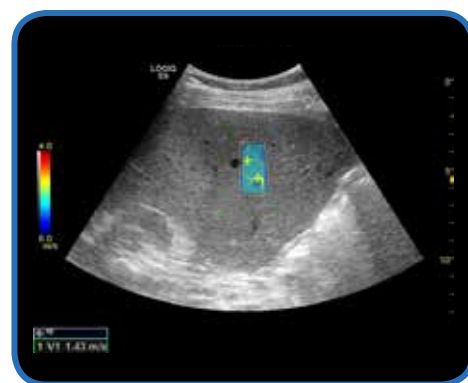


Image 3. Low liver Shear Wave speed measured in a patient with hepatitis C and hepatocellular carcinoma after liver transplant.

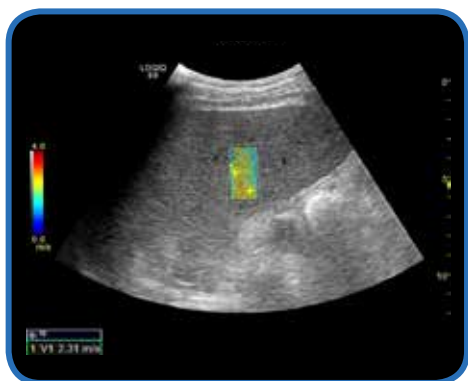

Image 4. High liver Shear Wave speed measured in a patient with Child-Pugh A cirrhosis.

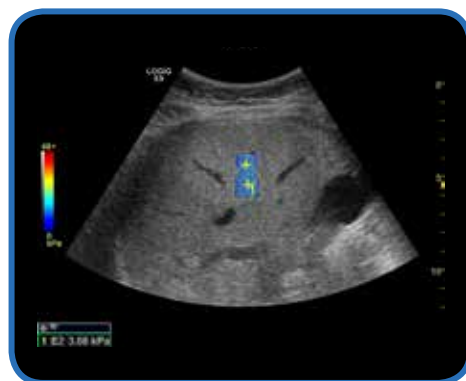

Image 5. Low liver Young's Modulus measured in a patient with stage F1 fibrosis.

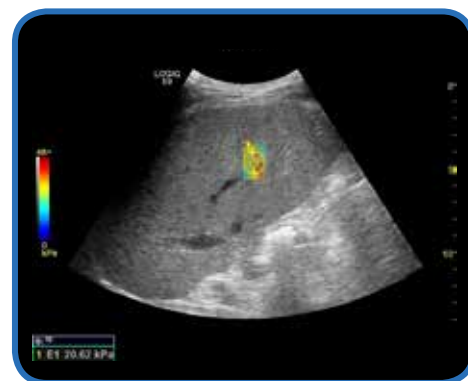


Image 6. High liver Young's Modulus measured in a patient with cirrhosis and suffering from portal hypertension and hepatitis C.

Conclusions

Shear Wave elastography on the LOGIQ E9 allows the user to visualize the tissue stiffness as a color-coded map in a 2D region of interest as well as providing the user with a quantitative measurement. Shear Wave elastography is a promising technique for non-invasive quantification of tissue stiffness and has the potential to be useful in the diagnosis, staging, and management of diseases associated with changes in tissue elasticity.

References

- ¹ Bamber, J., Cosgrove, D., Dietrich, C. F., Fromageau, J., Bojunga, J., Calliada, F., ... & Piscaglia, F. (2013). EFSUMB guidelines and recommendations on the clinical use of ultrasound elastography. Part 1: Basic principles and technology. *Ultraschall Med*, 34(2), 169-184.
- ² Greenleaf, J. F., Fatemi, M., & Insana, M. (2003). Selected methods for imaging elastic properties of biological tissues. *Annual review of biomedical engineering*, 5(1), 57-78.
- ³ Sarvazyan, A. P., Rudenko, O. V., Swanson, S. D., Fowlkes, J. B., & Emelianov, S. Y. (1998). Shear Wave elasticity imaging: a new ultrasonic technology of medical diagnostics. *Ultrasound in medicine & biology*, 24(9), 1419-1435.
- ⁴ Nyborg, W. L. (1965). Acoustic streaming. *Physical acoustics*, 2(Pt B), 265.
- ⁵ Nightingale, K., McAleavey, S., & Trahey, G. (2003). Shearwave generation using acoustic radiation force: in vivo and ex vivo results. *Ultrasound in medicine & biology*, 29(12), 1715-1723.
- ⁶ Kasai, C., Namekawa, K., Koyano, A., & Omoto, R. (1985). Real-time two-dimensional blood flow imaging using an autocorrelation technique. *IEEE Trans. Sonics Ultrason*, 32(3), 458-464.
- ⁷ Song, P., Zhao, H., Manduca, A., Urban, M. W., Greenleaf, J. F., & Chen, S. (2012). Comb-push ultrasound Shear Wave elastography (CUSE): a novel method for two-dimensional Shear Wave elasticity imaging of soft tissues. *Medical Imaging, IEEE Transactions on*, 31(9), 1821-1832.
- ⁸ A. Manduca, D.S. Lake, S.A. Kruse, R.L. Ehman, Spatio-temporal directional filtering for improved inversion of MR elastography images, *Medical Image Analysis*, Volume 7, Issue 4, December 2003, Pages 465-473.
- ⁹ Friedman, S. L. (2003). Liver fibrosis-from bench to bedside. *Journal of hepatology*, 38, 38-53.



About Us

GE Healthcare provides transformational medical technologies and services to meet the demand for increased access, enhanced quality and more affordable healthcare around the world. GE (NYSE: GE) works on things that matter—great people and technologies taking on tough challenges. Imaging, software & IT, patient monitoring and diagnostics to drug discovery, biopharmaceutical manufacturing technologies and performance improvement solutions, GE Healthcare helps medical professionals deliver great healthcare to their patients.

GE Healthcare
9900 Innovation Drive
Wauwatosa, WI 53226
U.S.A.
www.gehealthcare.com

Imagination at work

©2014 General Electric Company — All rights reserved.

General Electric Company reserves the right to make changes in specifications and features shown herein, or discontinue the product described at any time without notice or obligation.

GE, GE monogram, Vscan, and LOGIQ are trademarks of General Electric Company or one of its subsidiaries.

GE Healthcare, a division of General Electric Company.