



GE HealthCare

Reliability, productivity and image quality:

The role of Versana Premier in otolaryngology

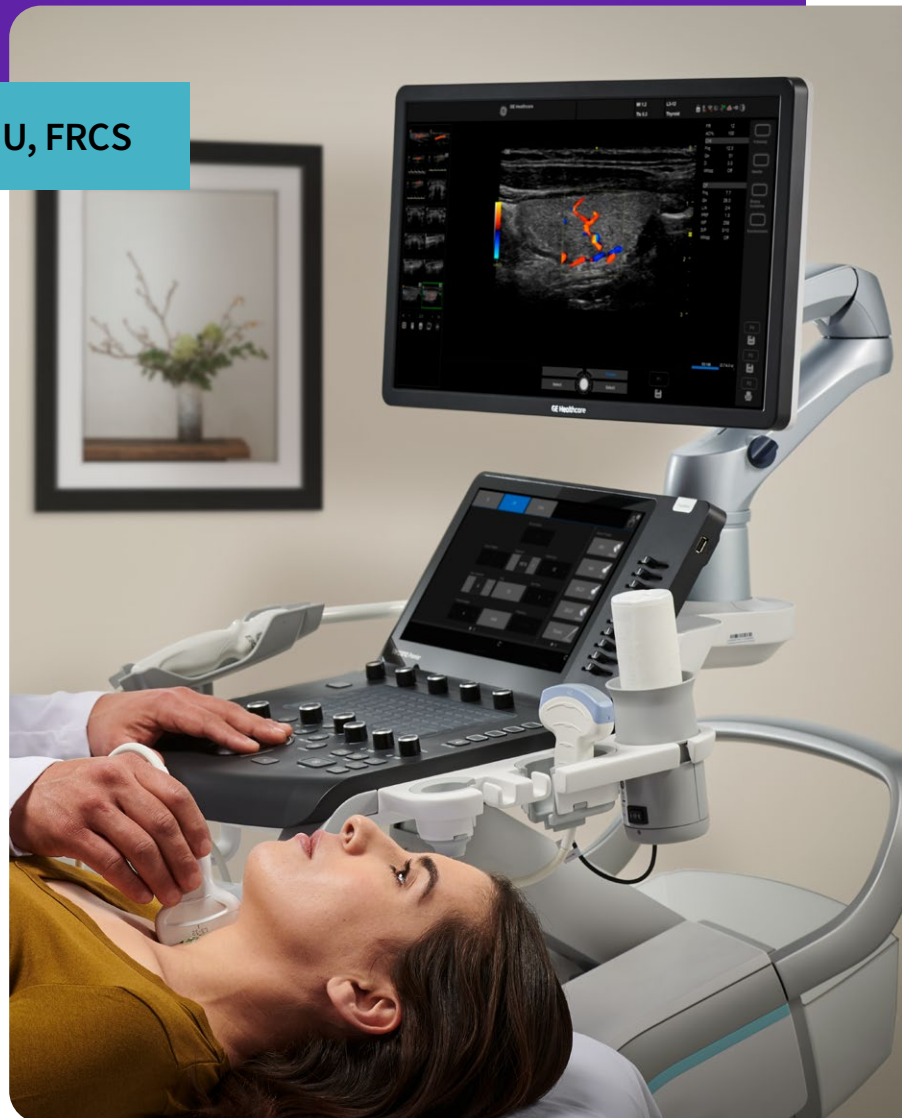Author: Jagdish K. Dhingra MBBS, ECNU, FRCS

Clinical case of pleomorphic adenoma

2024

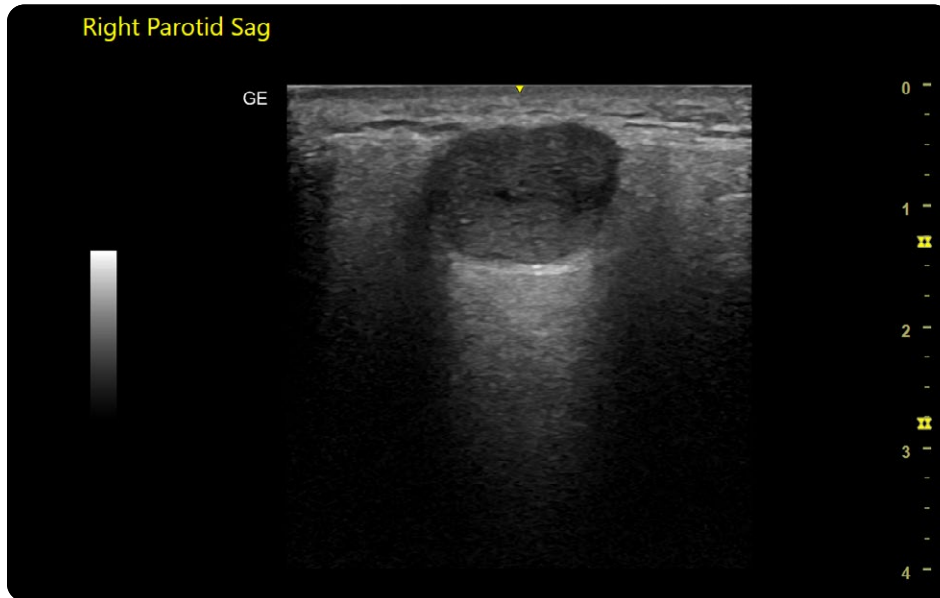
The following case was obtained by Dr. Dhingra using a Versana Premier™.

Dr. Dhingra is a paid consultant for GE HealthCare and was compensated for participation in this case study. The statements by Dr. Dhingra described here are based on his own opinions and on results that were achieved in his unique setting. Since there is no "typical" hospital and many variables exist, i.e. hospital size, case mix, etc., there can be no guarantee that other customers will achieve the same results.



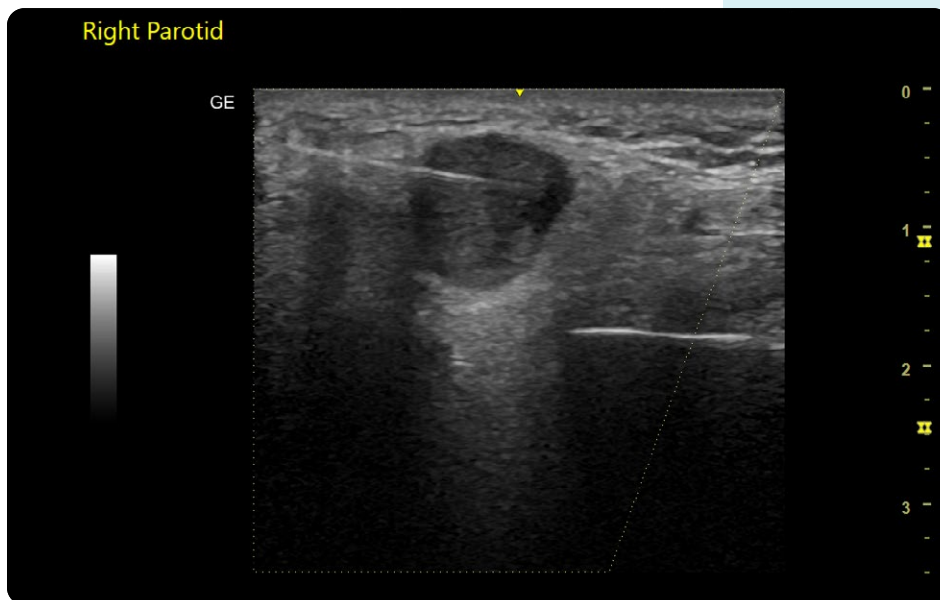
A case of pleomorphic adenoma

Clinical presentation



- 57-year-old male
- Presents with several year history of a slowly enlarging neck mass
- Physical exam reveals a right superficial parotid mass
- Ultrasound is positive for a solid hypoechoic mass with well-defined margins and posterior acoustic enhancement

Key findings



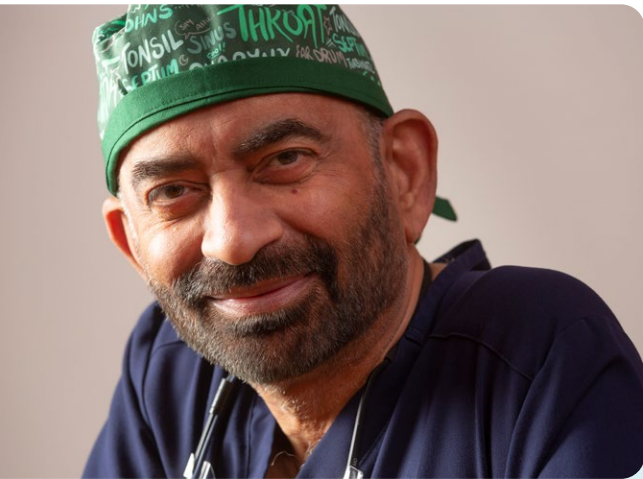Utilized feature: Ultrasound-guided fine needle aspiration was performed using Versana Premier Needle Guide Feature

Cytology results: Consistent with Pleomorphic adenoma

Key takeaway: A benign tumor that affects the salivary glands, particularly the parotid glands. Complete excision is the key to cure these tumors.

Conclusion

Ultrasound is an inexpensive, low-risk, and effective tool for evaluating thyroid and parotid lesions. Its accessibility and accuracy in predicting the nature of lesions compares favorably to that of more expensive and invasive cross-sectional imaging. Fine needle biopsies can be performed at the same visit, thus expediting care. These images taken on a Versana Premier suggest that ultrasound imaging in clinical settings can often be confidently used as an initial, and perhaps sole, imaging modality for thyroid and parotid masses.



Dr. Jagdish K Dhingra is an Otolaryngologist in Massachusetts with over 20 years of experience in the practice of otolaryngology head and neck surgery.

Dr. Dhingra did his initial training in India and the UK before moving to the US, where he did his residency training at Tufts Medical Center in Boston, Massachusetts before joining ENT specialists, Inc. in 2002.

For the last 10 years, he has focused his practice on diseases of the thyroid and parathyroid glands and has performed over 4,000 office-based ultrasound-guided thyroid procedures. He regularly teaches at courses sponsored by the American Head and Neck Society and American Academy of Otolaryngology – Head and Neck Surgery. He is also an associate professor at Tufts University School of Medicine.

Since 2005, Dr Dhingra has led 15 surgical missions to Rwanda, Africa and performed over 300 surgeries on patients with large goiters.

Products mentioned in the material may be subject to government regulations and may not be available in all countries. Shipment and effective sale can only occur after approval from the regulator. Please check with local GE HealthCare representative for details.

Versana Premier is a trademark of GE HealthCare. GE is a trademark of General Electric Company used under trademark license.

© 2024 GE HealthCare.

January 2024
JB26070XX



GE HealthCare