

Extracranial Examination

Patient name: Leslie McIsaac
Patient's DOB: 08/12/1943 (age: 63 years)

Referring physician: Dr. Harald Larch, Heart & Vascular Institute, 850 Mt. Auburn St. Watertown, MA 02472

Method: Duplex, US View: good, U/S-Machine: GE LOGIQ 9
 B/P Right Arm: 130 / 64mmHg B/P Left Arm: 141 / 77mmHg

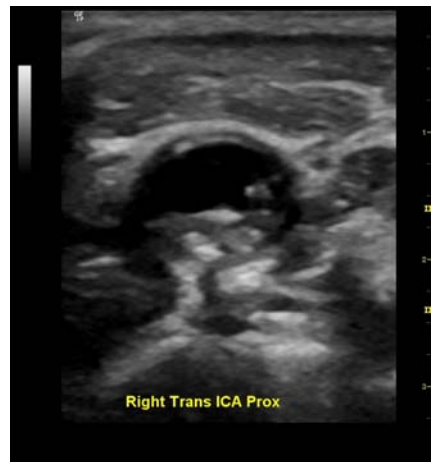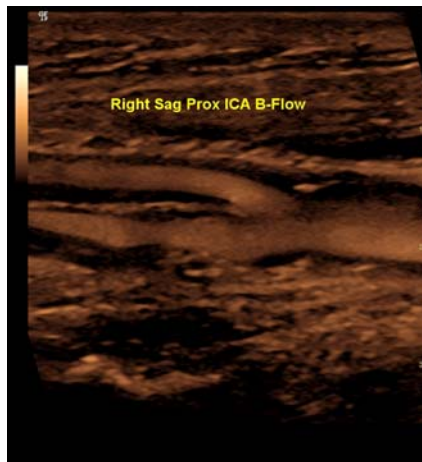
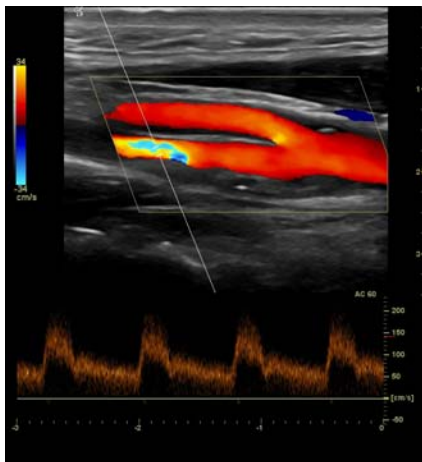
Indication: Type II diabetes, controlled, Tobacco use, Hypertension, Carotid stenosis, Prior Left CEA.

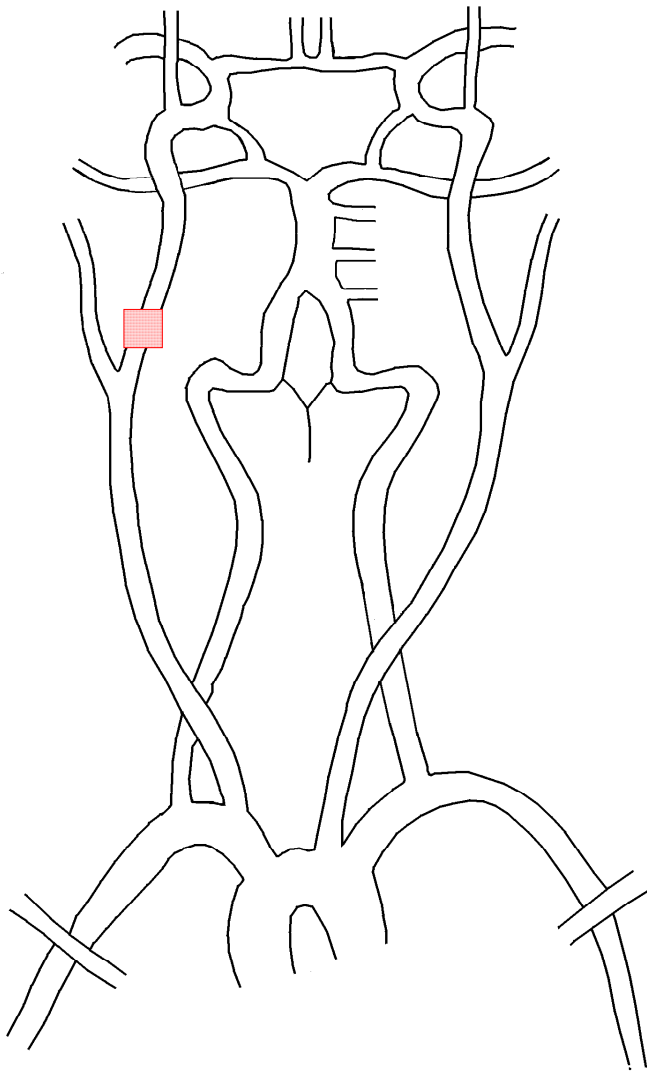
Results:	Right Side		Left Side	
	PSV [cm/s]	EDV [cm/s]	PSV [cm/s]	EDV [cm/s]
CCA prox.	75	23	78	23
CCA mid.	62	20	63	13
CCA dist.	83	26	85	17
Bulb	116	45	96	30
ICA prox.	172	51	120	38
ICA mid.	120	46	111	37
ICA dist.	94	40	107	36
ECA	107	11	94	6
Vertebral	56	20	52	28
Ratio ICA / CCA	2.1	2.0	1.4	2.2
Vertebral Artery	Antegrade flow		Antegrade flow	

Report Summary:

Impression: 60-69% stenosis in right proximal internal carotid artery. Prior left CEA with no evidence of a flow reducing stenosis. Antegrade flow in both vertebral arteries.

Recommendations: A repeat evaluation is recommended every six months.





Technician: UD. Bradley

Physician: Dr. Moore
