

Med. Record No.: 1
 Date of Exam: 08/31/2006
 Date of Print: 10/10/2006

Obstetrical Ultrasound Report

Patient name: Mary Ann O'Connor
Patient's DOB: 02/01/1973 (age: 33 years)

Referring physician: Dr Will Smith, Parkav. 113, Los Angeles, CA 12345

Indication: twin follow-up scan.

History: Age: 33 years.

Dating:

Best Overall Assessment: 06/30/2006 EDC: 01/11/2007 Assessed GA: 21w0d

The Best Overall Assessment is based on the ultrasound examination on 06/30/2006.
 The calculation of the gestational age was then based on CRL of Fetus 1.

Anatomy Scan:

Fetus 1:

Biometry:

BPD	51.0	mm	-	21w3d	(20w6d to 22w0d)
HC	191.0	mm	-	21w3d	(19w6d to 22w6d)
AC	165.0	mm	-	21w4d	(20w6d to 22w2d)
FL	37.0	mm	-	21w5d	(20w0d to 23w4d)
HUM	34.0	mm	-	21w4d	
EFW (lbs/oz)	0 lbs			15 ozs	
EFW (g)	437	g		76th%	

Fetal Anatomy:

Visualized with normal appearance: head, brain, face, spine, neck, skin, chest, 4 chamber heart and great vessels, abdominal wall, gastrointestinal tract, kidneys, bladder, extremities, skeleton.

Genitalia: Male fetus.

Fetal heart activity: present.

Fetus 2:

Biometry:

BPD	44.0	mm	-	19w2d	(18w5d to 19w6d)
HC	176.0	mm	-	20w1d	(18w4d to 21w4d)
AC	145.0	mm	-	19w6d	(19w1d to 20w4d)
FL	32.0	mm	-	20w0d	(18w1d to 21w5d)
HUM	29.7	mm	-	19w6d	
EFW (lbs/oz)	0 lbs			11 ozs	
EFW (g)	319	g		7th%	



Fetal Anatomy:

Visualized with normal appearance: head, brain, face, spine, neck, skin, chest, 4 chamber heart and great vessels, abdominal wall, gastrointestinal tract, kidneys, bladder, extremities, skeleton.

Genitalia: Female fetus.

Fetal heart activity: present.

Report Summary:

Impression: Twin growth and fluid volumes are normal.

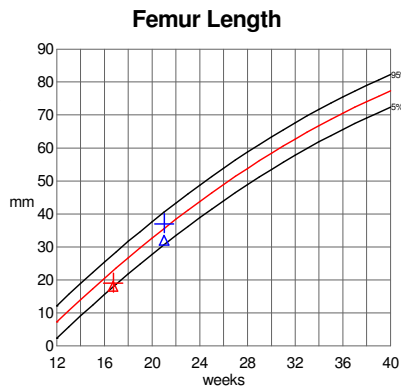
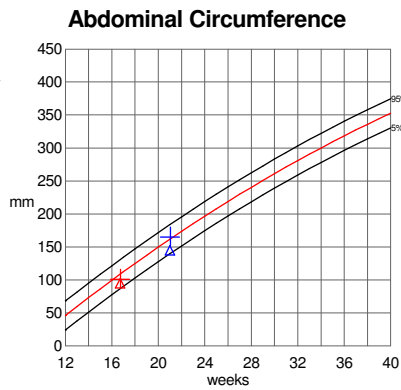
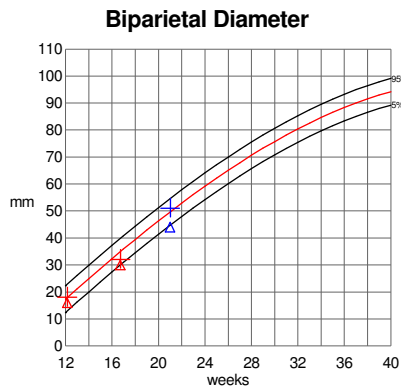
Fetal Growth Overview:

Fetus 1

Date	GA	BPD [mm]	HC [mm]	AC [mm]	FL [mm]	HUM [mm]	EFW	GP
06/30/2006	12 + 1	18.0	GP
08/01/2006	16 + 5	32.0	125.0	101.0	19.0	20.0
08/31/2006	21 + 0	51.0	191.0	165.0	37.0	34.0	437g , 0 lbs 15 ozs	76%

Fetus 2

Date	GA	BPD [mm]	HC [mm]	AC [mm]	FL [mm]	HUM [mm]	EFW	GP
06/30/2006	12 + 1	16.0	GP
08/01/2006	16 + 5	30.0	110.0	95.0	18.0	19.0
08/31/2006	21 + 0	44.0	176.0	145.0	32.0	29.7	319g , 0 lbs 11 ozs	7%



Sonographer: D. Bradley _____

Physician: Dr. Williams _____