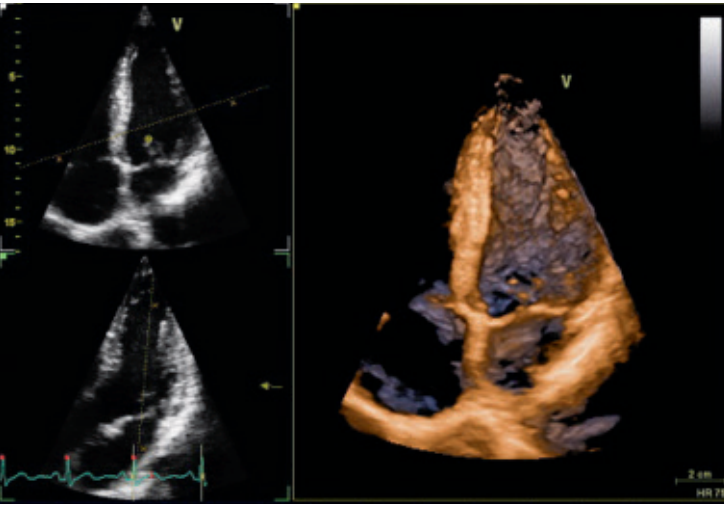
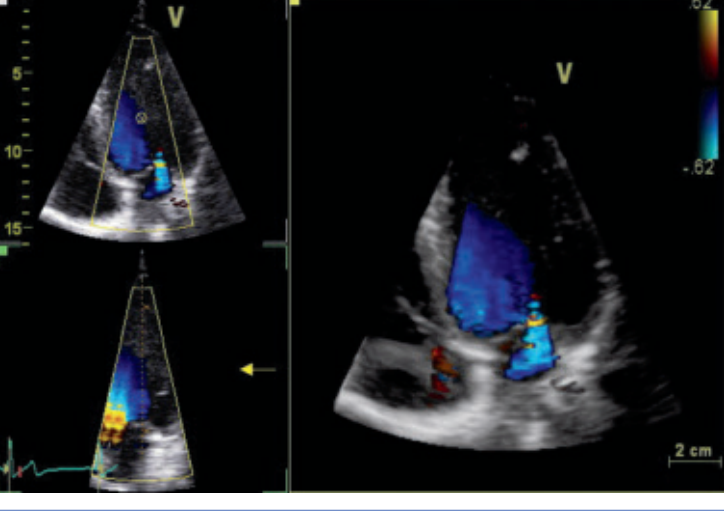
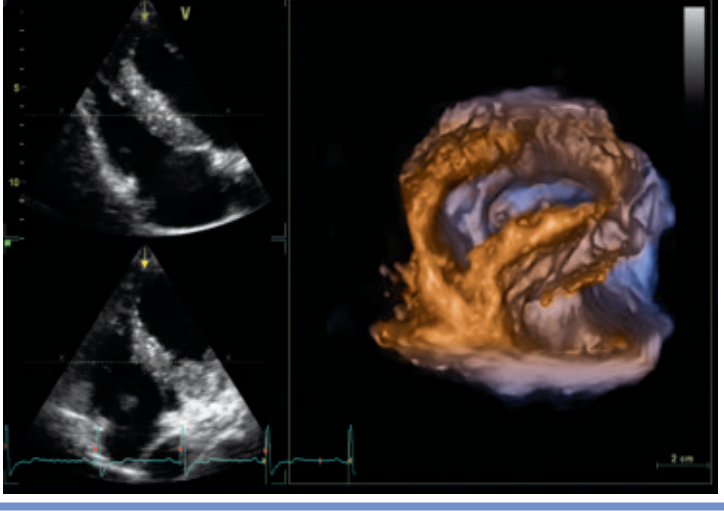
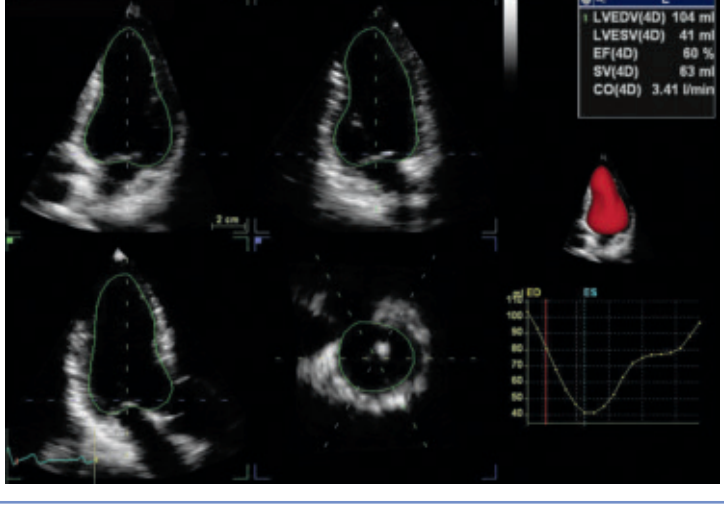
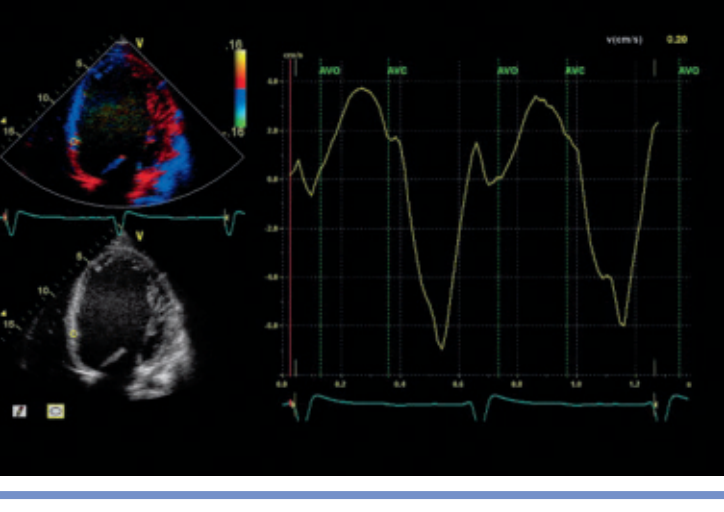
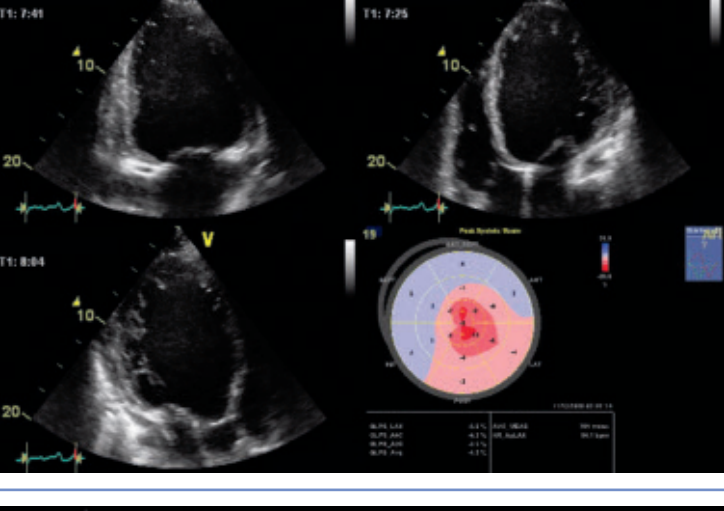
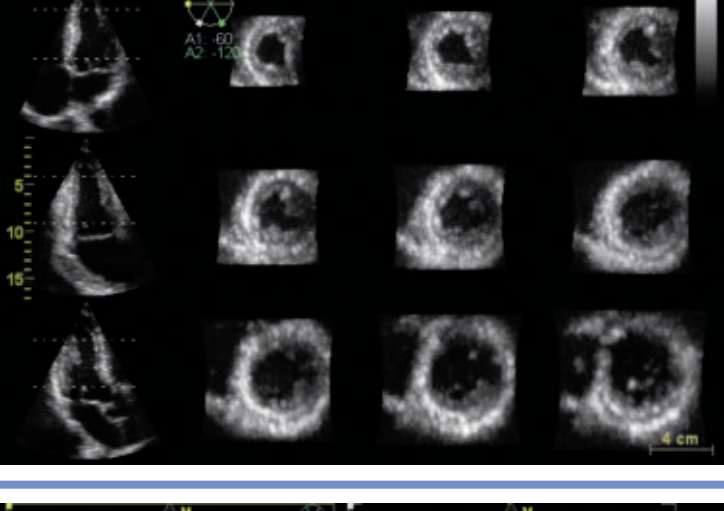
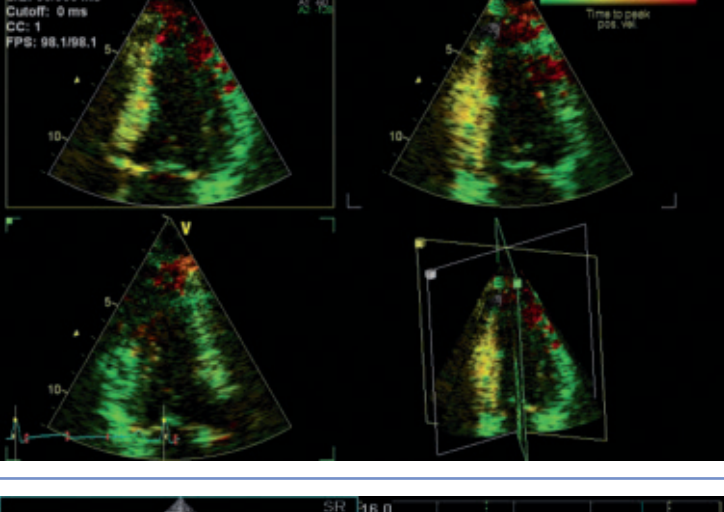
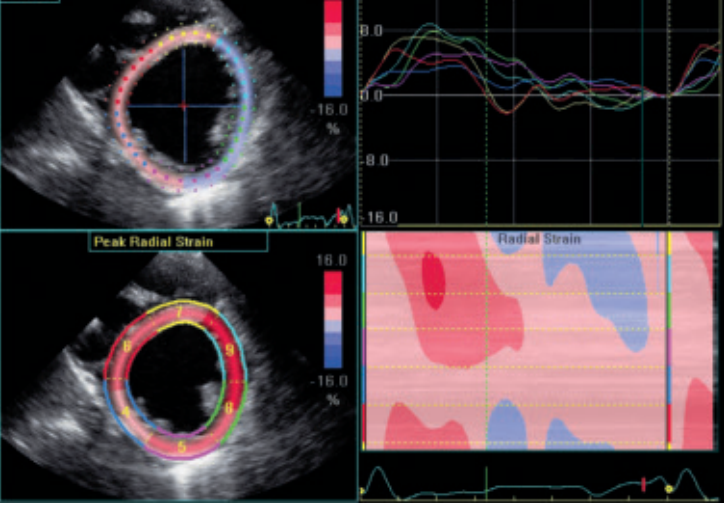
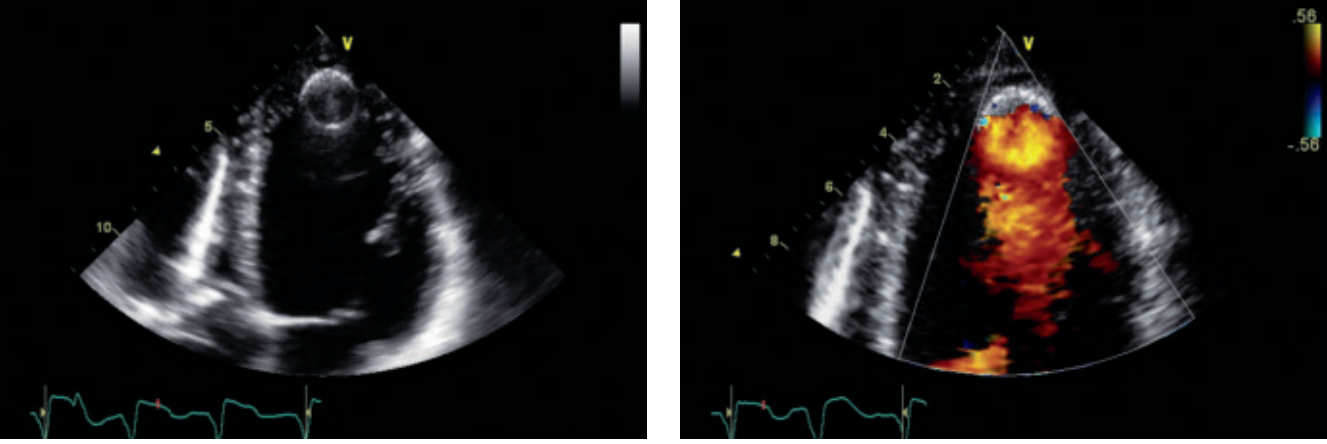


Echocardiography for heart failure

Echocardiography plays an important role as a diagnostic imaging tool for evaluation of patients for heart failure.

The clinical pathway includes diagnosis, evaluation of etiology, guiding treatment and medical management.

Utilization of Echo	Clinicals	GE feature	Clinical application for heart failure
Diagnosis – shape and size		Flexi-Volume 4D	Initial evaluation includes assessing the size and shape of the heart. A volume dataset with Flexi-Volume 4D will assess LV morphology. Utilizing the slice mode, measurements of the left ventricular internal dimensions, wall thickness, right ventricular dimensions and left atrial dimension can be obtained from a 4D dataset.
		4D Color flow	4D Color flow will visualize regurgitant volumes. Quantification of the regurgitant volume can be obtained with a 4D dataset. Examples include: vena contracta, flow convergence and proximal isovelocity surface area (PISA).
Diagnosis – right heart failure		RV Volume	Quantification of right ventricular ejection fractions (EF), end-diastolic volume (EDV) and end-systolic volume (ESV) from a 4D dataset.
Determine classification of systolic dysfunction vs. diastolic dysfunction		4D Auto LVQ	Clinicians need an accurate LV EF and volume. Various publications have demonstrated the accuracy of volumes obtained by 4D. 2D volumes use a geometric assumption. 4D Auto LVQ (left ventricular quantification) measurement will quantify ejection fraction (EF), end-diastolic volume (EDV) and end-systolic volume (ESV).
		Tissue Velocity Imaging	Common measurements for quantification of diastolic function include (but are not limited to) Tissue Velocity Imaging.
Determine classification of ischemic vs. non-ischemic		Automated Function Imaging	Quantification of left ventricular function. Peak global and regional systolic strain.
		4D Stress echo – (Pharm peak level 12 slice is shown)	Stress echo is frequently used to assess regional left ventricular function. Quantification is an advantage with 4D Stress; the 4D Auto LVQ is available at any stage in the stress.
Guide treatment and advanced therapy assessment		Tri-plane Tissue Synchronization Imaging	Quantification of regional time-to-peak longitudinal velocity. Evaluation of intraventricular dyssynchrony. TSI is based on time velocity data. It assigns a color to the tissue according to the amount of delay. Multi-plane TSI allows the user to acquire three planes simultaneously from the same cardiac cycle.
		2D Strain	Quantification of regional time-to-peak radial velocity. Evaluation of intraventricular dyssynchrony.
		2D Mode, Color flow	Evaluation and visualization of advanced therapy such as a left ventricular assist device (LVAD).