

Improving Breast Diagnosis Using High-Resolution MRI

By Dr. Daniel J. White, M.D.

Director, Magnetic Resonance Mammography Mount Carmel Hospital System

Medical Director, Mount Carmel Imaging Center

Senior Partner, Radiology Inc.

Introduction

The role of Magnetic Resonance Imaging (MRI) in breast diagnosis is evolving as technology improves and clinical experience with new techniques expands. In the past four years, the number of breast MRI exams performed annually in the U.S. has more than quadrupled, as compared with a 23 percent increase in MRI exams overall. This tremendous growth is due not only to more widespread acceptance of breast MRI as a problem-solving tool outside the university hospital setting, but also to the recognition that breast MRI may be clinically useful in other contexts as well. Additionally, improvements of commercially available breast MR imaging techniques is driving greater acceptance of the technique in busy clinical settings.

Mount Carmel Breast MRI Program

The Mount Carmel hospital system is composed of three main hospitals in Columbus, Ohio as well as several outpatient imaging centers. Breast MRI is performed using GE Signa® HD 1.5T scanners (GE Healthcare; Waukesha, WI) at four locations. Image data is transmitted to one of two reading stations, both equipped with computer aided detection (CAD) computers. The interpretations are provided by one of three dedicated radiologists who are part of a 47-member private practice radiology group. All three have fellowship training in MRI and are also actively reading mammograms as part of our general practice. Each radiologist began by attending a dedicated breast MRI program to learn the pathophysiology and basic interpretive skills of breast MRI. The number of radiologists interpreting breast MRI has been limited by design to maintain an adequate number of cases per reader to assure interpretive expertise. Since introducing breast MRI into our practice four-and-a-half years ago, we have seen our breast MRI caseload grow from two to three cases per month to our current rate of four to eight cases per day. We have imaged approximately 2,000 patients to date.

MR Breast Imaging Using VIBRANT

At Mount Carmel hospitals, all breast MRI exams are performed on GE Signa 1.5T scanners with a variety of software platforms and gradient performance. We use a variety of coils including 4-channel, 7-channel and 8-channel phased array

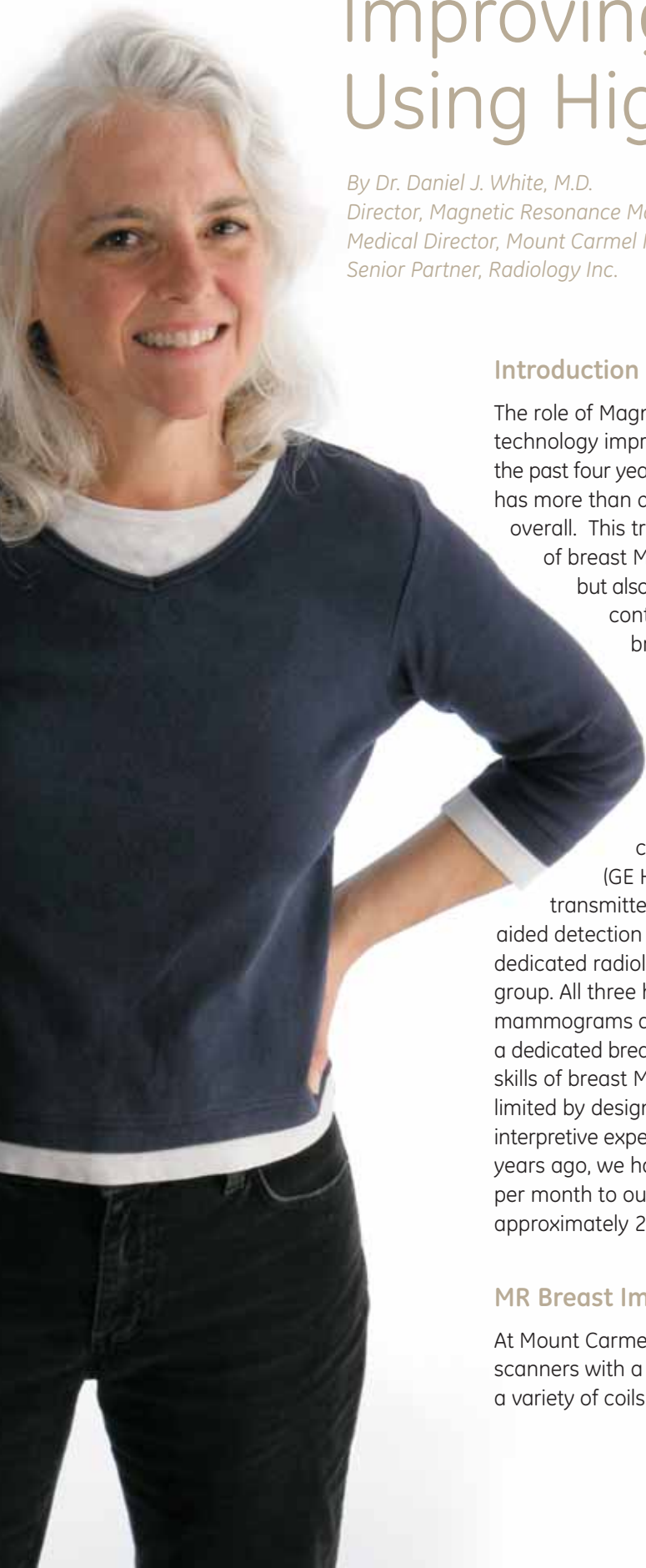

Table I. Mount Carmel East Imaging Center – Breast MRI Protocols

1) Standard 2D T1 Gradient

- 3 plane loc, slice 7mm/gap 5mm
- Axial 2D, T1 gradient, slice 4.0/0.0, matrix 256 x 160, FOV~34. One pre-contrast and 5 post sequences are run in one series.
- Coronal FSE T1 (no fat sat), slice 2.0/0.0 (may need to increase to 4.0 depending on pt size)
- Axial 3D fat sat SPGR, slice 2.0/0.0, matrix 256 x256, FOV~34
- Axial STIR, slice 4.0/0.0, matrix 224x224, FOV~34
- Axial FSE T2 (no fat sat), slice 2.0/0.0, 224 x 224, 34

2) Sagittal VIBRANT

- 3 plane loc, 7.0/5.0
- Axial calibration scan, slice 8.0/0.0, FOV 48
- Sagittal VIBRANT, slice 4.0/0.0 (ZIP2 to effective 2.0 mm slice thickness), matrix 224 x224 (ZIP 512). One pre-contrast and five post-contrast acquisitions simultaneously of both breasts.
- Axial VIBRANT, slice 2.6/0.0, matrix 350 x350, FOV~38-40. One delayed post-contrast acquisition.
- Axial FSE T1 (no fat sat), slice 2.0/0.0, matrix 224 x 224, FOV~34
- Sagittal FSE T2 (no fat sat) Left breast, slice 2.0/0.0, 224 x 224, FOV=24
- Sagittal FSE T2 (no fat sat) Right breast, slice 2.0/0.0, 224 x 224, FOV =24
- Axial STIR, slice 4.0/0.0, 256 x 192, FOV~38

3) Axial VIBRANT

- 3 plane loc
- Cal scan
- Axial VIBRANT, slice 2.6/0.0 (ZIP 2 to effective 1.3mm), 350 x 350 (ZIP 512), FOV~40. One pre-contrast and five post-contrast acquisitions.
- Sagittal VIBRANT, slice 4.0/0.0 (ZIP 2), 224 x 224, FOV~24
- Axial T2 FSE (no fat sat), slice 2.0/0.0, 224 x 224, FOV~34
- Coronal FSE T1 (no fat sat), slice 2.0/0.0 (may need to increase to 4.0 depending on patient size)
- Axial STIR, slice 4.0/0.0, 256 x 192, FOV~34

breast coils. Due to differences in scanner capabilities at our four breast MRI facilities, we utilize a range of techniques from basic 2D T1-weighted gradient echo imaging relying on subtraction techniques to assess enhancement, to more sophisticated 3D axial and sagittal fat saturated imaging using VIBRANT™ (See Table I for detailed protocol descriptions).

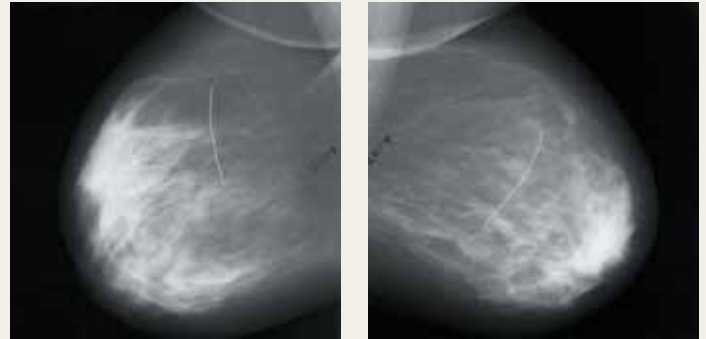VIBRANT is a specialized breast imaging pulse sequence recently developed by GE. The sequence is based on a fast 3D gradient echo sequence with T1-weighting and fat suppression, and has special modifications to optimize the image quality for breast imaging. With VIBRANT, parallel imaging may be applied to an axial or a sagittal volume. If a sagittal volume is defined, the parallel imaging acceleration is applied along the slice axis of the volume, i.e. in the L/R direction, to obtain true sagittal images without prolonging

scan time. Regardless of which orientation is used to acquire the images, reformatted images may be obtained from the acquired volume in any orientation, but with the proviso that the spatial resolution is significantly lower along the slice direction.

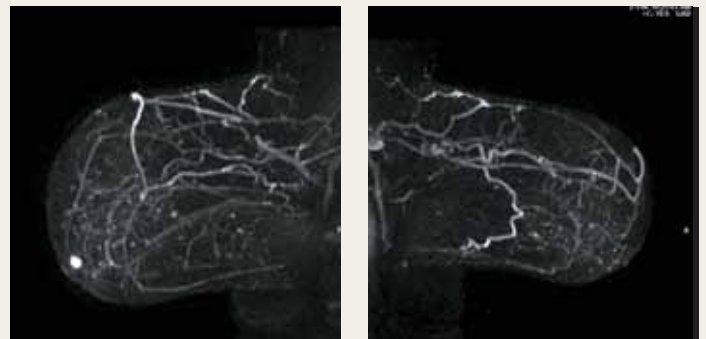
Case 1

63-year old female with left breast pain, heterogeneously dense breast tissue and a strong family history of breast cancer. Earlier mammograms revealed a focal asymmetric density in the superior region of the left breast, considered to have a benign appearance, and calcifications in the anterior superior region of the right breast. MR exam showed no abnormal enhancement in the left breast but revealed a 9 x 7 mm nodule of abnormal early contrast enhancement in the immediate subareolar right breast, demonstrating pronounced early enhancement with washout kinetics.

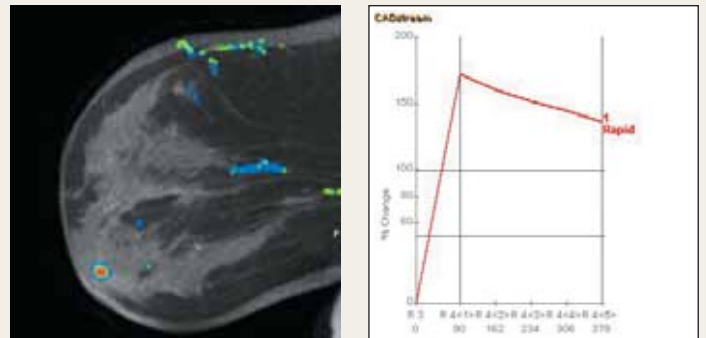
Subsequent biopsy revealed invasive carcinoma with adjacent low-grade ductal carcinoma (cribriform type). Histologic analysis of the mastectomy specimen showed a 0.7 x 0.6 cm area of residual carcinoma adjacent to the 2.5 cm biopsy cavity.



Right and left MLO view mammograms



One minute subtraction MIP images



Right breast, one minute fat saturated image with color parametric enhancement map (on left) and enhancement curve.

All imaging protocols, regardless of scanner performance, were designed to provide simultaneous, dynamic imaging of the breasts bilaterally (< 80 seconds per acquisition, optimally 60 to 70 sec.). Except in the case of prior mastectomy, we feel it is critical to image both breasts simultaneously for all studies.

Image Analysis Using a CAD System

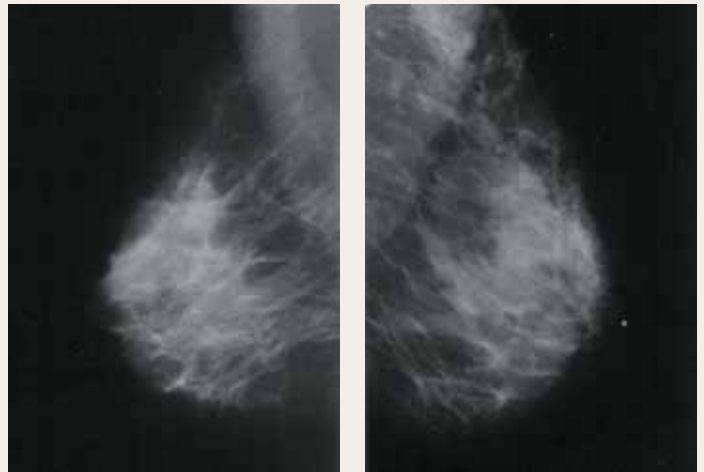
We have found the use of a computerized automated detection system to be an essential component of our breast MRI program. We began our program without a computer-aided detection (CAD) system, evaluating enhancement kinetics by manually placing regions of interest and attempting to correlate multiple pulse sequences. This was slow, labor intensive and often less accurate. Any minor error in the region of interest positioning can significantly change an enhancement kinetic curve. We would never go back to that method. Our CAD system, CADstream™ (Confirma, Inc; Kirkland, WA), has improved our interpretation speed by organizing and correlating the 1,200 to 1,500 images that we produce with each study. We believe that CAD also improves our accuracy through voxel-by-voxel evaluation of enhancement kinetics, motion correction algorithms and generation of color parametric overlays. Although we feel an exam should never be “read by color,” the color mapping serves to draw your eye to regions or lesions requiring further evaluation.

Conclusions

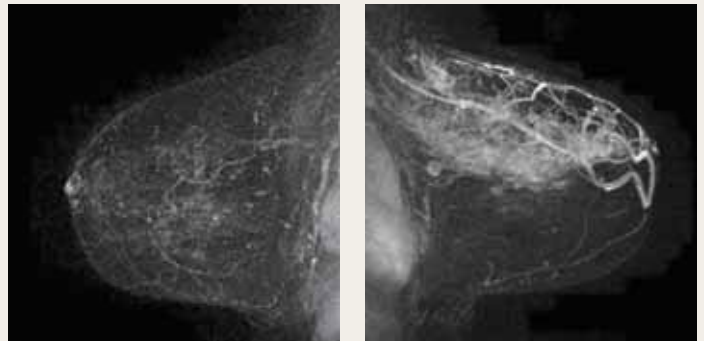
Breast MRI is an essential component of the comprehensive breast care program at our facilities. Over the past four-and-a-half years since we introduced breast MRI into our practice, the number of exams per year has increased and continues to increase dramatically. When performed correctly, in the context of a dedicated breast MRI program, this imaging modality frequently results in improved patient care. As more physicians experience this first-hand with their own patients, they begin to incorporate this exam more often into their patient care algorithms. We consider breast MRI a critical component in our approach to breast imaging, and use it routinely for a variety of problem-solving scenarios to greatly increase the clinician’s or surgeon’s confidence. The results are excellent, often providing critical information for determining the appropriate course of patient care. We feel that breast MRI technology has attained a degree of maturity that allows it to be effectively incorporated into a busy breast imaging practice. ■

Case 2

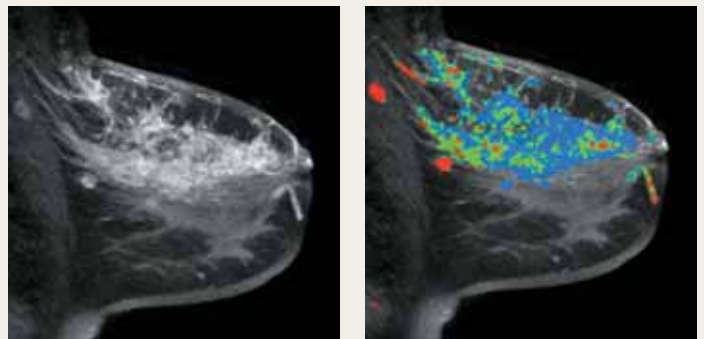
40-year-old woman presented with a palpable lump in her left breast. Mammography revealed dense breast tissue throughout the breasts and an irregularly-shaped asymmetric neo-density in the left breast at the site of the palpable lump. Asymmetric tissue was also noted in the axillary tail of the left breast, unchanged from prior management. Ultrasound confirmed a 14 x 12 x 9 mm irregularly shaped hypoechoic solid-appearing mass showing posterior acoustic shadowing at the location of the palpable lump. A biopsy revealed infiltrating ductal carcinoma in a background of DCIS. MRI demonstrated a dramatic asymmetric enhancement, involving the entire upper outer quadrant of the left breast. Histologic analysis of the left mastectomy specimen demonstrated multi-focal, multi-centric infiltrating ductal carcinoma with the largest tumor nodule measuring 1.4 cm corresponding with the palpable mass. Intervening DCIS filled the upper outer quadrant.



Right and left MLO view mammograms



One minute subtraction MIP images



A one minute fat saturated image of the left breast; same image with a color parametric map of the enhancement.