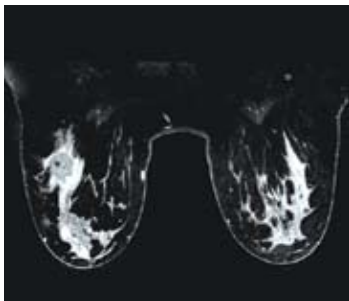


Increased Diagnostic Confidence with GE Signa HDx 3.0T MRI for Breast Imaging

Stepping Up to 3.0T

Since the early 1990s, Dr. Weinreb has collaborated with mammographers and with pathologists on diagnoses. He regards MR as a valuable complement to mammography screening and ultrasound examinations that can reveal areas of suspicion.



3T Bilateral Breast MRI

“We also use MR for women in whom the mammogram is completely normal,” Dr. Weinreb says. “These are patients who are at high risk because they have a genetic predisposition or a strong family history of breast cancer, have had breast cancer before, or have received radiation treatment for Hodgkin’s disease.” This coincides with the new guidelines released by the American Cancer Society in March 2007, which recommends MR for high-risk patients.

In 2005, Yale New Haven Hospital installed the GE Signa® HDx 3.0T MR system, adding to a department that already included four GE Signa 1.5T systems. The Signa HDx 3.0T scanner – the latest in MR technology – is equipped with high definition technology, such as the GE HD 8-channel breast coil and VIBRANT™, an exclusive GE application that enables fast, high-resolution bilateral breast imaging. GE’s complete Breast MRI solution, which also includes a breast-specific spectroscopy application, BREASE™, and unique integration with Confirma™ Inc. (Kirkland, WA) to provide an industry-leading CAD analysis product, CADstream™, is unmatched in the industry.

Bilateral imaging saves patients the inconvenience of having two separate Breast MRI exams. For clinicians, it eliminates the need to choose between scanning for structural detail and scanning rapidly for uptake information. It provides rapid imaging without compromising in-plane resolution. VIBRANT also allows the choice of direct sagittal or axial imaging and automatically optimizes parameters, making it easy for technologists to deliver consistent image quality. Specifically, a strength of VIBRANT is a unique bilateral shim method, which results in homogenous fat suppression over both breasts.

“Having worked in breast MR using 1.5T scanners for about 15 years, I had a good idea what the capabilities and limitations were,” says Dr. Weinreb. “With the added signal and other capabilities of 3.0T, I believed we could move breast MR to a higher level. We have translated the higher signal strength of 3.0T into higher spatial resolution, which enables us to see finer detail in the images.”

“I can’t say it increases diagnostic confidence on every single case. But we certainly have had cases where at 1.5T we were not quite sure what we were dealing with and 3.0T definitely gave us additional confidence.”



A GE Signa HDx 3.0T MR scanner helps Yale New Haven Hospital deliver more definitive diagnoses

Jeffrey Weinreb, M.D., FACR, believes the future of Breast MRI imaging belongs to 3.0T MR technology.

Dr. Weinreb, Chief of MRI and Director of Medical Imaging Services at Yale New Haven Hospital, uses the Signa HDx 3.0T system extensively for breast studies and finds that it sometimes provides information that is useful in making a diagnosis. In some cases, its higher spatial resolution provides crucial information that is not attainable at 1.5T.



An Urgent Health Issue

Breast cancer remains a leading cause of premature death in women. The American Cancer Society (ACS) reports that breast cancer is the most common cancer among women, other than skin cancer, and is the second leading cause of cancer death in women, after lung cancer.

Approximately 178,480 women in the United States will be found to have invasive breast cancer in 2007, the ACS estimates. At present, slightly more than two million women living in the United States have been treated for breast cancer.

The chance of a woman having invasive breast cancer at some time during her life is about 1 in 8. The chance of dying from breast cancer is about 1 in 33. Breast cancer death rates are going down. The decline is probably the result of finding the cancer earlier and improved treatment.

Imaging Challenges

- 1 in 3 breast cancer patients has undiagnosed multi-focal disease.
- 1 in 20 breast cancer patients has undiagnosed bilateral disease.



Seeing Both Sides in One Exam

Dr. Weinreb prefers bilateral breast studies and finds the VIBRANT application extremely helpful. "In the past, bilateral exams were technically challenging, because it was difficult to get uniform fat suppression over both breasts," he says. With VIBRANT and bilateral shimming, it is no longer a challenge to achieve uniform fat suppression. This has tremendous value versus other breast MR imaging applications in the industry.

VIBRANT is a 3D, fat-suppressed, T1-weighted technique used for dynamic scans. "With VIBRANT, we can get good, uniform fat suppression across the entire field of view," Dr. Weinreb says. "There are two benefits of a bilateral exam. First, we can find suspicious areas in the other breast that were totally unsuspected. Second, we can compare the breasts. Symmetry is very important. We might see something in one breast that looks suspicious, but if we see exactly the same thing in the other breast, our suspicion drops significantly."

The typical protocol for 3.0T breast studies is to perform a T2-weighted, fat-suppressed scan in the sagittal or axial plane, then a series of T1-weighted non-fat-suppressed images. "We do that because, very commonly, there are little enhancing nodules in the breast," Dr. Weinreb says. "They can enhance very intensely, and we don't know if they're benign or malignant. With the non-fat-suppressed T1-weighted images, if we see bright fat in that nodule, we know it's an intra mammary lymph node and we don't have to worry about it. That has prevented us from recommending unnecessary biopsy in a lot of patients."

"Our real workhorse sequence is VIBRANT. It's a fat-suppressed 3D scan, and we do it with a temporal resolution of less than two minutes. Although, with 3.0T technology and higher acceleration factors, we have the flexibility to select temporal resolution as low as 30 seconds while maintaining adequate image quality. However, based on published literature, we favor higher spatial resolution to achieve greater specificity. In our current protocol, we acquire a true isotropic voxel of 1mm, meaning there is no interpolation, with a temporal resolution of 90 seconds. For the dynamic scan, we generate datasets once prior to and three times after uptake. We used to do this in the sagittal plane, followed by a delayed high-resolution axial scan with VIBRANT. More recently, we have been performing the bilateral VIBRANT exams in the axial plane which allows us to achieve even higher spatial resolution and facilitates comparisons of the breasts."

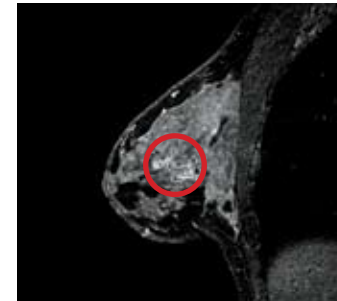
An automatic subtraction feature provides a valuable aid to diagnosis: It makes it easier to identify subtle or small areas of enhancement. "The first thing we look at is the first set of subtracted images," Dr. Weinreb says. "Then we go back to the other images just to validate what is enhancing, and also to look at other characteristics."

Cases in Point

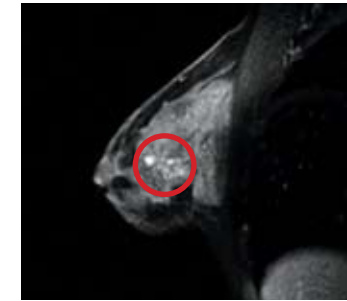Dr. Weinreb cites three cases in which the GE Signa HDx 3.0T made a difference in diagnosis.

Non-mass Enhancement: Comparison 3.0T/1.5T

A 54-year-old patient whose mammogram showed a focal asymmetric density was imaged at 1.5T. The images (right) showed a small, slightly irregular enhancing mass, and posterior to that an abnormal area of non-mass enhancement. "The findings were non-specific", Dr. Weinreb says. A follow-up 3.0T scan using VIBRANT, six months later, shows clustered ring enhancement, a finding that is highly suggestive of DCIS.



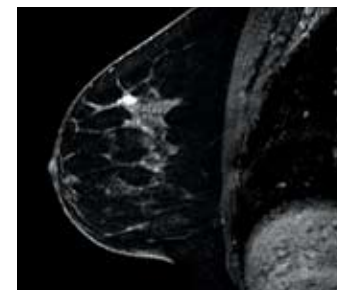
3.0T
2.0mm sl th
256 x 256 FOV 18
Voxel 2.0 x .7 x .7



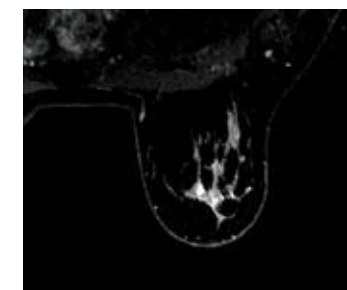
1.5T
3.0mm sl th
256 x 160 FOV 18
Voxel 3.0 x 1.1 x .7

Benign Fibroadenoma: Comparison 3.0T/1.5T

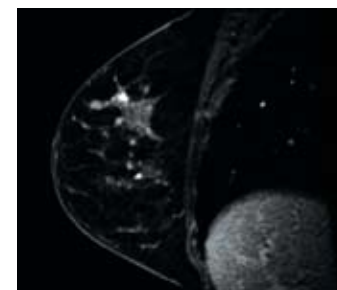
An MR study was performed for a 42-year-old patient who had a mastectomy on the left side for breast cancer and so was at high risk for the disease. Images from an exam at 1.5T show a bright area of enhancement that cannot be clearly evaluated. Dynamic images from a 3.0T scan using VIBRANT with higher spatial resolution show that the growth has smooth lobulated margins and an internal non-enhancing septation, a finding highly suggestive of benign fibroadenoma.



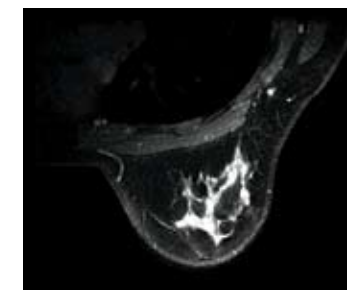
3.0T



1.0mm sl th



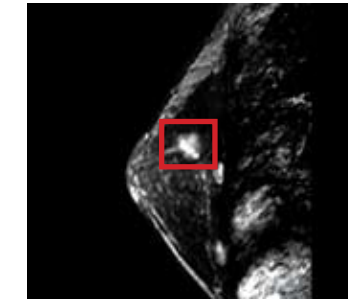
1.5T



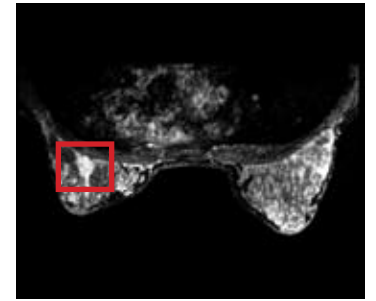
1.5mm sl th

DCIS: 3.0T BREASE Exam Showing a Choline Peak

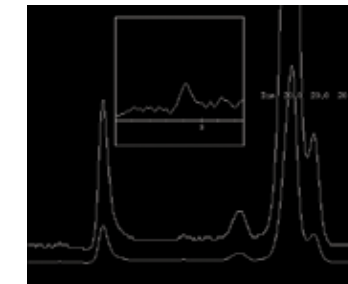
BREASE is a breast-specific spectroscopy application that is designed to enhance diagnostic confidence. It is a proton spectroscopy application optimized specifically for the breast that uses a signal detection technique to show elevated concentrations of choline. BREASE is a TE-averaged, PRESS spectroscopy acquisition compatible with a 4-, 7-, or 8-channel breast coil.



Sagittal VIBRANT

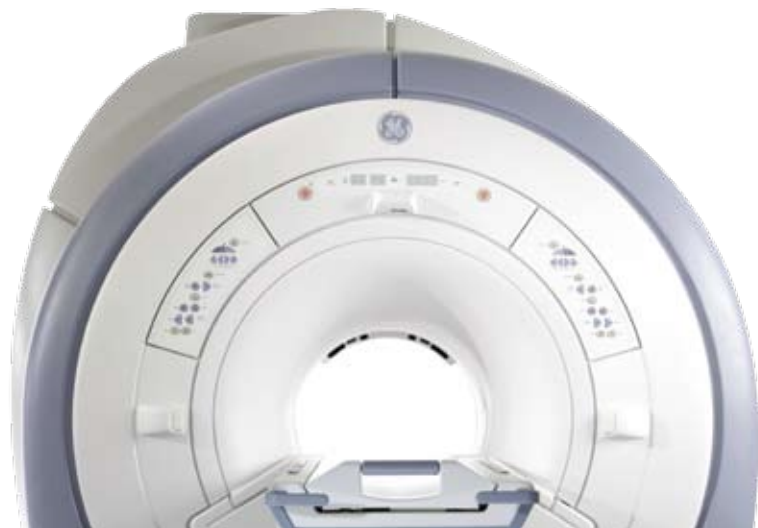

Axial VIBRANT



BREASE Spectrum Showing a Choline Peak

Voxel 20mm x 20mm x 20mm
Scantime: Approx. 5 minutes



© 2007 General Electric Company – All rights reserved. GE and GE Monogram are trademarks of General Electric Company

Signa is a registered trademark, and VIBRANT and BREASE are trademarks of GE Healthcare.

CADstream and Confirma are trademarks of Confirma, Inc.

General Electric Company, doing business as GE Healthcare.

Healthcare Re-imagined

GE is dedicated to helping you transform healthcare delivery by driving critical breakthroughs in biology and technology. Our expertise in medical imaging and information technologies, medical diagnostics, patient monitoring systems, drug discovery, and biopharmaceutical manufacturing technologies is enabling healthcare professionals around the world discover new ways to predict, diagnose and treat disease earlier. We call this model of care “Early Health.” The goal: to help clinicians detect disease earlier, access more information and intervene earlier with more targeted treatments, so they can help their patients live their lives to the fullest. Re-think, Re-discover, Re-invent, Re-imagine.

GE Healthcare
3000 North Grandview Blvd
Waukesha, WI 53188
U.S.A.
www.gehealthcare.com



imagination at work