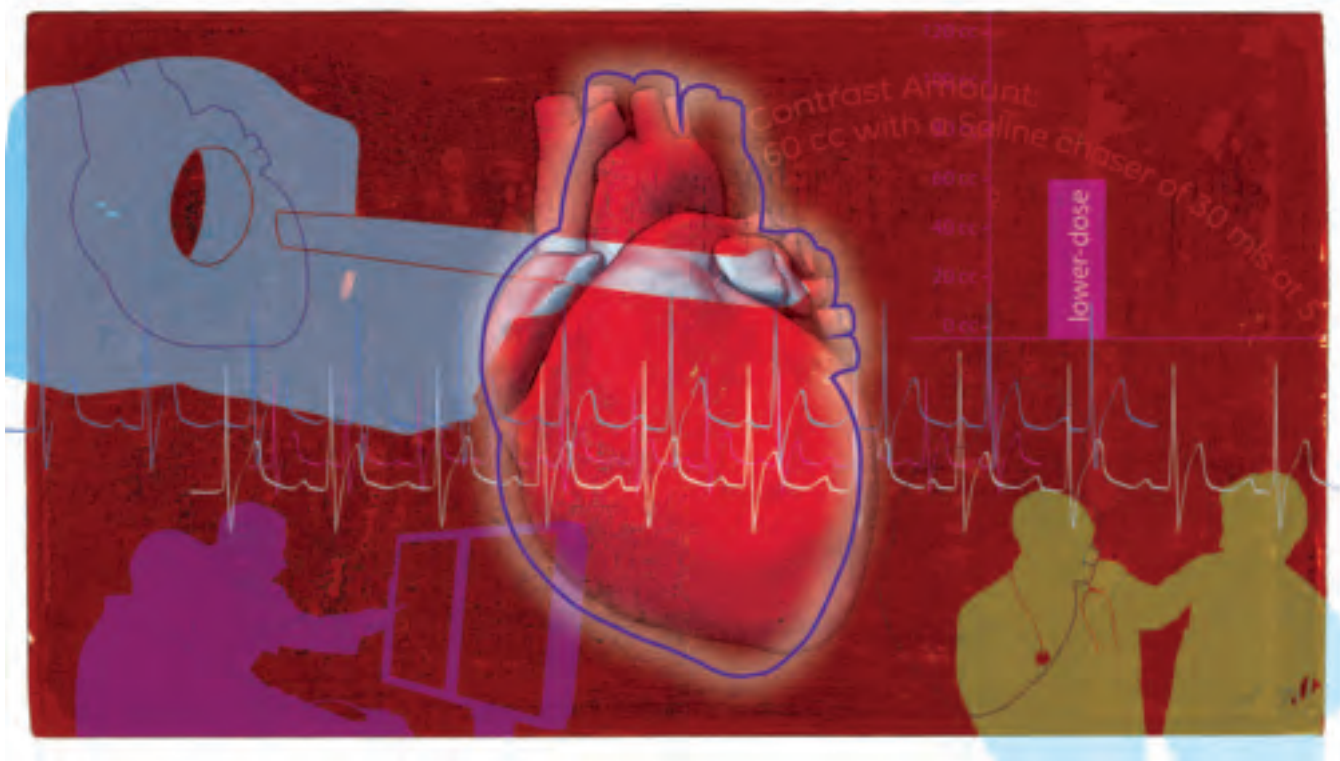


# A Promising New Tool for Myocardial Evaluation

By Erasmo de la Peña-Almaguer, MD, FACC, Director, Cardiovascular Imaging Center, Cardiac and Vascular Diseases Institute, Hospital San José, Tec de Monterrey



## Patient history

The patient presented with atypical chest pain six months after having undergone a dual stent placement for a chronic total occlusion of the RCA.

An acute obstruction of the LAD with presence of thrombus was also present.

A moderate lesion of the first diagonal was also present but treated with medical therapy.

A coronary CT angiography (CTA), 3T Stress MR Perfusion using Fiesta and MDE, and a rest-stress MIBI was performed.

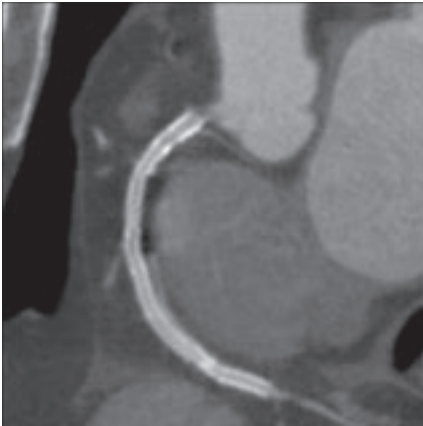


Figure 1. RCA

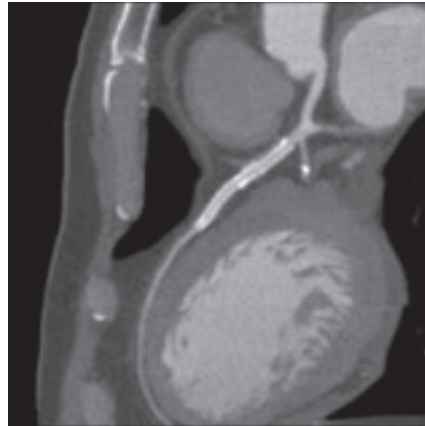


Figure 2. LAD

## Acquisition protocol

Scanner .....	LightSpeed® VCT
Slice thickness .....	64 x 0.625 mm
Pitch .....	0.2:1
Rotation time .....	0.35 sec
mA .....	739
kVp .....	12
Recon kernel .....	Detail
SFOV .....	Large
Heart rate .....	55 bpm

## Contrast protocol

Injection rate .....	5 cc/sec
Contrast amount ....	60 cc with a Saline flush of 30 mls at 5 cc/sec

## Background

To assess viability and detect ischemia in the area of the first diagonal, a comparison study was done with rest-stress MIBI and stress MR.

In addition, the patient underwent a prescribed contrast-enhanced coronary CTA on a GE Healthcare LightSpeed VCT scanner. The exam was immediately processed and reviewed on a GE Advantage Workstation® equipped with CardIQ™ Xpress 2.0 Elite.



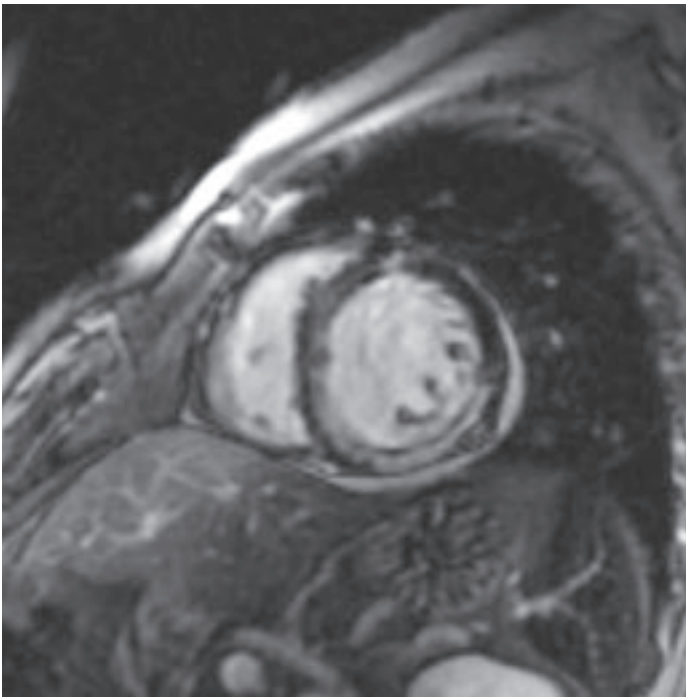
Erasmio de la Peña-Almaguer, MD, FACC, Director, Cardiovascular Imaging Center, Cardiac and Vascular Diseases Institute, Hospital San José, Tec de Monterrey, Mexico is a clinical cardiologist with post-doctoral training in cardiovascular imaging. He is trained in multiple areas of cardiovascular imaging, including nuclear medicine, MR, and CT. He studied at the Brigham and Women's Hospital, Harvard Medical School, and Stanford University Medical Center. He co-chairs the Latin American Chapter of the Society of Cardiovascular MR (SCMR) and is a reviewer for the International Journal of Cardiovascular Imaging (North American Society of Cardiac Imaging).

## Clinical findings

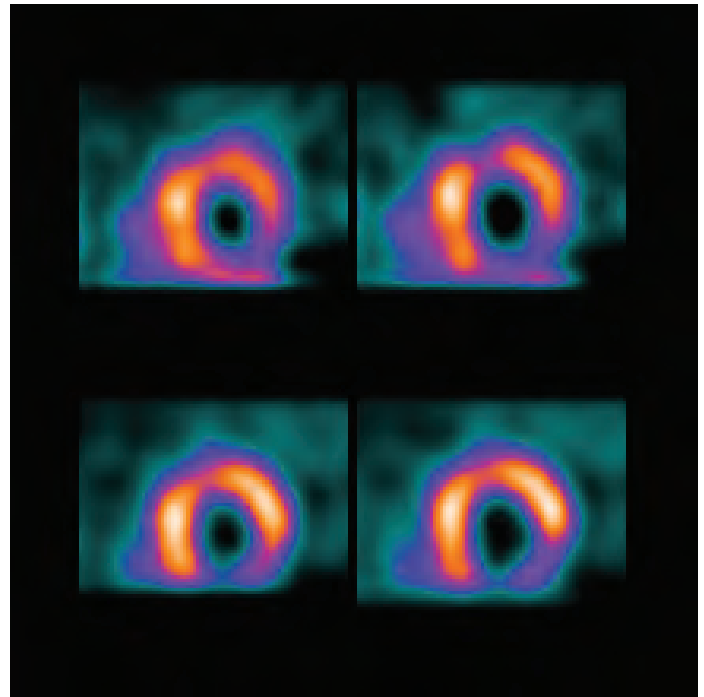
The rest perfusion tool helped us identify a non-transmural MI on the anterior wall as well as on the inferior wall in the area surrounding the LAD stent. This correlates well with the clinical data received from the MRI study.

## Advantages of using CardIQ Xpress 2.0 Elite

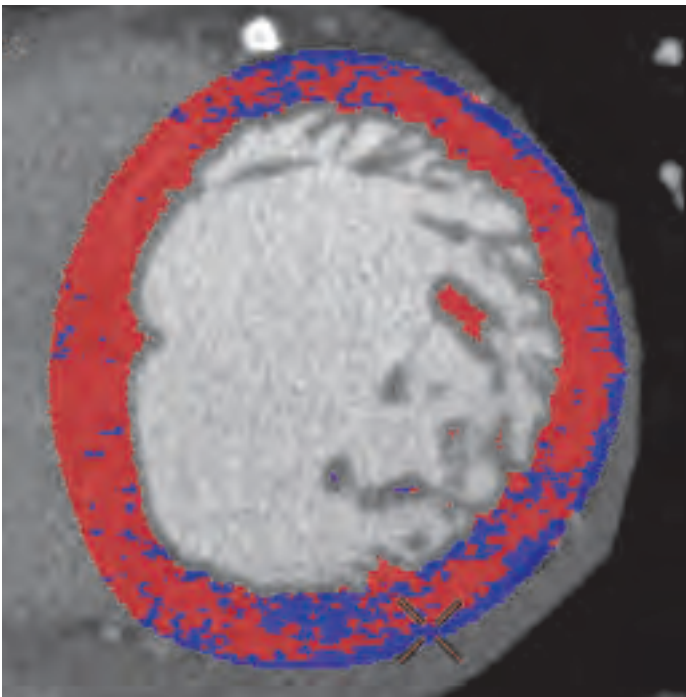
The application was used to assess the CTA data to analyze rest perfusion, a capability once available only via MRI and nuclear imaging. As this case demonstrates, CT rest perfusion is a promising technique for assessing areas of hypo-perfused myocardial tissue using a low-dose prospective technique. ■



**Figure 3.** Tesla rest perfusion MR using 3D FIESTA sequence. The MR shows a non-transmural MI in the inferior wall, combined with a small zone in the center of the anterior wall, underneath the zone of the stent (LAD Territory).



**Figure 4.** Rest MIBI perfusion showing the inferior wall and small anterior wall defects.



**Figure 5.** CT rest perfusion image obtained with CardIQ Xpress 2.0 Elite, showing region of interest as compared to MR and rest MIBI with delayed contrast enhanced MIBI.

...CT rest perfusion is a promising technique for assessing areas of hypo-perfused myocardial tissue using a low-dose prospective technique.

– Dr. Erasmo de la Peña-Almaguer, FACC