

# Multiple Colonic Polyps

Abraham H. Dachman, M.D.  
Director of Computed Technology  
The University of Chicago, Chicago, IL



# Multiple Colonic Polyps

Abraham H. Dachman, M.D.  
Director of Computed Technology  
The University of Chicago, Chicago, IL

## Patient History

This 61-year-old patient presented with anemia and no other signs or symptoms. CTC showed multiple polyps, which were confirmed at optical colonoscopy.

## Follow Up

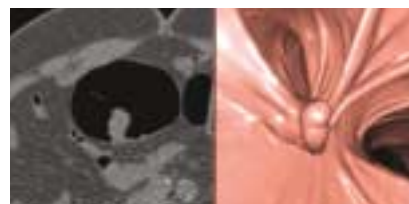
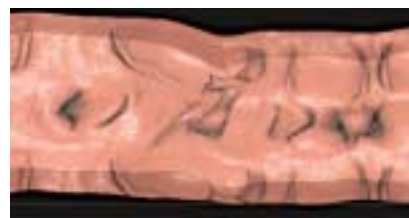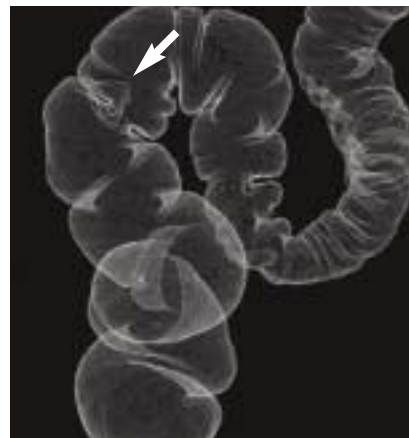The patient underwent polypectomy for several polyps. Histopathologic analysis of the polyps showed them to be tubular and tubulovillous adenomas.

## Protocol

Slice thickness	1.25 mm
Interval	1.25 mm
kV	120
MA	100
Rotation time	0.8 sec.
Algorithm	Soft
Total acquisition time	20 seconds

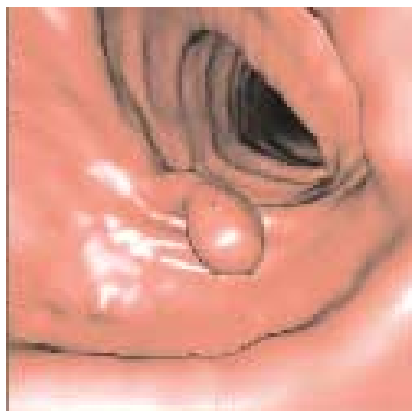
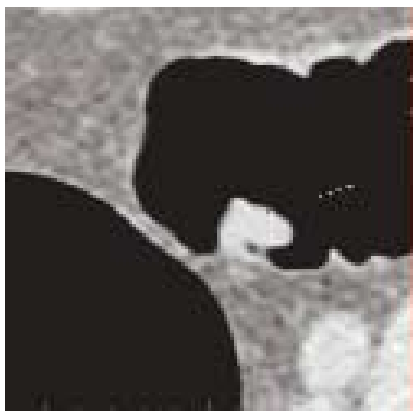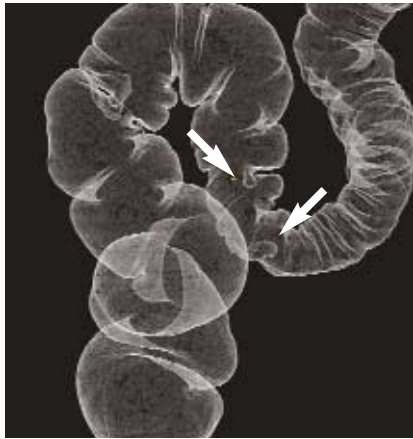
## Exam Comment

Thin patients are scanned with lower mA settings, often 50-64 mAs. On the 64-slice scanner, shorter breath holds of 10 seconds may be done, thus minimizing the risk of respiratory motion. The excellent distension seen here was achieved using carbon dioxide administered via a mechanical pump (maximum pressure 25 mmHg), but without the use of a spasmolytics drug.



## Sigmoid Mass

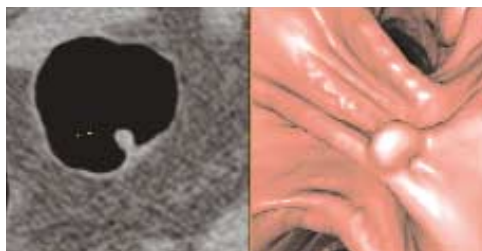
1.2 cm sigmoid polyp with a broad pedicle is well-seen on all views.



**Axial image**

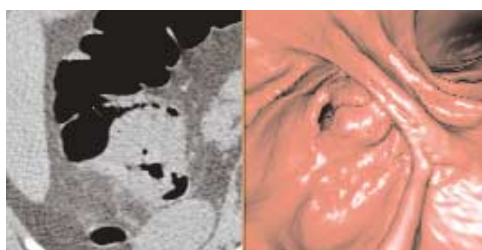
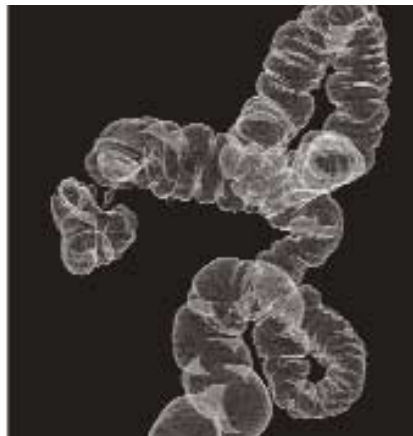A small pedunculated polyp is seen in the sigmoid colon. Some gas is trapped between the head of the polyp and the colon wall (arrow). This might lead the reader to mistake the polyp for stool; however the true nature of lesion, a pedunculated polyp, is easily discerned on the 3-D endoluminal Navigator view. The virtual 360-Dissection view shows a strip of colon and simultaneously shows a second polyp (#3) more proximally in the sigmoid colon

**Second Polyp seen**



The virtual 360-Dissection view provides a quick way to check behind folds for polyps that might be missed on an endoluminal fly through in one direction. The slightly elongated shape of the polyps on this view is an expected shape for which the reader should search. Problem-solving the virtual 360-Dissection view is very quick. Users can place the cursor over suspected polyps, depress the shift key, and have immediate point-to-point correlation with the 3-D endoluminal view and MPR views in 1-5 seconds. In this manner, the entire colon can be reviewed on the virtual 360-Dissection view, often in 60 seconds or less.

**Mass in Cecum**



General Electric Company reserves the right, subject to any regulatory approval if required, to make changes in specifications and features shown herein or discontinue the product described at any time without notice or obligation.  
Contact your GE Representative for the most current information.

©2005 General Electric Company - All rights reserved.  
GE and GE Monogram are trademarks of General Electric Company.

GE Medical Systems, a General Electric company,  
going to market as GE Healthcare.

GE Healthcare  
3000 North Grandview  
Waukesha, WI 53188  
U.S.A.

[www.gehealthcare.com](http://www.gehealthcare.com)



imagination at work