



Dr. Susan Roberts
Kingston Vale
London SW15 3RG

Exam Date: 03.12.2008

Extracranial Examination

Dear Dr. Roberts,

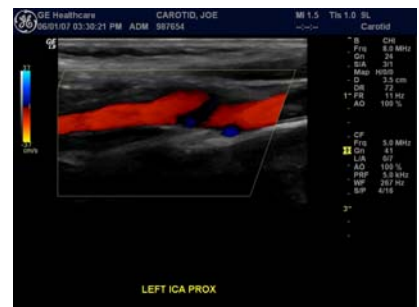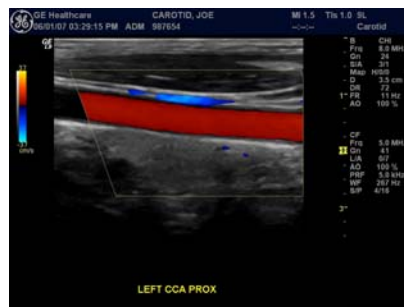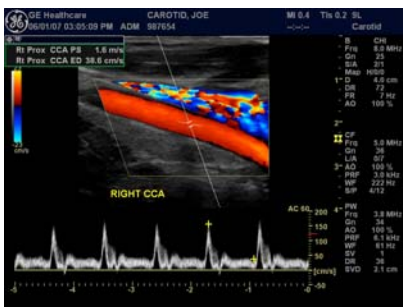
I have rescanned your patient **Fiona Test**, DOB 04.03.1943, Chestnut Ln. Wembley, Middlesex, HA0 4LL.

Results:

	Right		Left	
	PSV [cm/s]	EDV [cm/s]	PSV [cm/s]	EDV [cm/s]
CCA prox.	16	39	16	36
CCA mid.	11	31	12	32
CCA dist.			9	25
ICA prox.	91	34	73	33
ICA mid.	101	39	92	33
ICA dist.	117	52	99	48
ECA mid.	79	13	69	13
Vertebral mid.	109	22	70	24
Subclavian mid.	164	17	202	46
Ratio ICA / CCA	10,6		11,0	1,9
Vertebral artery	Antegrade flow		Antegrade flow	
Subclavian artery	Normal flow		Normal flow	

Report summary:

Normal flow conditions in the common carotid artery and and inner carotid artery. Antegrade flow in the vertebral artery on both sides.



Dr. Bradley

Dr. Williams