



Dr. Arthur Adkins
12 Lensfield Road
Cambridge CB2 1EH

Exam Date: 18.03.2008

Dear Dr. Adkins,

I have rescanned your patient **Julia Test**, DOB 10.10.1972, Fallowfield, Manchester.

Indication: Growth scan.

History:

Maternal age: 35 years. Pre-pregnancy weight 58,0 kg. Blood group: B, (Rh D), Rh -ve. Menstrual cycle regular - LMP unsure. Conception spontaneous on 02.09.2006. Pregnancy test: Positive. Non-smoker.

Obstetric History: Gravida: 2. Para: 1. Living children \geq 37W: 1.

Last period: 15.08.2007.

EDD by ultrasound: 21.05.2008 (EDD by dates: 25.05.2008).

Gestational age: 30 weeks + 4 days.

Fetal Wellbeing Scan:

Transabdominal and transvaginal US with GE Voluson E 8. Ultrasound view: Restricted by overlying bowel gas.

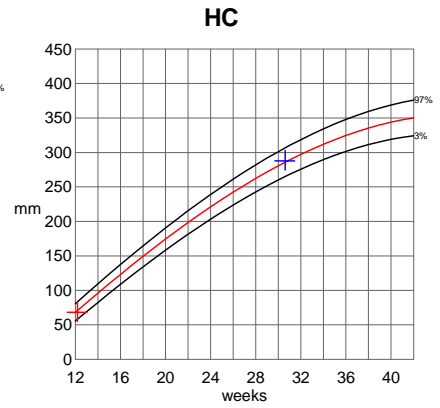
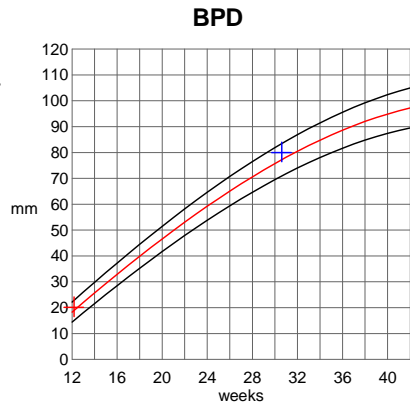
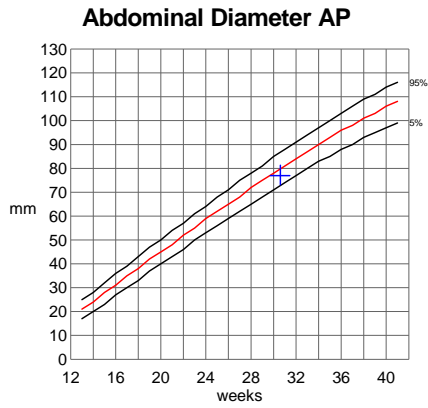
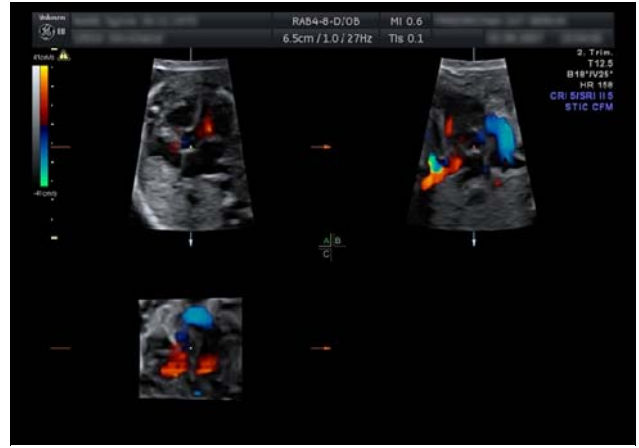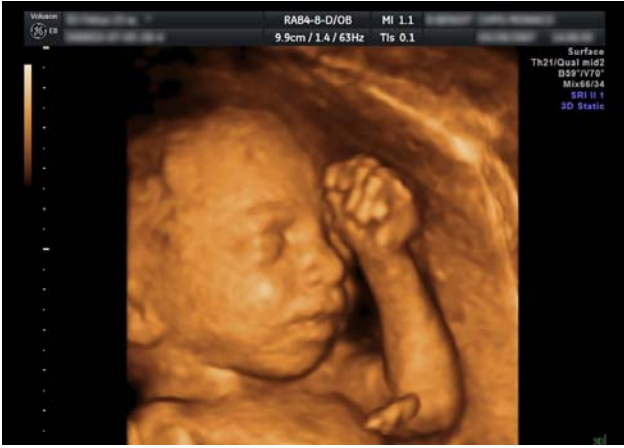Fetal Measurements (plotted in relation to the normal mean and 5th to 95th centile).

Biparietal diameter (BPD)	80,0	mm	81st%	
Occipitofrontal diameter (OFD)	103,2	mm	61st%	
Head circumference (HC)	287,8	mm	58th%	
Transcerebellar diameter (TCD)	35,0	mm	54th%	
Cisterna magna (CM)	7,2	mm		
Abdominal circumference (AC)	256,0	mm	50th%	
Femur length (FL)	59,2	mm	62nd%	
Est. fetal weight (Hadlock (BPD-AC-FL))	1697	g	55th%	
	3	lb(s)	12 ozs	

Heart action present. Presentation cephalic I. Amniotic fluid: Normal.

Placenta: Anterior high, structure normal.

Summary of ultrasound findings: Fetal growth according to gestational age.



Dr. Bradley