

**PRODUCT MONOGRAPH**

**VISIPAQUE  
(Iodixanol)**

**Solution for Injection  
550 mg/mL and 652 mg/mL**

**Non-ionic Radiographic Contrast Medium**

GE Healthcare Canada Inc.  
2300 Meadowvale Blvd.  
Mississauga, ON  
L5N 5P9

DATE OF PREPARATION:  
May 25, 2006

Control #: 106091

## **NAME OF DRUG**

VISIPAQUE  
(iodixanol injection USP)

VISIPAQUE 270  
(iodixanol injection USP 270 mg I/mL)

VISIPAQUE 320  
(iodixanol injection USP 320 mg I/mL)

## **THERAPEUTIC OR PHARMACOLOGICAL CLASSIFICATION**

Non-ionic radiographic contrast medium.

## **ACTIONS AND CLINICAL PHARMACOLOGY**

Immediately following rapid intravascular injection, VISIPAQUE (iodixanol) reaches peak plasma concentration and is then rapidly distributed throughout the extracellular fluid compartment. It will opacify those vessels in the path of flow of the contrast medium, permitting radiographic visualization of the vasculature of the internal structures until significant dilution and elimination occurs. The degree of density enhancement is directly related to the iodine content in an administered dose.

The lower osmolality of VISIPAQUE (which is isotonic with blood) compared with conventional contrast media of similar iodine concentration can be expected to cause fewer and less severe osmolality-related disturbances, specifically, less pain, heat and burning sensation, upon injection. VISIPAQUE has approximately one third the osmolality of the

non-ionic media and one sixth that of the monomeric ionic media of equi-iodine concentration (i.e. 290 mOsm/kg water vs 844 and 1800 mOsm/kg water respectively).

Parameter	Concentration (mg I/mL)	
	320	270
Osmolality (mOsm/kg water) (vapour pressure at 37°C)	290	290

Pharmacokinetics of intravenously administered VISIPAQUE are best described by a two-compartment model with a rapid phase for drug distribution and a slower phase for drug elimination. Following intravenous administration of 0.3 to 1.2 g I/kg body weight VISIPAQUE to healthy adult males, the distribution half-life (alpha phase) is 21 minutes, excretion half-life (beta phase) 123 minutes, volume of distribution 0.26 L/kg body weight (a volume consistent with extracellular fluid), and renal clearance 110 mL/min. These values were independent of dose.

VISIPAQUE is excreted by glomerular filtration: approximately 97% of the injected dose is excreted unchanged in urine in the first 24 hours, with peak urine concentrations occurring in the first hour. Less than 2% is excreted in feces within 5 days post-injection.

In patients with impaired renal function, prolonged blood levels of a contrast agent, including VISIPAQUE, may be anticipated due to decreased renal elimination.

In persons with normal renal function, renal visualization with VISIPAQUE occurs approximately 5 minutes after injection; with monomeric non-ionic media visualization occurs after approximately 2 minutes.

Iodixanol produced renal vacuolation of the proximal convoluted tubule in rats at lower urinary concentrations than did non-ionic monomers (see Toxicology, Non-Clinical Pharmacology Table). In view of these findings, it is recommended that caution should be exercised in patients with compromised renal function, and that only the lowest dose necessary to obtain adequate visualization should be used.

Iodixanol showed no significant metabolism in humans.

Iodixanol did not cross the intact blood-brain barrier to any significant extent following intravascular administration in animal studies.

In vitro at human plasma levels of 1.2 mg I/mL, VISIPAQUE did not display any notable protein binding.

In contrast enhanced computed tomographic head imaging, VISIPAQUE does not accumulate in normal brain tissue due to the presence of the normal blood-brain barrier. The increase in x-ray absorption in normal brain is due to the presence of VISIPAQUE within the blood pool. Peak iodine levels occur immediately following rapid intravenous injection. A break in the blood-brain barrier, such as occurs in malignant tumors of the brain allows for the accumulation of contrast medium within the interstitial tissue of the tumor. Diagnostic contrast enhancement images of the brain have been obtained up to 1 hour after intravenous bolus administration.

In contrast enhanced CT body imaging (nonneural tissue), VISIPAQUE diffuses rapidly from the vascular into the extravascular space. Increase in x-ray absorption is related to blood flow, dose, concentration of the contrast medium, diffusion of the contrast medium into the interstitial space, and timing of the scan. Contrast enhancement is thus due to the

relative differences in vascularity and extravascular diffusion between normal and abnormal tissue, quite different from that in the brain.

## **INDICATIONS AND CLINICAL USE**

### **ANGIOCARDIOGRAPHY**

VISIPAQUE (iodixanol) 320 mg I/mL is indicated for use in angiocardiology (left ventriculography, aortic root injections and selective coronary arteriography) and can be used in the diagnosis of coronary artery disease as well as evaluation of the function of the chambers of the heart and heart valves.

### **ARTERIOGRAPHY**

VISIPAQUE 320 mg I/mL is indicated for visualization of the aorta and its branches and for selective peripheral and visceral arteriography and in diagnosing arterial occlusive diseases, aneurysms, arteriovenous malformations and tumors. It may be used for both conventional radiography and digital subtraction angiography (DSA).

VISIPAQUE 270 mg I/mL is also indicated for visualization of the aorta and its branches and for selective visceral arteriography and in diagnosing arterial occlusive diseases and tumors.

## **CT SCANNING OF THE HEAD**

VISIPAQUE 320 mg I/mL or 270 mg I/mL administered intravenously is indicated in refining diagnostic precision in areas of the brain that may not otherwise be satisfactorily visualized.

VISIPAQUE is useful in investigating the presence and extent of malignancies such as gliomas including malignant gliomas, glioblastomas, astrocytomas, oligodendrogliomas and gangliomas, ependymomas, medulloblastomas, meningiomas, neuromas, pinealomas, pituitary adenomas, craniopharyngiomas, geminomas and metastatic lesions. In calcified lesions there is less likelihood of enhancement; following therapy, tumors may show decreased or no enhancement.

VISIPAQUE may be beneficial in the enhancement of most non-neoplastic lesions, including many cerebral infarcts of recent onset, arteriovenous malformations and aneurysms.

Hematomas, intraparenchymal bleeding and clot seldom show enhancement, however, the administration of VISIPAQUE may still help to rule out any associated arteriovenous malformation. Sites of active infection may be enhanced as well.

## **CT SCANNING OF THE BODY**

VISIPAQUE 320 mg I/mL or 270 mg I/mL administered intravenously is indicated for enhancement of computed tomographic images for detection and evaluation of lesions in the liver, pancreas, kidney, aorta, mediastinum, pelvis, abdominal cavity, thoracic space, and retroperitoneal space.

### **Excretory Urography**

VISIPAQUE 320 mg I/mL or 270 mg I/mL administered intravenously is indicated in excretory urography to provide diagnostic contrast of the urinary tract and in the diagnosis of prostate enlargement, renal calculi, obstructive uropathy, urinary tract anomalies, neurogenic bladder, and urinary tract malignancies.

### **Venography**

VISIPAQUE 270 mg I/mL administered intravenously is indicated for venography and is useful in the diagnosis of thrombosis, phlebitis, or obstructed venous system.

## **CONTRAINDICATIONS**

VISIPAQUE (iodixanol) should not be administered to patients with known or suspected hypersensitivity to iodixanol.

## **WARNINGS**

**USE THE RECOMMENDED VISIPAQUE (iodixanol) CONCENTRATION FOR THE PARTICULAR PROCEDURE TO BE UNDERTAKEN.**

Serious or fatal reactions have been associated with the administration of water-soluble contrast media. It is of utmost importance that a course of action be carefully planned in advance for immediate treatment of serious reactions, and that adequate facilities and appropriate personnel be readily available in case a severe reaction should occur.

There must be a clear indication for performing procedures involving the administration of contrast agents in all patients.

Diagnostic procedures which involve the use of radiopaque contrast agents should be carried out only by physicians with the prerequisite training and with a thorough knowledge of the particular procedure to be performed and who are thoroughly familiar with the emergency treatment of all adverse reactions to contrast media.

Generally accepted contraindications, warnings, precautions and adverse reactions commonly related to the use of radiopaque contrast media should be kept in mind during administration of VISIPAQUE.

#### Pheochromocytoma

Administration of radiopaque media to patients known or suspected to have pheochromocytoma should be performed with extreme caution. If, in the opinion of the physician, the possible benefits of such procedures outweigh the considered risk, the amount of radiopaque material injected should be kept to a minimum. The blood pressure should be assessed throughout the procedure and measures for treatment of a hypertensive crisis should be available.

#### Sickle Cell

Contrast media, when injected intravenously or intraarterially, may promote sickling in individuals who are homozygous for sickle cell disease.

#### Multiple Myeloma

Radiopaque contrast agents are potentially hazardous in patients with multiple myeloma or other paraproteinemias, particularly in those with therapeutically resistant anuria. Although neither the contrast agent nor dehydration has been proven separately to be the cause of

anuria in myelomatous patients, it has been speculated that the combination of both may be causative. The risk in myelomatous patients is not a contraindication; however, they require special precautions. (See Precautions).

#### Other Defined Patient Groups

Patients with a history of allergy, bronchial asthma or other allergic manifestations, combined renal and hepatic disease, the elderly, debilitated or severely ill patients, those with homocystinuria, endotoxemia, elevated body temperature, severe hypertension or congestive heart failure and other cardiovascular diseases, hyperthyroidism and recent renal transplant recipients, as well as patients sensitive to iodine, present an additional risk and call for careful benefit/risk ratio assessment. Patients with serum creatinine levels above 3 mg/dL should not undergo excretory urography or other radiological procedures unless the benefit clearly outweighs the risk.

#### Coagulation

Non-ionic iodinated contrast media inhibit blood coagulation less than ionic contrast media in vitro. Clotting has been reported when blood remains in contact with syringes, catheters or tubes containing non-ionic contrast media. Serious, rarely fatal, thromboembolic events causing myocardial infarction and stroke have been reported during angiographic procedures with non-ionic and also with ionic contrast media. Therefore, meticulous intravascular administration technique is necessary, particularly during angiographic procedures, to minimize thromboembolic events. Numerous factors, including length of procedure, number of injections, catheter and syringe material, underlying disease state, and concomitant medications may contribute to the development of thromboembolic events. For

these reasons, meticulous angiographic techniques are recommended including close attention to keeping guidewires, catheters and all angiographic equipment free of blood, use of manifold systems and/or three way stopcocks, frequent catheter flushing with heparinized saline solutions, and minimizing the length of the procedure. Non-ionic iodinated contrast media are not recommended as flush solutions. The use of plastic syringes in place of glass syringes has been reported to decrease but not eliminate the likelihood of in vitro clotting.

### Concurrent Medication

Extreme caution is advised should the injection of a contrast medium be indicated following the administration of vasopressors since they may strongly potentiate neurologic effects.

General anesthesia may be indicated in some procedures; however, one should be aware of possible increased incidence of adverse reactions in such circumstances.

## **PRECAUTIONS**

### **General**

Patients should be well hydrated prior to and following administration of any contrast medium, including VISIPAQUE (iodixanol). Preparatory dehydration is dangerous and may contribute to acute renal failure in patients with pre-existing renal insufficiency, diabetes or advanced vascular disease. Dehydration in these patients seems to be enhanced by the osmotic diuretic action of urographic agents and by the decreased water clearance and uricosuria induced by cholangiographic agents. It is believed that overnight fluid restriction prior to excretory urography generally does not provide better visualization in normal patients.

Before any contrast medium is injected, the patient should be questioned for a history of allergy or bronchial asthma. The susceptible population includes, but is not limited to, patients with a known sensitivity to iodine per se, patients with a history of a previous reaction to contrast media, and patients with a known clinical hypersensitivity: bronchial asthma, hay fever, and /or food allergies. Although a history of allergy or hypersensitivity may imply a greater than usual risk, it does not arbitrarily contraindicate the use of a contrast agent, but extreme caution should be exercised. Premedication with antihistamines or corticosteroids to avoid or minimize possible allergic reactions in such patients may be considered. Additionally, the possibility of an idiosyncratic reaction in patients who have previously received a contrast medium without ill effect should always be considered.

The intravenous injection of a test dose of 0.5 to 1 mL of the contrast agent, before injection of the full dose, has been employed in an attempt to predict severe or fatal adverse reactions. However, pretesting cannot be relied upon to predict severe reactions and may itself be hazardous for the patient. A history of allergy may be more useful in predicting reactions, and warrants special attention when administering the drug. Since delayed severe reactions may occur the patient should be kept under close observation following injection.

Unlike other iodinated contrast agents of comparable iodine concentration but with higher osmolality, VISIPAQUE should not pull additional fluid into the blood because its osmolality is equivalent to the normal osmolality of whole blood. However, caution is required in patients with congestive heart failure since a transient increase in circulatory volume will occur with large injection volumes. These patients should be observed following the procedure to detect delayed hemodynamic disturbances.

Reports of thyroid storm occurring following the intravascular use of iodinated radiopaque agents in patients with hyperthyroidism or with an autonomously functioning thyroid nodule, suggest that this additional risk be evaluated in such patients prior to the use of VISIPAQUE.

Caution should be exercised in performing contrast medium examination in patients with endotoxemia and in those with elevated body temperature.

Angiography should be avoided whenever possible in patients with homocystinuria because of the risk of inducing embolism.

In angiographic procedures, the possibility of dislodging plaques, rupturing aneurysms, or damaging (or perforating) the vessel wall should be borne in mind during catheter manipulations and contrast medium injection. Test injections to ensure proper catheter placement are recommended.

Special care is advised in patients with increased intracranial pressure, cerebral thrombosis or embolism, primary or metastatic cerebral lesions, subarachnoid hemorrhage, arterial spasm, transient ischemic attacks, and in any condition when the blood brain barrier is breached or the transit time of the contrast material through the cerebral vasculature is prolonged, since clinical deterioration, convulsions, and serious temporary or permanent neurological complications (including stroke, aphasia, cortical blindness, etc.) may occur following intravenous or intraarterial injection of relatively large doses of contrast media.

Such patients, and patients in clinically unstable or critical condition should undergo examinations with intravascular contrast media only if in the opinion of the physician the expected benefits outweigh the potential risks, and the dose should be kept to the absolute minimum.

Caution should be exercised in the administration of contrast media to severely debilitated patients, particularly those with severe hypertension and impaired renal function. Acute renal failure has been reported in patients with diabetic nephropathy and in susceptible non-diabetic patients (often elderly with pre-existing renal disease) following administration of iodinated contrast agents. Careful consideration should be given to the potential risks before performing radiographic procedures in these patients.

When considering aortic injections the presence of a vigorous pulsatile flow should be established before using a catheter or pressure injection technique. A small "pilot" dose (about 2 mL) should be administered to locate the exact site of the needle or catheter tip to help prevent injection of the main dose into a branch of the aorta or intramurally.

Entry of a large concentrated bolus into an aortic branch should be avoided. Mesenteric necrosis, acute pancreatitis, renal shut-down, serious neurologic complications including spinal cord damage and hemiplegia or quadriplegia have been reported following inadvertent injection of a large part of the aortic dose of contrast media into an aortic branch or arterial trunks providing spinal or cerebral artery branches.

Pulsation must be present in the artery to be injected. Extreme caution is advised in considering peripheral angiography in patients suspected of having thromboangiitis obliterans (Buerger's disease) since any procedure (even insertion of a needle or catheter) may induce a severe arterial or venous spasm. Caution is also advisable in patients with severe ischemia associated with ascending infection. Special care is required in patients with suspected thrombosis, ischemic disease, local infection or a significantly obstructed vascular system. Occasional serious neurologic complications, including paraplegia have been reported in patients with aorto-iliac or femoral artery bed obstruction, abdominal compression, hypotension, hypertension and following injection of vasopressors.

When large individual doses are administered, an appropriate time interval should be permitted to elapse between injections to allow for subsidence of hemodynamic disturbances.

Following catheter procedures gentle pressure hemostasis is advised followed by immobilization of the limb for several hours to prevent hemorrhage from the site of arterial puncture.

### **Special Precautions By Indication**

#### Angiocardiology

Selective coronary arteriography should be performed only in those patients in whom the expected benefits outweigh the risk. The inherent risks of angiocardiology in patients with chronic obstructive pulmonary disease must be weighed against the necessity for performing this procedure.

During left ventriculography and coronary arteriography, vital signs and the ECG should be monitored routinely throughout the procedure. Caution is advised in the administration of large volumes to patients with incipient heart failure because of the possibility of aggravating the pre-existing condition. Hypotension should be corrected promptly.

Special care regarding dosage should be observed in patients with right ventricular failure, pulmonary hypertension, or stenotic pulmonary vascular beds, because of the hemodynamic changes that may occur after injection into the right heart outflow tract.

Depending on the injection site and the time of recording, significant changes include a drop in cardiac output, elevation or decrease in ventricular pressures (RVSP, LVSP, LVEDP, RVEDP), systemic pressure, peripheral hypotension, brady- or tachycardia, ectopic beats and other arrhythmias.

The hemodynamic changes which occur during and after ventricular and coronary injections are, in general, less pronounced with the low-osmolality VISIPAQUE than those seen with similar concentrations of conventional ionic contrast media, but serious and life threatening hemodynamic disturbances can occur with the administration of all iodinated contrast

media, including VISIPAQUE. If repeat injections are made in rapid succession, all these changes are likely to be more pronounced.

After an initial rise, plasma volume may decrease and continue to fall below control levels, even beyond 30 minutes, probably due to diuresis.

The volume of each individual injection is a more important consideration than the total dose used. When large individual volumes are administered, as in ventriculography, sufficient time should be permitted to elapse between each injection to allow for subsidence of hemodynamic disturbances.

Due to increased risk of adverse reactions following recent acute myocardial infarction, careful patient selection is necessary, and the timing and performance of the examination should be carried out with extreme caution, if invasive radiographic procedures are considered necessary.

### Cerebral Arteriography

Cerebral arteriography should be undertaken with extreme care, especially in elderly patients, patients in poor clinical condition, or patients with advanced arteriosclerosis, severe arterial hypertension, cardiac decompensation or recent cerebral embolism or thrombosis.

In patients with cerebral hemorrhage, a rare association between contrast administration and clinical deterioration, including severe headache and death, has been reported. Therefore, administration of intraarterial iodinated contrast media in these patients should be undertaken with caution, and the lowest dose possible to achieve the necessary diagnostic information should be used.

#### Peripheral and Visceral Arteriography

Under conditions of slowed aortic circulation there is an increased likelihood for aortic injection to cause muscle spasm.

Entry of a large aortic dose into the renal artery may cause, even in the absence of symptoms, albuminuria, hematuria, elevated creatinine and urea nitrogen and possible renal damage.

Pulsation should be present in the artery to be injected. In thromboangiitis obliterans or ascending infection associated with severe ischemia, arteriography should be performed only if the benefits clearly outweigh the risks.

#### Venography

Special care is required when venography is performed in patients with suspected thrombosis, phlebitis, ischemic disease, local infection or a significantly obstructed venous system.

In thromboangiitis obliterans or ascending infection associated with severe ischemia, venography should be performed only if the benefits clearly outweigh the risks.

### Excretory Urography

Urography should be performed with caution in patients with severely impaired renal function and patients with combined renal and hepatic disease. Preparatory dehydration is not recommended, especially in the elderly, diabetic or azotemic patients, or in patients with suspected myelomatosis. Caution is advised in patients with congestive heart failure and in cases of impaired renal function. In all these patients the individual's clinical status and renal function should be carefully monitored.

Since there is a possibility of temporary suppression of urine formation, it is recommended that an interval of at least 48 hours elapse before excretory urography is repeated in patients with unilateral or bilateral reduction in renal function.

### Contrast Enhanced Computed Tomography

In patients where the blood-brain barrier is known or suspected to be disrupted, the use of any radiographic contrast medium must be assessed on an individual risk to benefit basis, since neurological complications are more likely to occur.

The decision to employ contrast enhancement should be based upon a careful evaluation of clinical, other radiological and unenhanced CT findings, because unenhanced scanning may provide adequate diagnostic information in the individual patient, and because contrast

enhancement may be associated with risk, may obscure certain lesions and increases radiation exposure. Intravenous CT scans of the head performed within 24 hours following myelography may yield false results due to the permeation of the brain by the contrast medium from adjacent CSF spaces. Therefore, if indicated, intravenous CT scan of the brain should be performed either before, or after a period of at least 24 hours following myelography.

The opacification of the inferior vermis following administration of contrast media has resulted in a false positive diagnosis in normal subjects.

### **Usage in Pregnancy**

There are no studies on the use of VISIPAQUE (iodixanol) in pregnant women.

Reproduction studies have been performed in rats and rabbits with up to 1.6 times (cumulatively, 20 times) the maximum recommended human dose. No evidence of impaired fertility or definite harm to the fetus has been demonstrated due to iodixanol.

Animal reproduction studies are not always predictive of human response. Therefore, VISIPAQUE should be used during pregnancy only if the benefit to the mother clearly outweighs the risk to the fetus.

### **Nursing Mothers**

It is not known to what extent iodixanol is secreted in human milk.

If use of VISIPAQUE is considered necessary, it is suggested that breast feeding be discontinued for at least 48 hours following administration of VISIPAQUE.

### **Pediatric Use**

The safety and effectiveness of VISIPAQUE for use in children have not been established.

### **Drug Interactions**

Administration of water soluble contrast media should be deferred for 48 hours in patients with hepatic or biliary disorders who have recently been administered cholecystographic agents, as renal toxicity has been reported in the literature in such patients who received conventional contrast agents.

There have been reports in the literature indicating that patients on adrenergic beta-blockers may be more prone to severe adverse reaction to contrast media. At the same time treatment of allergic-anaphylactoid reactions in these patients is more difficult. Epinephrine should be administered with caution since it may not exhibit its usual effects. On the one hand larger doses of epinephrine may be needed to overcome the bronchospasm, while on the other, these doses can be associated with excessive alpha adrenergic stimulation with consequent hypertension, reflex bradycardia and heart-block and possible potentiation of bronchospasm. Alternatives to the use of large doses of epinephrine include vigorous supportive care such as fluids and the use of beta agonists including parenteral salbutamol or isoproterenol to overcome bronchospasm and norepinephrine to overcome hypotension.

General anesthesia may be indicated in the performance of some procedures in selected adult patients. However, a higher incidence of adverse reactions following administration of contrast agents has been reported in anesthetized patients. This may be attributable either to the inability of the patient to identify untoward symptoms or to the hypotensive effect of anesthesia, which can reduce cardiac output and increase the duration of exposure to a contrast agent.

Addition of an inotropic agent to contrast agents may produce a paradoxical depressant response, which can be deleterious to the ischemic myocardium.

Do not mix contrast agents with any other drugs in the same syringe.

#### Laboratory Test Interactions

Radioactive iodine uptake studies if required, should be performed prior to the administration of VISIPAQUE (iodixanol).

VISIPAQUE interferes with Multistix™ measurements of specific gravity and may produce a false-positive result for protein in the urine via Multistix. However, the Coomassie blue method has been shown to give accurate results for the measurement of urine protein in the presence of VISIPAQUE. If a positive Multistix result is obtained, and it is clinically relevant, this method (Coomassie) should be used to check for the presence or absence of protein.

In vitro studies of human urine which tested negative for protein with Multistix, also showed a false positive reaction when iodixanol was added.

### **ADVERSE REACTIONS**

Since the reactions which are known to occur upon parenteral administration of iodinated contrast agents are possible with any non-ionic agent, the same degree of careful patient observation for adverse reactions as with the use of conventional ionic contrast media should be strictly followed. Adequate equipment and appropriate personnel should be readily available in case a severe reaction should occur.

Adverse reactions following the use of VISIPAQUE (iodixanol) are usually of mild to moderate severity and of short duration, resolving spontaneously without treatment. However, serious, life-threatening and fatal adverse reactions have been associated with the administration of iodine-containing contrast agents.

Although most adverse reactions occur soon after the administration of the contrast medium, some adverse reactions may be delayed and could be of a long-lasting nature.

The reported incidence of adverse reactions to contrast media in patients with a history of allergy is twice that of the general population. Patients with a history of previous reactions to a contrast medium are three times more susceptible than other patients. However, sensitivity to contrast media does not appear to increase with repeated examinations.

The injection of contrast media is frequently associated with the sensation of warmth and pain, especially in peripheral arteriography. Patients receiving VISIPAQUE have had less injection-associated discomfort than those receiving control non-ionic contrast agents.

The following listing of adverse reactions is based upon clinical trials in over 2100 patients, 1246 of whom received VISIPAQUE. This listing includes all adverse reactions that occurred following the administration of VISIPAQUE, regardless of their attributability to the drug or to the procedure. The most frequent adverse reactions, which occurred in 1 to 3.4% of patients, were taste perversion (3.4%), nausea (2.8%), vertigo (2.4%), headache (2.3%), rash/erythematous rash (2.1%), pruritus (1.6%), chest pain (1.1%) and scotoma (1.1%).

The following adverse reactions occurred in less than 1% of patients. They appear in descending order of frequency. (However, significantly more severe experiences are listed before others in a system regardless of frequency.)

Injection Site: injection site pain, injection site reaction, injection site inflammation.

Body as a Whole: polymyalgia rheumatica, syncope, precordial chest pain, back pain, edema, pain, fatigue, malaise, rigors, peripheral edema, fever.

Cardiovascular, General: cardiac failure, myocardial infarction, angina pectoris.

Heart Rate and Rhythm: bradycardia, extrasystoles, atrial fibrillation.

Central and Peripheral Nervous System: amnesia, visual anosognosia, convulsions, stupor, paresthesia, sensory disturbance, dizziness, migraine, hypesthesia, leg cramps.

Gastrointestinal System: vomiting, diarrhea, dry mouth, dyspepsia, abdominal pain, increased saliva, esophagitis.

Hearing and Vestibular: earache, tinnitus, hearing decreased.

Platelet, Bleeding and Clotting: hematoma.

Psychiatric: confusion, insomnia, nervousness, somnolence, agitation, anxiety, depression.

Respiratory System: pharyngitis, rhinitis, sinusitis, upper respiratory tract infection, pulmonary edema, dyspnea, bronchitis, asthma.

Sensitivity: pharyngeal edema, facial edema, periorbital edema, urticaria, hypotension.

Skin and Appendage: increased sweating, dry skin.

Special Senses: parosmia.

Urinary System: urinary tract infection, abnormal renal function, hematuria, BUN increased.

Vascular (Extracardiac): flushing, peripheral ischemia, cerebrovascular disorder.

Vision: abnormal vision, conjunctivitis, diplopia.

### Adverse Reactions With Increased Frequency In Individual Indications

For certain procedures, the number of some adverse reactions was higher than the overall rate for all procedures. Following are the clinically relevant experiences occurring at a higher rate, listed by indication:

#### Cerebral Arteriography

Central and Peripheral Nervous System: vertigo (28.3%), scotoma (12.3%), headache (11.3%), sensory disturbance (6.6%).

Gastrointestinal System: nausea (5.7%).

Psychiatric: confusion (3.8%).

#### CT Scanning of the Body

Central and Peripheral Nervous System: headache (5.1%).

Gastrointestinal System: nausea (5.1%).

Skin and Appendage: rash (6.1%), pruritus (4.2%).

Special Senses: taste perversion (14.9%).

#### CT Scanning of the Head

Special Senses: parosmia (3.0%).

#### Venography

Body as a Whole: chest pain (4.3%).

## **TREATMENT OF ADVERSE REACTIONS TO CONTRAST MEDIA**

Contrast media should be injected only by physicians thoroughly familiar with the emergency treatment of all adverse reactions to contrast media. The assistance of other trained personnel such as cardiologists, internists and anesthesiologists is required in the management of severe reactions.

A guideline for the treatment of adverse reactions is presented below. This outline is not intended to be a complete manual on the treatment of adverse reactions to contrast media or on cardiopulmonary resuscitation. The physician should refer to the appropriate texts on the subject.

It is also realized that institutions or individual practitioners will already have appropriate systems in effect and that circumstances may dictate the use of additional or different measures.

**For Minor Allergic Reactions:** (If considered necessary).

The intravenous or intramuscular administration of an antihistaminic such as diphenhydramine hydrochloride 25-50 mg is generally sufficient (contraindicated in epileptics). The resulting drowsiness makes it imperative to ensure that out-patients do not drive or go home unaccompanied.

**Major or Life-Threatening Reactions:**

A major reaction may be manifested by signs and symptoms of cardiovascular collapse, severe respiratory difficulty and nervous system dysfunction. Convulsions, coma and cardio-respiratory arrest may ensue.

The following measures should be considered:

1. Start emergency therapy immediately - carefully monitoring vital signs.
2. Have emergency resuscitation team summoned - do not leave patient unattended.
3. Ensure patent airway - guard against aspiration.
4. Commence artificial respiration if patient is not breathing.
5. Administer oxygen if necessary.
6. Start external cardiac massage in the event of cardiac arrest.
7. Establish route for i.v. medication by starting infusion of appropriate solution (5% dextrose in water).
8. Judiciously administer specific drug therapy as indicated by the type and severity of the reaction. Careful monitoring is mandatory to detect adverse reactions to all drugs administered.
  - Soluble hydrocortisone 500-1000 mg i.v., for all acute allergic-anaphylactic reactions.
  - Epinephrine 1:1000 solution (in the presence of anoxia it may cause ventricular fibrillation - CAUTION in patients on adrenergic -blockers - See Precautions):
    - 0.2-0.4 mL subcutaneously for severe allergic reactions.

- in extreme emergency 0.1 mL per minute, appropriately diluted, may be given intravenously until desired effect is obtained. Do not exceed 0.4 mL.
- in case of cardiac arrest 0.1-0.2 mL appropriately diluted, may be given intracardially.
  
- In hypotension (carefully monitoring blood pressure):
  - phenylephrine hydrochloride 0.1-0.5 mg appropriately diluted, by slow intravenous injection or infusion.
  
  - or
  - norepinephrine bitartrate 4 mL of 0.2% solution in 1,000 mL of 5% dextrose by slow drip infusion.
  - Sodium bicarbonate 5%: 50 mL i.v., every 10 minutes as needed to combat post-arrest acidosis.
  - Atropine 0.4-0.6 mg i.v., to increase heart rate in sinus bradycardia. May reverse 2nd or 3rd degree block.
  
- TO CONTROL CONVULSIONS:
  - DIAZEPAM 5-10 mg SLOWLY I.V., TITRATING THE DOSE TO THE RESPONSE OF THE PATIENT
  
  - OR
  - PHENOBARBITAL SODIUM may be injected i.v., or i.m., at a rate not in excess of 30 to 60 mg/ minute. Depending on the patient's response a total dose of 200-300

mg may be required. The dose may be repeated in 6 hours if necessary.

9. Defibrillation, administration of anti-arrhythmics and additional emergency measures and drugs may be required.
10. Transfer patient to intensive care unit when feasible for further monitoring and treatment.

### **OVERDOSAGE**

The adverse effects associated with overdosage of iodinated contrast media may be life-threatening; they affect mainly the pulmonary and cardiovascular systems. The symptoms include cyanosis, edema, bradycardia, acidosis, pulmonary hemorrhage, convulsions, coma and cardiac arrest. The symptoms of overdosage generally appear between 10 minutes and several hours after injection of the contrast medium. Treatment of an overdosage is directed toward the support of all vital functions and prompt institution of symptomatic therapy.

The minimum lethal dose of intravenously administered VISIPAQUE (iodixanol) in adult rats is approximately 14 g I/kg (over 10 times the maximum recommended human dose).

### **DOSAGE AND ADMINISTRATION**

BEFORE USE, VISIPAQUE (iodixanol) CONTAINERS SHOULD BE INSPECTED VISUALLY FOR PARTICULATE MATTER AND/OR DISCOLORATION. IF EITHER IS PRESENT, THE CONTAINERS SHOULD BE DISCARDED.

VISIPAQUE SHOULD BE INJECTED AT OR CLOSE TO BODY TEMPERATURE AND SHOULD BE USED IMMEDIATELY ONCE THE CONTAINER SEAL HAS BEEN PUNCTURED. VISIPAQUE SHOULD NOT BE TRANSFERRED FROM THE ORIGINAL CONTAINER TO OTHER DELIVERY SYSTEMS EXCEPT IMMEDIATELY PRIOR TO USE; NOR SHOULD IT BE MIXED WITH OTHER DRUGS. ANY UNUSED PORTION SHOULD BE DISCARDED. VISIPAQUE CONTAINERS SHOULD BE PROTECTED FROM EXPOSURE TO LIGHT. SYRINGES, NEEDLES AND CATHETER TIPS MUST BE KEPT FREE OF ASPIRATED BLOOD TO PREVENT CLOTTING FROM PROLONGED CONTACT.

The combination of volume and concentration of VISIPAQUE to be used should be carefully individualized accounting for factors such as age, body weight, size of the vessel, rate of blood flow within the vessel, indication for examination, and timing of the X-ray or CT scan. Other factors to be considered are anticipated pathology, degree and extent of opacification required, structure or area to be examined, disease processes affecting the patient, and equipment and technique used.

Sterile technique must be used in all procedures involving vascular injections of contrast media. Withdrawal of contrast agents from their containers should be accomplished under aseptic conditions with sterile equipment.

## Dosage Table

<u>Intraarterial*</u>	<u>Concentration</u> (mg I/mL)	Usual Recommended <u>Single Dose</u> (mL)	<u>Maximum Total</u> <u>Procedural Dosage</u> (mL)
Angiocardiology Left ventricle Left coronary artery Right coronary artery	320	20-45 3-10 3-8	200
Cerebral Arteriography (A) Conventional Carotoid artery Vertebral artery (B) Digital Subtraction Angiography (DSA) Carotoid artery Vertebral artery	320	10-14 10-12  5-8 5-8	175   175
Peripheral Arteriography (A) Conventional Aortography Aortofemoral runoffs Peripheral arteries (B) Digital subtraction Angiography (DSA) Aortography/ Aortofemoral runoffs Peripheral arteries	320	30-60 20-90 15-30  6-15 3-15	250   250
Visceral Arteriography (A) Conventional Aortography, including runoffs Major branches of aorta Renal arteries (B) DSA Aortography, including runoffs Major branches of aorta (C) Abdominal DSA Aortography Major branches of aorta Renal arteries	320   320  270	30-70 10-70 8-18  10-50 2-10  20-50 5-30 10-25	250   250  250
<u>Intravenous</u>			
Excretory Urography	270, 320	1/kg (0.27-0.32 g I/kg)	100
Computed Tomography (CT) of the Head	270, 320	100	-
Computed Tomography (CT) of the Body	270, 320	75-150	-
Venography	270	50- 150/extremity**	-

\* These doses may be repeated as necessary, up to the procedural maximum dose shown.

\*\* Volume depends on size, flow rate, and disease state of the injected vessel, on the size and condition of the patient, and on the imaging technique used.

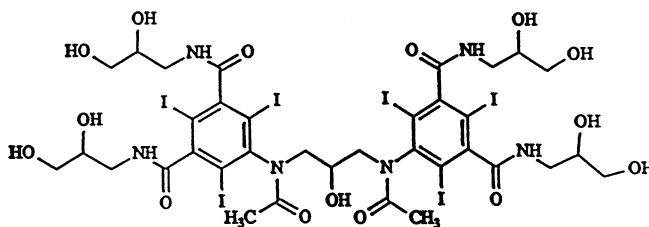
## PHARMACEUTICAL INFORMATION

Trade Name: Visipaque injection

Common Name: iodixanol

Chemical Name: 5,5 -[(2-hydroxy-1,3-propanediyl)bis(acetylimino)]  
bis[N,N -bis(2,3-dihydroxypropyl)-2,4,6-triiodo-1,3-benzenedicarboxamide]

Structural Formula:



Molecular Formula: C<sub>35</sub>H<sub>44</sub>I<sub>6</sub>N<sub>6</sub>O<sub>15</sub>

Molecular Weight: 1550.20

Iodine Content: 49.1%

VISIPAQUE (iodixanol) is provided as a sterile, pyrogen-free, colorless to pale yellow solution. It decomposes between 221 and 244°C. Iodixanol does not exhibit polymorphism. Partition coefficients are  $9.0 \times 10^{-5}$  using n-octanol/water (1:1), and  $4.3 \times 10^{-2}$  using n-butanol/water (4:1).

Name	Iodixanol conc. mg/mL	Iodine conc. mg I/mL	Osmolality mOsm/kg H <sub>2</sub> O	Viscosity (cps)		Density (g/mL) (37° C)
				20°C	37 °C	
VISIPAQUE 270	550	270	290	12.7	6.3	1.303
VISIPAQUE 320	652	320	290	26.6	11.8	1.356

### Composition

Sodium chloride and calcium chloride have been added, resulting in an isotonic solution for injection.

VISIPAQUE 270 (270 mg I/mL) contains 0.074 mg calcium chloride dihydrate per mL and 1.87 mg sodium chloride per mL, and VISIPAQUE 320 (320 mg I/mL) contains 0.044 mg calcium chloride dihydrate per mL and 1.11 mg sodium chloride per mL, providing for both concentrations a sodium/calcium ratio equivalent to blood. In addition, each mL contains 1.2 mg tromethamine and 0.1 mg edetate calcium disodium; the pH is adjusted between 6.8 and 7.7 with hydrochloric acid at 22°C.

All solutions are terminally sterilized by autoclaving and contain no preservatives.

### Storage Recommendations

Protect bottles of VISIPAQUE from strong daylight and direct exposure to sunlight. Store at controlled room temperature, 15°C to 30°C. VISIPAQUE may be stored at 37°C for up to one month in a contrast agent warmer utilizing circulating air.

Do not freeze. Freezing may compromise the closure integrity of these packages. Do not use if the product is inadvertently frozen.

### Directions for Dispensing from Pharmacy Bulk Vial

The use of Pharmacy Bulk Vials is restricted to hospitals with a recognized intravenous admixture program. The Pharmacy Bulk Vial is intended for single puncture, multiple dispensing.

### **AVAILABLE DOSAGE FORMS**

VISIPAQUE (iodixanol) injection 320mg I/mL:

50 mL bottle, boxes of 10

100 mL bottle, boxes of 10

250 mL bottle (200 mL fill), boxes of 10

500 mL bottle, boxes of 6

VISIPAQUE (iodixanol) injection 270 mg I/mL:

50 mL bottle, boxes of 10

100 mL bottle, boxes of 10

250 mL bottle (200 mL fill), boxes of 10

500 mL bottle, boxes of 6

## Nonclinical TOXICOLOGY Studies

Study type	Animal species	Total no. of animals		Number of dosings Route (Rate)	Dose in gI/kg (Concentration)	Results
		M	F			
<b>Acute:</b> Intravenous tolerance in mice	Mouse	20	20	1 IV (1 mL/min)	6.4, 12.8, 19.2 (320 mg I/mL)	ALD <sub>50</sub> (male) = 18.8 gI/kg (female) = 18.0 gI/kg Cause of death was kidney toxicity. Effects: ataxia, dyspnea, spastic body moves, ptosis, and ↓ or absent motor activity.
<b>Acute:</b> Acute toxicity study	Monkey	12	0	1 IV (10 mL/min)	0.3, 1.0, 3.0 (320 mg I/mL)	No deaths. Minimal fine vacuolation of the kidney proximal tubules.
<b>Repeated-dose:</b> Intravenous administration of iodixanol to rats for three weeks followed by a four-week recovery period	Rat	60	60	9 [3 per week] IV (1 to 2 mL/min)	0.5, 2.0, 4.0 (320 mg I/mL)	Dose-related vacuolation of kidney proximal tubules and urothelium of urinary bladder, both partially reversible. ↑ kidney weight at 2.0 and 4.0 g I/kg.
<b>Repeated-dose:</b> Preliminary two-week intravenous study in monkeys	Monkey	2	2	14 [1 per day] IV	0.03, 0.1 (320 mg I/mL)	No evidence of treatment-related effects.
<b>Repeated-dose:</b> Intravenous administration to monkeys for four weeks with a four-week recovery period	Monkey	16	16	28 [1 per day] IV (10 mL/min)	0.1, 0.3, 1.0 (320 mg I/mL)	Partially reversible minimal fine vacuolation of the kidney proximal tubules at all doses.
<b>Irritation:</b> Acute vascular irritation in rabbits	Rabbit	6	4	1 IV (bolus)	0.16 gI total (320 mg I/mL)	Nonirritating.
<b>Irritation:</b> Intra-arterial irritation in rabbits	Rabbit	6	6	1 IA (5 min)	0.32 (320 mg I/mL)	Nonirritating.
<b>Reproductive:</b> Fertility and reproductive performance of male and female rat	Rat	112	96	M: 84-103 [Daily 9 weeks prior to mating → Day 20 of gestation] F: 22-41 [Daily 2 weeks prior to mating → Day 7 of gestation] (saline) IV (1 mL/min)	0.3, 1.0, 2.0 (320 mg I/mL)	No effect on any reproductive parameters. Maternal NOEL = 0.3 gI/kg Developing conceptus NOEL > 2.0 gI/kg
<b>Reproductive:</b> Teratology in the rabbit	Rabbit	0	64	13 [Daily, Days 6-18 of gestation] (saline) IV	0.3, 1.0, 2.0 (320 mg I/mL)	No teratogenic effects or adverse effects on F0 or F1 animals.

Study type	Animal species	Total no. of animals		Number of dosings Route (Rate)	Dose in gI/kg (Concentration)	Results
		M	F			
<b>Mutagenicity:</b> 1. Ames metabolic activation test	<i>In vitro</i> ( <i>S. typhimurium</i> ; 5 strains)	3 plates per test		1 [With and without metabolic activation] (4 positive controls) N/A	50, 150, 500, 1500, 5000 µgI/plate (320 mg I/mL)	Negative with and without metabolic activation.
2. Mammalian cell mutation assay using the Chinese hamster ovary/HPRT locus system	<i>In vitro</i> (Chinese hamster ovary cells)	3 dishes per test (200 cells per dish)		1 [With and without metabolic activation] (2 positive controls) N/A	N/A (1.2, 1.6, 2.0, 2.4, 2.8, 3.2 mg I/mL; prepared from 320 mg I/mL)	Negative with and without metabolic activation.
3. Analysis of metaphase chromosomes obtained from CHO cells cultured <i>in vitro</i> and treated with iodixanol	<i>In vitro</i> (Chinese hamster ovary cells)	200 cells per test		1 [With and without metabolic activation] (2 positive controls) N/A	(0.32, 1.6, 3.2 mg I/mL; prepared from 320 mg I/mL)	Negative with and without metabolic activation.
4. Mouse micronucleus test	Mouse	40	40	1 (positive control given orally and vehicle) IV	3.2 (320 mg I/mL)	No evidence of mutagenic potential or bone marrow cell toxicity.

IV = Intravenous IA = Intra-arterial

## Nonclinical PHARMACOLOGY Studies

Study type	Animal species	Total no. of animals		Number of dosings Route (Rate)	Dose in gI/kg (Concentration)	Results
		M	F			
<b>CNS:</b> Effects on behaviour and electroencephalogram	Rabbit	4	0	4 [one week recovery] IV (3 mL/min)	660, 2200, 6600 mg/kg (10 mL/kg)	Hyperventilation and dilatation of blood vessels in ear at higher doses; mild EEG activation.
<b>CNS:</b> Effects on blood-brain barrier; comparison with iothalamate, iohexol and iopentol	Rabbit	50	0	1 IA (30 sec)	0.28-0.62 (diluted to 280 mg I/mL)	Iodixanol produced only minor changes of the barrier; producing less extravasation than iopentol or iohexol. Iothalamate caused severe extravasation.
<b>CNS:</b> Effects on EEG and behaviour	Dog	0	12	1 IC (4 mL/min)	0.13, 0.26 (320 mg I/mL)	Iodixanol produced more marked but less persistent EEG effects than iopamidol; behavioral effects were less severe and less persistent with iodixanol.
<b>Cardiovascular:</b> Effects on blood pressure	Rabbit	14	0	1 IV	2, 4 (320 mg I/mL)	No effect on blood pressure.
<b>Cardiovascular:</b> Comparison of effects of iodixanol, iopamidol, ioxaglate and saline during left and right intracoronary injections	Dog	Right injection 10  Left injection 6		2 [15 or 30 min apart] IA (0.4 mL/sec for 25 sec)  4 [every 15 min] IA (1 mL/sec for 5 sec)	1.6, 3.2 gI total (320 mg I/mL)	Incidence of VT or VF in right intracoronary injection similar to saline, significantly less than iopamidol and ioxaglate. Changes in LV dP/dt, LV pressure and mean SP and DP after left intracoronary injection similar to saline, significantly less than with ioxaglate.
<b>Cardiovascular:</b> Comparison of hemodynamic effects after intracoronary injection of iodixanol, iohexol or ioxaglate	Dog	9		2 [10-15 min apart] IA (3 mL/min)	6 mL total per dosing (320 mg I/mL with added NaCl)	Iodixanol better tolerated than iohexol and ioxaglate; all induced only small changes in systolic and diastolic functions.
<b>Cardiovascular:</b> Effects of four contrast media on femoral blood flow after injection into the femoral artery: iodixanol, iopentol, iohexol, metrizoate	Dog	12		8 [1 at each dose; 10 min apart] IA (3 or 6 sec)	0.05, 0.1 (320 mg I/mL)	Iodixanol produced smaller flow increases.

Study type	Animal species	Total no. of animals		Number of dosings Route (Rate)	Dose in gI/kg (Concentration)	Results
		M	F			
<b>Renal:</b> Effects of contrast media on kidney morphology	Rat	162	0	1 IV	1, 2, 5, 10 (320 mg I/mL)	Vacuolation of proximal convoluted tubular epithelium was seen following the highest doses of iodixanol, ioxaglate, iohexol, iopentol and iopamidol, in decreasing order of severity. No vacuolation followed diatrizoate administration. For iopamidol, ioxaglate, iopentol and iohexol hepatic parenchymal vacuolation was also seen at these high dose levels. No effect levels were seen at 5 gI/kg for diatrizoate, 2 gI/kg for iopamidol, iopentol or iohexol, 1 gI/kg for ioxaglate and <1 gI/kg for iodixanol.
<b>Renal:</b> Effects on renal tubular vacuolation	Monkey	4	0	1 IV (10 mL/kg per min)	2.4, 3.6, 4.8 (320 mg I/mL)	Renal proximal tubular vacuolation seen 24 hours after 3.6 gI/kg dose. No vacuoles seen at biopsy two weeks postdose.
<b>Renal:</b> Effects on renal tubular vacuolation	Monkey	15	0	1 IV (10 mL/min)	1.2, 3.6 (320 mg I/mL)	Renal proximal tubular vacuolation was compound-related and was reversible within seven weeks.
<b>Renal:</b> Effects in unilaterally nephrectomized rats	Rat	24	0	1 IV (1 mL/min)	2.0 (320 mg I/mL)	Iodixanol did not affect renal function as determined by serum urea and creatinine concentration.
<b>Renal:</b> Effects on kidney function after high doses	Rabbit	6		1 IV (10 mL/min)	7.3, 7.5, 8.6, 10.5 (370 mg I/mL)	No change in kidney function at any dose except 10.5 gI/kg.
<b>Blood:</b> Effects of four non-ionic contrast media on red blood cells <i>in vitro</i> : aggregation	<i>In vitro</i> (Human blood)	5 samples per concentration and volume ratio		1 N/A	Volume ratios 2, 20, 50% [CM: blood] (original: 350 mg I/mL; isotonic: 121 mg I/mL)	All agents decreased RBC aggregation, with no differences among the contrast media.
<b>Blood:</b> Effects of three contrast media on <i>in vitro</i> thrombin generation in human blood (iodixanol, iohexol, iopamidol)	<i>In vitro</i> (Human blood)	7 samples per assay		N/A N/A	5 mL per tube (320 mg I/mL)	Iodixanol inhibited thrombin formation less than iohexol and iopamidol.

IV = Intravenous IC = Intracisternal IA = Intra-arterial

## Nonclinical PHARMACOKINETIC Studies

Study type	Animal species	Total no. of animals		Number of dosings Route (Rate)	Dose in gI/kg (Concentration)	Results
		M	F			
Pharmacokinetics after a single dose of [ <sup>125</sup> I]-iodixanol	Rat	20	0	1 (none) IV (2 mL/min)	0.2 (15 mg I/mL)	Half-life = 25.4 ± 1.9 min. No metabolites detected in the bile (limit < 0.3%).
Pharmacokinetics after infusion of a single high dose of metrizoate, diatrizoate, metrizamide, ioxaglate, iodixanol, iopentol or iohexol in rabbits	Rabbit	203		1 (iohexol at 0.5 and 1.0 gI/kg) IV (~1 mL/min)	12.5 (280 mg I/mL)	Half-life = 83 min Clearance = 30 mL/min • m <sup>2</sup> Vol. of dist. = 0.42 L/kg Values were similar to those for high doses of iopentol and iohexol, but half-life was significantly longer than with iohexol at 1.0 gI/kg (43 min).
Excretion: disposition and systemic availability of iodixanol in dogs after intravenous and intracisternal administration	Dog	0	6	2 (separated by two-week washout period) IV,IC (4 mL/min)	0.128 (320 mg I/mL)	After IV administration, 89.9% of the administered dose recovered in urine. After IC administration, 82.8% of the administered radioactivity recovered in urine.
Pharmacokinetics after a single dose of [ <sup>125</sup> I]-iodixanol in monkeys	Monkey	12	0	1 (none) IV (10 mL/min)	0.3, 1.0, 3.0 (320 mg I/mL)	Half-life = 76 min Clearance = 8.62 mL/min Vol. of distribution = 0.32 L/kg 85% of the administered radioactivity excreted in urine within 24 h, only 1% in feces. 0.05% to 1.54% of the administered radioactivity present in the kidneys at 24 h.

IV = Intravenous      IC = Intracisternal

## **BIBLIOGRAPHY**

### Animal Studies

1. Klow NE, Martensen E, Refsum H. Left ventricular systolic and diastolic function during coronary arteriography before and after acute left ventricular failure in dogs: a comparison between iodixanol, iohexol and ioxaglate. Acta Radiol 1991; 32: 124-9.
2. Almen T. Effects of iodixanol, iopentol, iohexol and metrizoate on femoral blood flow after injection into the femoral artery of the dog. Acta Radiol 1987; Suppl. 370: 69-72.
3. Sunnegardh O, Hietala S-O, Holtz E. Systemic, pulmonary and renal haemodynamic and renal morphologic effects of intravenously infused iodixanol: a study in the pig of a new iso-osmolar contrast medium. Acta Radiol 1990; 31: 513-18.

### Clinical Studies

4. Svaland MG, Haider T, Langseth-Manrique K, Andrew, E and Hals, PA. Human pharmacokinetics of iodixanol. Invest Radiol 1992; 27: 130-3.
5. Jakobsen JA, Lundby B, Kristoffersen DT, Borch KW, Hald JK and Berg KJ. Evaluation of renal function with delayed CT after injection of non-ionic monomeric and dimeric contrast media in healthy volunteers. Radiology 1992; 182: 419-424.
6. Bolstad B, Borch KW, Grynne BH, Lundby B, Nossen JO, Kloster YF, Kristoffersen DT and Andrew A. Safety and tolerability of iodixanol. A dimeric, non-ionic contrast medium: An emphasis on European clinical phases I and II. Invest Radiol 1991; 26: 201-4.
7. Jorgensen NP, Nossen JO, Borch KW, Kristiansen AB, Kristoffersen DT, Lundby B and Theodorsen L. Safety and tolerability of iodixanol in healthy volunteers with reference to two monomeric x-ray contrast media. Eur J Radiol 1992; 15: 252-7.
8. Klow NE, Levorstad K, Berg KJ, Brodahl U, Endresen K, Kristoffersen DT, Laake B, Simonsen S, Tofte AJ, and Lundby, B. Iodixanol in cardioangiography in patients with coronary artery disease. Tolerability, cardiac and renal effects. Acta Radiol 1993; 34: 72-7.
9. Albrechtsson U, Larusdottier H, Norgren L and Lundby B. Iodixanol - a new non-ionic dimer - in aortofemoral angiography. Acta Radiol 1992; 33: 1-3.
10. Pugh ND, Sissons GRJ, Ruttley MST, Berg KJ, Nossen JO and Eide H. Iodixanol in femoral arteriography (phase III) - a comparative double-blind parallel trial between iodixanol and iopromide. Clin Radiol 1993; 47: 96-9.